

Intradural-Extramedullary Cavernous Hemangioma of the Left Motor Root C7 – Case Report and Update of the Literature

J. Rachinger¹
R. Buslei²
T. Engelhorn³
A. Doerfler³
C. Strauss¹

Intradural-extramedulläres kavernöses Hämangiom der linken motorischen Wurzel C7 – Fallbericht und Update der Literatur

Abstract

Objective: Intradural-extramedullary cavernomas of the spine are rare lesions with only 21 published cases to date. Due to their rareness and special characteristics diagnosis often is difficult. We report on an additional case of an intradural-extramedullary cavernoma of the spine. **Patient:** A 56-year-old male presented with left shoulder pain and acute onset of pain affecting the whole spinal column two weeks prior to admission. There were no motor deficits, but a hypesthesia corresponding to the right distal C8-dermatome. MRI revealed an intradural-extramedullary, expansive lesion at the level of C6 with a hyperintense appearance in both T₁- and T₂-weighted images. Neither a hemosiderin rim nor contrast enhancement was visible. **Results:** During surgery a hematoma and a reddish, berry-like tumor adherent to the left motor root C7 were removed. There were no new neurological deficits, and shoulder and back pain resolved within a few weeks after surgery. Histopathologically a cavernous hemangioma was diagnosed. **Conclusions:** The patient's symptoms were caused both by direct nerve compression and by spinal hemorrhage, most likely spinal SAH. As there was no characteristic hemosiderin rim and due to the hyperintense appearance in T₁- and T₂-weighted MR scans, a radiological diagnosis of hemorrhage and classification of the lesion was difficult. Despite their rareness, in patients with signs of spontaneous, spinal SAH and/or nerve compression syndromes cavernous hemangiomas have to be considered as a potential cause.

Zusammenfassung

Einleitung: Intradural-extramedulläre Kavernome der Wirbelsäule sind seltene Läsionen, bis jetzt wurden nur 21 solcher Fälle publiziert. Wegen ihrer Seltenheit und ihrer besonderen Eigenschaften ist die Diagnose oft schwierig. Wir berichten über einen weiteren Fall eines intradural-extramedullären Kavernoms der Wirbelsäule. **Patienten/Material und Methoden:** Ein 56-jähriger Mann klagte über Schmerzen der linken Schulter und einen 2 Wochen vor der stationären Aufnahme akut einsetzenden Schmerz im Bereich der gesamten Wirbelsäule. Motorische Ausfälle bestanden nicht, es zeigte sich jedoch eine Hypästhesie im distalen Dermatome C8 rechts. Kernspintomographisch fand sich dorsal des HWK 6 ein intradural-extramedullär gelegener, raumfordernder Prozess, der sowohl in den T₁- als auch in den T₂-gewichteten Sequenzen hyperintens imponierte. Ein Hemosiderin-saum oder eine Kontrastmittelaufnahme fehlten. **Ergebnisse:** Im Rahmen der Operation wurden ein Hämatom und ein rötlicher, Maulbeer-artiger Tumor, der von der vorderen Wurzel C7 ausging, entfernt. Neue neurologische Defizite traten nicht auf, Schulter- und Rückenschmerz bildeten sich innerhalb weniger Wochen vollständig zurück. Histopathologisch wurde ein kavernöses Hämangiom diagnostiziert. **Schlussfolgerungen:** Die Symptome des Patienten wurden durch eine direkte neurale Kompression und eine intraspinale Blutung verursacht, wobei eine subarachnoidale Blutungskomponente angenommen werden kann. In Abwesenheit eines Hemosiderinsaumes war bei

Affiliation

¹ Department of Neurosurgery, University of Erlangen-Nuernberg, Erlangen, Germany

² Institute for Neuropathology, University of Erlangen-Nuernberg, Erlangen, Germany

³ Department of Neuroradiology, University of Erlangen-Nuernberg, Erlangen, Germany

Correspondence

Jens Rachinger MD · Department of Neurosurgery · University of Erlangen-Nuernberg · Schwabachanlage 6 · 91054 Erlangen · Germany · Tel.: +49/91 31/8 53 30 01 · Fax: +49/91 31/8 53 45 69 · E-mail: jens.rachinger@nch.imed.uni-erlangen.de

Bibliography

Zentralbl Neurochir 2006; 67: 144–148 © J. A. Barth Verlag in Georg Thieme Verlag KG
DOI 10.1055/s-2006-933362
ISSN 0044-4251

der im T₁- und T₂-Bild hyperintensen Darstellung die radiologische Diagnose der Blutung und die Einordnung der Läsion schwierig. Trotz ihrer Seltenheit müssen spinale, intradurale Kavernome bei Patienten mit Zeichen einer spinalen SAB oder eines nervalen Kompressionssyndromes als mögliche Ursache in Betracht gezogen werden.

Key words

Cavernous hemangioma · spine · subarachnoid hemorrhage

Schlüsselwörter

Kavernöses Hämangiom · Wirbelsäule · Subarachnoidalblutung

Introduction

Cavernous hemangiomas (also referred to as cavernomas or hemangiomatous angiomas) are congenital vascular lesions consisting of dilated blood vessels separated by fibrous tissue with no interposing neural structures that may affect any area in the neuraxis [5, 12]. Between 3–16% of all angiomatous lesions of the spine are cavernomas [15]. They occur in the vertebral body with and without epidural extension, in the epidural space without involving bony structures, as intradural-extramedullary as well as intramedullary lesions [7]. Only 3% are localized intradurally, most of them within the spinal cord [10]. Of all spinal cavernous hemangiomas intradural-extramedullary lesions are among the rarest ones. Prior to 1990 only 10 surgically treated cases were reported in literature [16], by 2003 this number had increased to 21 [13] with only three cases located in the cervical spine. Due to their rareness, the variable clinical symptoms and inhomogeneous MR findings, diagnosis of these lesions is often difficult. By presenting an additional case of an intradural-extramedullary cavernoma and providing an update of the literature we outline the clinical characteristics of these lesions and discuss the specific problems that may arise.

Case report

A 56-year-old man presented with a six month history of left shoulder pain. Two weeks prior to admission additional, persistent pain extending from the craniocervical level along the spinal column down to the sacrum developed. Furthermore, the patient reported a numbness of the right forearm. 30 years ago this man had suffered from an abscess in the deep musculature of the neck that was treated by antibiotics. Neurological examination revealed a hypesthesia corresponding to the right distal C8-dermatome, but no motor deficits. Laboratory analysis of blood showed normal findings: in particular, there was no evidence for an infection. Magnetic resonance tomography revealed a roundish, expansive lesion posterior to the vertebral body C6, with an intradural-extramedullary and left anterolateral location. It was homogeneously hyperintense both in T₁- and T₂-weighted images; contrast enhancement could not be documented (Fig. 1). A laminectomy at the level of C6 and a partial laminectomy of C7 were performed (Fig. 2). After opening the dura on the left side, the posterior nerve root C7 was found to be elevated and displaced dorsally by an underlying hematoma. After evacuation of the hematoma caudally from the left motor root C7 and anterolaterally to the spinal cord, a reddish, berry-like mass became visible which was adherent to the anterior root of C7

(Fig. 3). The lesion could be removed completely with all neural structures preserved (Fig. 4). A cavernous hemangioma was diagnosed histopathologically. The surgical specimen consisted of a hematoma with a tightly packed collection of hyalinized vessels (Fig. 5). The vessel walls were of variable thickness, lacking elastic tissue and back to back without tissue fragments in between. In addition to fresh blood and old hemorrhage remnants, some vessels showed extensive thrombotic occlusions. There was no evidence for an arteriovenous malformation. The post-operative course was uneventful: the pain resolved within a few weeks after surgery and the hypesthesia of the right forearm remained unchanged in the two-month follow-up.

Discussion

So far 21 cases of surgically treated, intradural-extramedullary cavernomas have been reported in the literature [1–4, 7–11, 13, 14, 16–22] (Table 1). Ages ranged from 20 to 67 years, 14 patients were male. 15 lesions were located in the thoracolumbar region, while three were between T1 and T9 and another three were found in the cervical spine. In eleven cases radiculopathy and/or myelopathy led to sensory and/or motor deficits. Bladder dysfunction was observed in three patients, while SAH was confirmed in nine patients. In a single patient with gait disturbance and cognitive impairment the co-existence of a cavernoma of the cauda equina and normal pressure hydrocephalus was described [19]. Although the symptoms regressed after surgical removal of the cavernoma, in this case the causality was not definitely clear. Nearly all patients suffered from pain, either radiculopathic or back pain caused by SAH or direct nerve compression. Complete resection was achieved in 20 cases, one patient deteriorated after surgery, another one showed no neurological improvement. In three patients an incomplete recovery was observed. As in many pathologies of the spine, the severity and duration of neurological deficits at the time of surgery seem to be important factors for outcome. Twelve cavernous hemangiomas originated from a nerve root, two showed a mixed origin from the myelon and a nerve root, while two originated from the spinal cord alone. One lesion arose from the filum terminale, another one from the dura. In three cases the origin remained unclear. In MRI, intradural-extramedullary cavernomas can be homogeneously or inhomogeneously hyperintense in T₁-weighted images. They can also appear hyperintense in T₂-weighted images, and gadolinium enhancement is frequent but not necessary. In cases with hemorrhage, MRI findings obviously depend on the stage and the size of the bleeding. According to the literature, surgery is the only treatment option for symptomatic lesions [7,

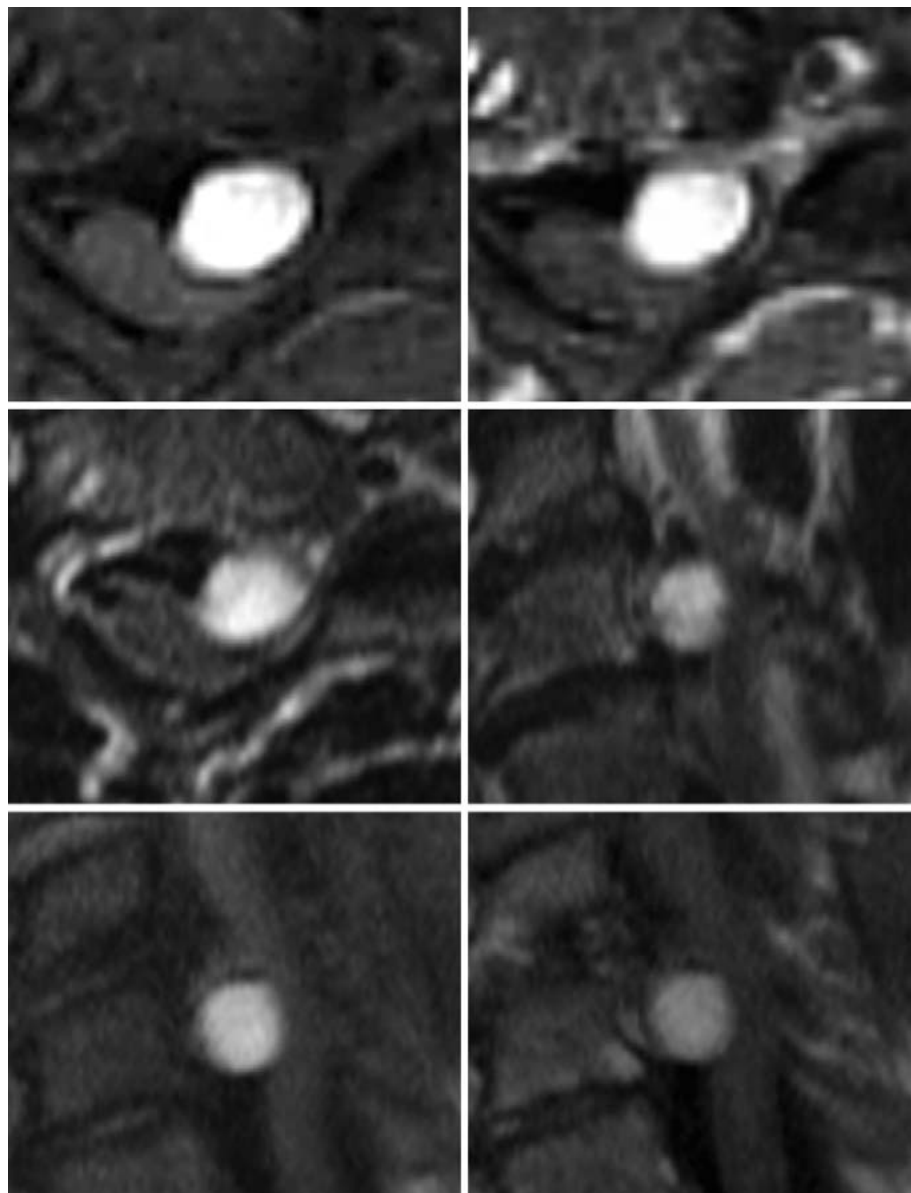


Fig. 1 Axial T₁-sequence with (upper right) and without (upper left) contrast agent. Native T₂-images axial (middle, left) and sagittal (middle, right). Sagittal T₁-sequence with (bottom, right) and without contrast agent (bottom, left).

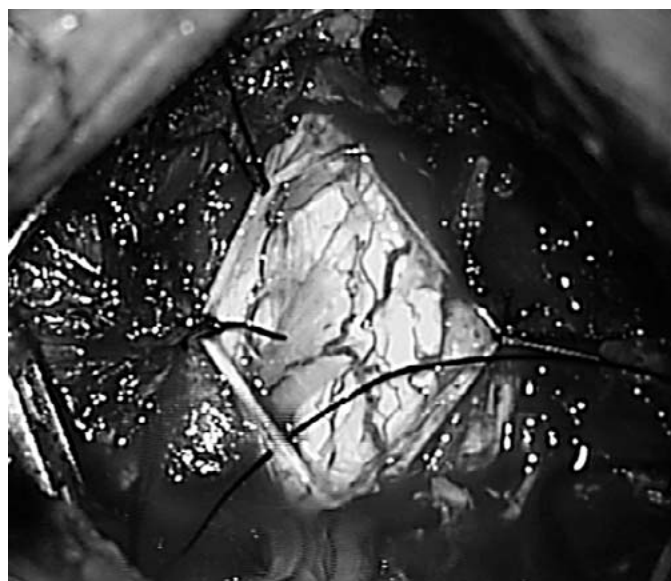


Fig. 2 Intraoperative situation after opening of the dura. Left dorsal root C7 is displaced dorsally by hematoma.

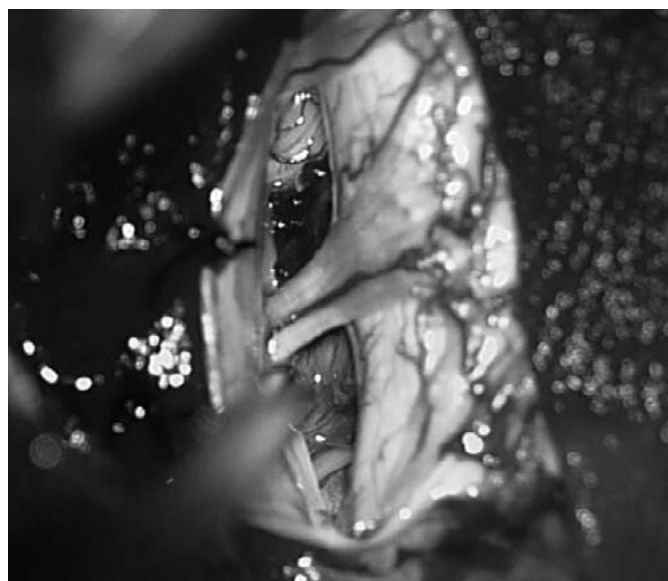

Fig. 3 Situs after removal of hematoma, dorsal root C7 unbent and cavernoma became visible.

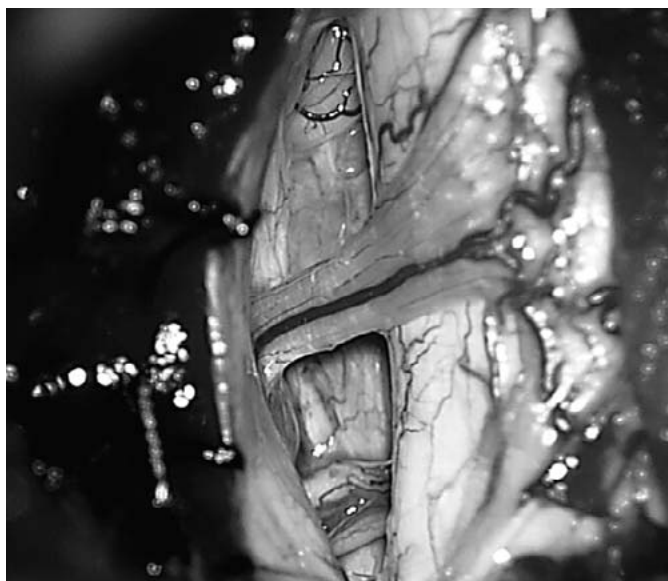


Fig. 4 Situation after complete resection of cavernoma, its origin was the left motor root C7, all neural structures could be preserved and are decompressed.

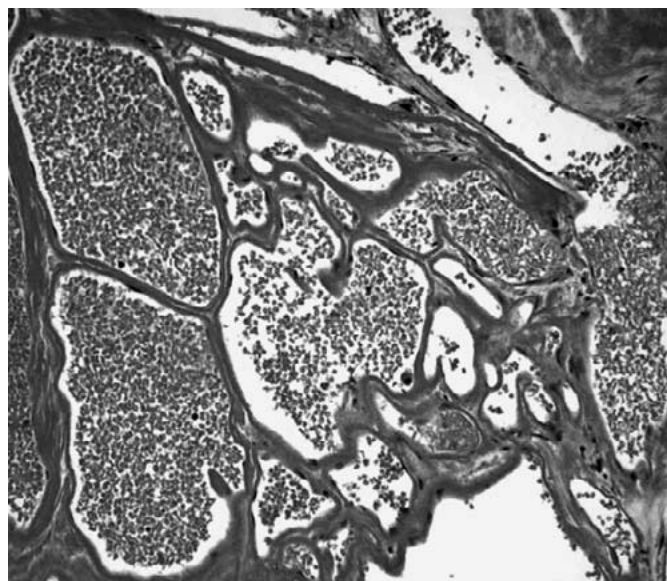


Fig. 5 The lesion is characterized by tightly packed, variably thickened vascular channels lying back to back to each other without intervening tissue (hematoxylin and eosin).

Table 1 Summary of published cases of surgically treated intradural-extramedullary cavernomas

author	year of publication	age [years]/sex	location	symptoms	origin	resection/outcome
Roger	1951	22/f	T11	paresis, sciatic and back pain	not reported	total/deterioration
Floris	1958	57/m	T12	paresis	not reported	total/unknown
Hirsch	1965	20/m	L2/3	paresis, bladder dysfunction, SAH	root	total/incomplete recovery
Pansini	1966	46/m	L2	paresis, bladder dysfunction, sciatic and back pain	root	total/ incomplete recovery
Ortner	1973	22/m	C4–7	SAH	not reported	total/no improvement
Heimberger	1982	24/m	T2/3	SAH	root	total/excellent
Ueda	1987	28/m	L1/2	SAH	root	total/excellent
Pagni	1990	46/m	T12/L1	back pain	root	total/excellent
Ramos	1990	67/f	L3	hydrocephalus	filum terminale	total/excellent
Mastronardi	1991	49/f	T4	sensorimotor deficits	root	total/excellent
Mori	1991	65/m	T1	SAH	spinal cord	total/excellent
Acciarri	1992	54/f	C2/3	SAH	dura mater	total/excellent
Sharma	1992	63/m	T12	sensorimotor deficits, back pain, bladder dysfunction	root/spinal cord	total/no improvement
		43/m	T5	SAH	root/spinal cord	total/excellent
Bruni	1994	28/m	L2	SAH	root	total/excellent
Cervoni	1995	26/f	L1/2	SAH	root	total/excellent
		32/m	L5	sensorimotor deficits, back pain	root	total/ incomplete recovery
Rao	1997	60/m	L1–3	sensorimotor deficits	root	total/excellent
		35/f	T12	sensorimotor deficits	spinal cord	subtotal/no improvement
Duke	1998	49/f	L1	sensory deficits, back pain	root	total/excellent
Nozaki	2003	51/m	C5/6	sensorimotor deficits	root/dentate ligament	total/excellent

13]. In most cases cavernomas are circumscribed lesions allowing safe resection with excellent neurological outcomes. The case presented in this study is the fourth published case of a cervical, intradural-extramedullary cavernoma and it is very compatible with the majority of the other reports on this entity. Like in approximately two thirds of the reported cases, the patient is male and the lesion originated from a nerve root. Pain was the leading symptom and the therapy of choice was surgery. As in most other published cases, a complete resection was accomplished with an excellent functional outcome and an improvement of the patient's preoperative complaints. Intraoperatively we could not definitely confirm a SAH, but found a hematoma anterior to the left dorsal root C7, thus proving an episode of hemorrhage. In view of the patient's history, SAH seems very likely and in our opinion was responsible for the pain longitudinally affecting the whole spine, while direct compression of the nerve roots is likely to be the reason for the more chronic shoulder pain. Retrospectively the hypesthesia of the right forearm must be regarded as independent from the operated cavernoma and could be attributed to an ulnar nerve entrapment syndrome. Interpretation of MRI findings was difficult as there was no characteristic hemosiderin rim in T₂-weighted images. The homogenous hyperintense appearance in both T₁- and T₂-sequences included the differential diagnosis of a lipoma, which was ruled out by fat suppressed sequences (STIR). Application of contrast media did not result in a significant enhancement. Due to the patient's history the differential diagnosis included the residuum of an intraspinal infection as well as schwannoma and eventually cavernoma. Since preoperative MRI did not reveal the nature of the lesion, we decided on a more generous spinal exposure, although retrospectively a left-sided hemilaminectomy of C6 and a partial hemilaminectomy of C7 would have been sufficient for a safe removal of both tumor and hematoma.

Conclusion

Despite their rareness, intradural-extramedullary cavernous hemangiomas of the spine have to be taken into account as a potential cause in patients with signs of spinal SAH and/or spinal nerve compression syndromes. As in the present case, interpretation of MRI may be difficult, especially after an episode of hemorrhage when no hemosiderin rim is detected. Nevertheless, MRI provides clear morphologic definition of the lesion and remains the diagnostic procedure of choice. Surgical removal yields an excellent result and is the therapy of choice for symptomatic intradural-extramedullary cavernomas.

References

- Acciarri N, Padovani R, Pozzati E, Gaist G, Manetto V. Spinal cavernous angioma: a rare cause of subarachnoid hemorrhage. *Surg Neurol* 1992; 37: 453–456
- Bruni P, Massari A, Greco R, Hernandez R, Oddi G, Chiappetta F. Subarachnoid hemorrhage from cavernous angioma of the cauda equina: case report. *Surg Neurol* 1994; 41: 226–229
- Cervoni L, Celli P, Gagliardi FM. Cavernous angioma of the cauda equina: report of two cases and review of the literature. *Neurosurg Rev* 1995; 18: 281–283
- Duke BJ, Levy AS, Lillehei KO. Cavernous angiomas of the cauda equina: case report and review of the literature. *Surg Neurol* 1998; 50: 442–445
- Fahlbusch R, Strauss C, Huk W, Röckelein G, Kömpf D, Ruprecht KW. Surgical removal of pontomesencephalic cavernous hemangiomas. *Neurosurgery* 1990; 26: 449–457
- Floris V. Angiome angiomatosi del sistema nervosa. *Lav Neuropsich* 1958; 27: 159–379
- Harrison MJ, Eisenberg MB, Ullman JS, Oppenheim JS, Camins MB, Post KD. Symptomatic cavernous malformations affecting the spine and spinal cord. *Neurosurgery* 1995; 37: 195–205
- Heimberger K, Schnaberth G, Koos W, Pendl G, Auff E. Spinal cavernous haemangioma (intradural-extramedullary) underlying repeated subarachnoid haemorrhage. *J Neurol* 1982; 226: 289–293
- Hirsch JF, Pradat P, David M. [Cavernous angioma of the cauda equina] (French). *Neurochirurgie* 1965; 11: 323–327
- Mastronardi L, Ferrante L, Scarpinati M, Gagliardi FM, Celli P, Fortuna A. Intradural extramedullary cavernous angioma: case report. *Neurosurgery* 1991; 29: 924–926
- Mori K, Ishii H, Tomita Y, Morimoto K, Maeda M. Intradural-extramedullary spinal cavernous angioma – case report. *Neurol Med Chir (Tokyo)* 1991; 31: 593–596
- Nagi S, Megdiche H, Bouzaïdi K, Haouet S, Khouja N, Douira W, Sebai R, Chaabene S, Zitouna M, Touibi S. Imaging features of spinal epidural cavernous malformations. *J Neuroradiol* 2004; 31: 208–213
- Nozaki K, Inomoto T, Takagi Y, Hashimoto N. Spinal intradural extramedullary cavernous angioma. *J Neurosurg* 2003; 99 (Spine 3): 316–319
- Ortner WD, Kubin H, Pillz P. Ein zervikales kavernöses Angiom. *Fortschr Roentgenstr* 1973; 118: 475–476
- Padovani R, Acciarri N, Giulioni M, Pantieri R, Foschini MP. Cavernous angiomas of the spinal district: surgical treatment of 11 patients. *Eur Spine J* 1997; 6: 298–303
- Pagni CA, Canavero S, Forni M. Report of a cavernoma of the cauda equina and review of the literature. *Surg Neurol* 1990; 33: 124–131
- Pansini A, Lo Re F. Raro caso di angiocavernoma della cauda. *Mem Soc Tos Um Chir* 1966; 27: 679–696
- Rao GP, Bhaskar G, Hemaratnan A, Srinivas TV. Spinal intradural extramedullary cavernous angiomas: report of four cases and review of the literature. *Br J Neurosurg* 1997; 11: 228–232
- Ramos Jr F, de Toffol B, Aesch B, Jan M. Hydrocephalus and cavernoma of the cauda equina. *Neurosurgery* 1990; 27: 139–142
- Roger H, Paillas JE, Bonnal J, Vigouroux R. [Angiomas of the spinal cord and nerve roots]. *Acta Neurol Psych Belg* 1951; 7: 491–495
- Sharma R, Rout D, Radhakrishnan VV. Intradural spinal cavernomas. *Br J Neurosurg* 1992; 6: 351–356
- Ueda S, Saito A, Inomori S, Kim I. Cavernous angioma of the cauda equina producing subarachnoid hemorrhage. Case report. *J Neurosurg* 1987; 66: 134–136