

Deterioration of Hemiparesis after Recurrent Stroke in the Unaffected Hemisphere: Three Further Cases with Possible Interpretation

Shiro Yamamoto^a Masashi Takasawa^b Koji Kajiyama^a Jean-Claude Baron^b
Takenori Yamaguchi^a

^aDepartment of Neurology, Kansai Rosai Hospital, Hyogo, Japan;

^bStroke Research Group, Department of Clinical Neurosciences, University of Cambridge, Cambridge, UK

Key Words

Corticospinal tract • Extrapyramidal motor pathway •
Neural tract • Reorganization, neural • Stroke

Abstract

Background: The concept of neural reorganization after brain damage is already well established, and many previous studies have successfully reported the translocation of the neural activation in the motor-related cortices during motor tasks using functional imaging modalities. Several primate and human studies have suggested the formation of newly reorganized tracts in the ipsilesional or contralesional hemisphere, but the mechanism for the formation of these tracts is still largely unknown. **Methods:** Three acute stroke patients who presented with abrupt deterioration of their right-sided hemiparesis due to the infarcts following a recurrent stroke in the originally unaffected hemisphere were studied using magnetic resonance imaging (MRI), MR angiography and single-photon emission CT. The relationship between the neurological symptom on admission and the precise location of the new infarct was carefully investigated from the perspective of reorganization. **Results:** Diffusion-weighted MRI showed a new subcortical infarct in the right hemisphere contralateral to the initial stroke in all patients. These new lesions involved the thalamus, globus pallidus or corona radiata, sparing the area of the internal capsule. T₂-

weighed MRI on admission showed an old infarct in the left middle cerebral artery territory, which had caused the original right-sided hemiparesis. **Conclusion:** It is proposed that the 'extrapyramidal' motor pathway in the unaffected hemisphere is associated with poststroke neural reorganization.

Copyright © 2007 S. Karger AG, Basel

Introduction

It has recently been suggested that reorganization of the central neural system plays an important role in the recovery of motor function after stroke [1, 2]. Previous reports have shown evidence of reorganization in motor-related cortices after stroke, by means of positron emission tomography [3, 4] or functional magnetic resonance imaging (fMRI) [5, 6] during various motor tasks. Both cross-sectional and longitudinal studies have been successfully performed to detect the translocation of activation in motor-related cortices or interhemispheric balance of activation [1, 3, 4, 6]. Transcranial magnetic stimulation (TMS) [7, 8] and near-infrared spectroscopic imaging [9] also showed the existence of reorganization after stroke. Recently Konishi et al. [10] evaluated the corticospinal tract (CST) and stroke recovery, using MR tractography, but pointed out the technical limitation to depict the precise neural tracts.

Based on these previous studies, distinct anatomical neural tracts related to the motor system have been thought to participate in neural reorganization. The bilateral CST has been proposed to participate in this phenomenon [1–9]. However, there are no detailed studies on the role of ‘extrapyramidal’ tracts in forming the reorganized network after the stroke.

Subjects and Methods

Patients

Three acute stroke patients who presented with abrupt deterioration of their right-sided hemiparesis due to subsequent infarcts in the originally unaffected hemisphere were studied using magnetic resonance imaging (MRI), MR angiography (MRA) and single-photon emission CT (SPECT). Each patient was scored on the National Institute of Health Stroke Scale (NIHSS) [11] and the Medical Research Council (MRC) score [12]. The relationship between the neurological symptom on admission and the precise location of the new infarct was retrospectively investigated from the perspective of reorganization.

MRI Protocol

All examinations were performed on a 1.5-tesla MRI system (Signa, GE Medical Systems) with echoplanar imaging capability and the use of a standard protocol. Diffusion-weighted images [DW-MRI; repetition time (TR) = 5,999 ms; echo time (TE) = 104 ms; slice thickness = 5 mm; $b = 1,000 \text{ s/mm}^2$], T_2 -weighted images (TR = 4,000 ms; TE = 83.6 ms; slice thickness = 5 mm) and MRA (TR = 26 ms; TE = 6.9 ms; slice thickness = 0.6 mm; matrix 256×160) were acquired. MRA images were processed with a maximum intensity projection, 3-dimensional time-of-flight technique.

SPECT Imaging Protocol

SPECT imaging was performed using a 2-headed rotating gamma camera (Millennium VG, GE Medical systems) interfaced with a dedicated computer system. Sixty images were acquired using a 64×64 matrix and a low-energy high-resolution collimator during a 180° rotation. The transaxial slices were reconstructed using filtered backprojection with a Butterworth filter. The patients were allowed to rest in a quiet, dimly lit room and were intravenously injected with 111 MBq of ^{123}I N-isopropyl-*p*-iodoamphetamine (^{123}I -IMP). Imaging was carried out 15–40 min after the injection of the radiotracer.

Results

Patient 1

A 74-year-old right-handed man had residual right hemiparesis and conduction aphasia from a brain infarction that had occurred 11 years before. He had been able to walk with a cane until 2 days before admission, when his right hemiparesis deteriorated and he became unable

to walk. On admission the MRC score of the right upper extremity was 2/5 and that of the right lower extremity 3/5. The right limbs were spastic. The deep tendon reflexes of the upper limbs were brisk bilaterally, and there was hyperreflexia in the right lower limb. A Babinski sign was present on the right. There was slight right upper motor neuron facial palsy with dysarthria. The score on the NIHSS was 9/42. He did not exhibit left hemiparesis. T_2 -weighted MRI on admission showed an old extensive infarct in the left corona radiata with some cortical extension into the left middle cerebral artery (MCA) territory (fig. 1a, 2a, b). DW-MRI, however, demonstrated an acute lacunar infarct in the right lateral thalamus at the junction of the internal capsule (fig. 1b, 2c). MRA revealed an occlusion of the left MCA trunk (fig. 1c), and ^{123}I -IMP SPECT performed 3 days after admission showed a marked reduction in the cerebral blood flow in the region supplied by the left MCA only (fig. 1d). Within a week he had fully recovered to the same level as before admission; the MRC score of the right upper limb improved to 3/5 and that of the right lower to 4/5. The score on the NIHSS was 7/42 on discharge.

Patient 2

A 76-year-old right-handed man, with residual right hemiparesis and Wernicke aphasia due to a stroke 11 years before, experienced sudden deterioration of his right hemiparesis. Until then he had been able to walk without a cane, but he suddenly became unable to walk. The right limbs were slightly spastic. The MRC scores of the right upper and lower extremities on admission were 3/5. The deep tendon reflexes of the right limbs were brisk, and a Babinski sign was present on the right. The score on the NIHSS was 5/42. The left side was unaffected. T_2 -weighted MRI showed an old infarct in the left corona radiata with an extensive cortical infarct in the left MCA territory (fig. 2d, e). However, DW-MRI revealed a small round high-intensity area in the right corona radiata, suggesting a fresh infarction (fig. 2f). MRA showed an occlusion of the left MCA at the trifurcation, and ^{123}I -IMP SPECT performed 3 days after admission demonstrated a reduction in the cerebral blood flow in the left MCA region only. He made a gradual recovery within 1 week of admission. The MRC score of the right upper and lower limbs improved to 4/5. The score on the NIHSS was 4/42 on discharge.

Patient 3

A 64-year-old right-handed man had incurred chronic right hemiparesis and dysarthria 4 years before. Al-

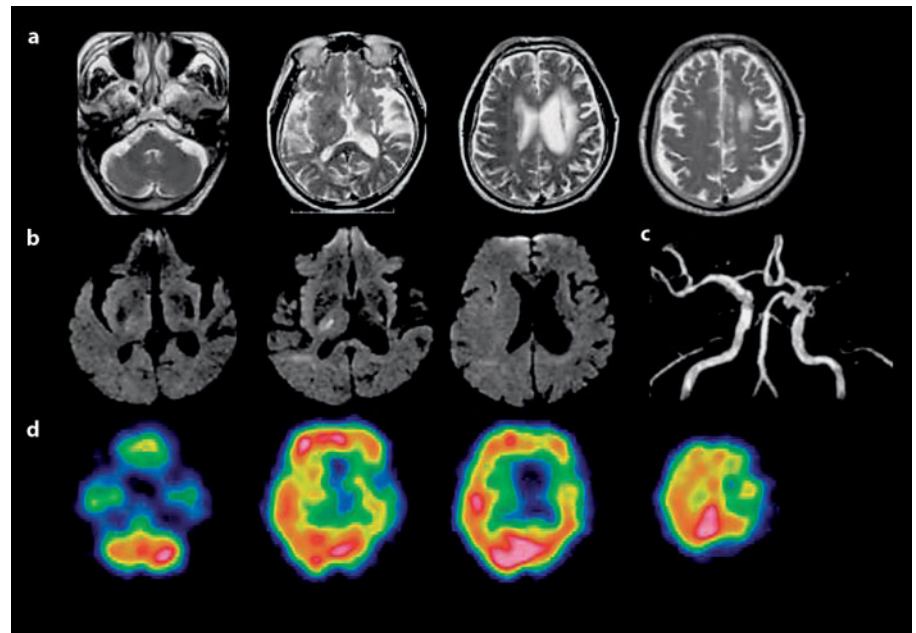


Fig. 1. Patient 1: T₂-weighted MRI (a), DW-MRI (b), MRA (c) and ¹²³I-IMP SPECT (d). DW-MRI on admission revealed the high-intensity lesion in the right lateral thalamus at the junction of the internal capsule, in the hemisphere contralateral to the initial stroke.

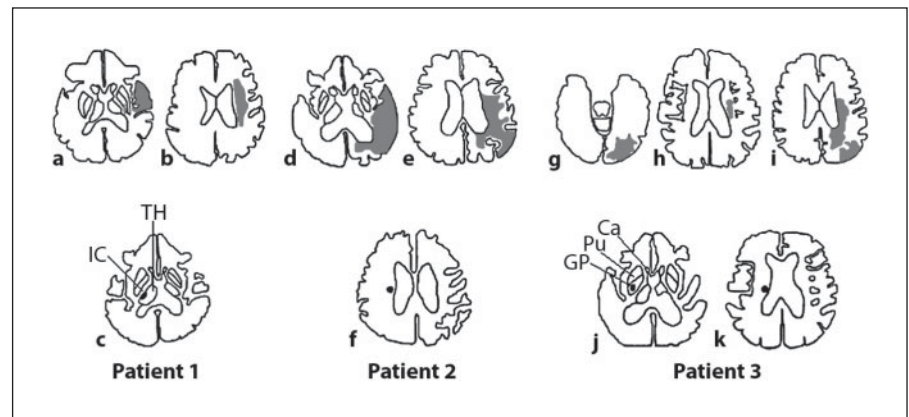


Fig. 2. The 3 patients' MRI to determine the location of the initial and recurrent infarcts. Initial infarcts (gray areas in a, b, d, e, g, h and i) and recurrent infarcts (black points in c, f, j and k). The fresh infarcts (black points) in all patients did not involve the area of the internal capsule. a–c Patient 1. d–f Patient 2. g–k Patient 3. IC = Internal capsule; Th = thalamus; GP = globus pallidus; Pu = putamen; Ca = caudate nucleus.

though he had recovered to the point of being able to walk without a cane and to write with a pen, his right hemiparesis deteriorated a few days before admission, and he became unable to walk unassisted and unable to write. He presented with right hemiparesis, predominating in the proximal limbs, with impairment of coordinated movements. The MRC scores of the right upper and lower extremities on admission were both 3/5. There was right facial palsy and dysarthria. The score on the NIHSS was 4/42. There were no signs of left hemiparesis. T₂-weighted MRI showed old lacuna infarcts in the left paraventricular region and a chronic cortical infarct in the left occipital lobe (fig. 2g, h, i). DW-MRI revealed a fresh infarct in the right corona radiata and globus pallidus (fig. 2j, k). MRA showed a tight stenosis of the posterior

division of the left MCA. ¹²³I-IMP SPECT performed 2 days after admission showed a reduction in the cerebral blood flow in the left MCA region. He recovered to the same level as before admission within 1 week. The MRC score of the right upper and lower limbs improved to 4/5. The score on the NIHSS was 3/42 on discharge.

Discussion

The uncrossed CST (uncrossed pyramidal tract) has been proposed to participate in reorganization after stroke [1–9]. However, there are no detailed studies on the role of extrapyramidal tracts in the reorganized network after stroke. In this study the relationship between the

symptoms of the secondary neurological deterioration and the precise locations of the infarcts were used to investigate the neural tracts underlying the reorganization after stroke.

Regarding the CST, the axons in the motor-related cortices descend through the subcortical white matter, gather in the internal capsule and then descend to the cerebral peduncle [13, 14]. It has been reported that the severity of the motor deficit after stroke is related to a lesion involving the internal capsule, which is a pivotal area for the CST [15, 16]. Most CST fibers cross to the opposite side in the medulla at the pyramidal decussation, but around 10% of the fibers do not cross until they reach the level of the spinal cord, at which point they terminate. The uncrossed CST extends only to the upper thoracic cord and primarily innervates the muscles of the neck, trunk and proximal upper extremities [13, 14].

Recent neuroimaging studies documented poststroke reorganization [1, 2]. Cao et al. [5] demonstrated that bilateral primary sensorimotor cortices were activated during paretic hand movement using fMRI and proposed that the uncrossed CST might be recruited for the activation in the contralesional hemisphere. Ago et al. [17] reported a similar case in which a subsequent lacunar infarct in the corona radiata of the unaffected hemisphere caused deterioration of the original hemiparesis. They suggested the uncrossed CST in the unaffected hemisphere could intensify the motor recovery or neural reorganization. Using both TMS and fMRI, Johansen-Berg et al. [8] provided evidence that the activation of the contralesional dorsal premotor area has an important role in affected hand movement. They proposed that uncrossed CST from the contralesional dorsal premotor area might be recruited after stroke. However, TMS studies do not strongly support a role for the uncrossed CST in ipsilateral fine hand movement of stroke [1, 2, 7, 8]. Also, imaging studies do not generally support the idea that the contralateral motor-related areas participate in recovery, although opinions diverge [1–6].

Fisher [18] reported 2 cases with subsequent strokes. Based on detailed neurological observations and pathological studies, the uncrossed CST was suggested to have participated in the motor recovery. Moreover author implied that the extrapyramidal tract might also be among the possible tracts underlying the motor recovery.

Among the extrapyramidal tracts, several motor-related cortical areas, including the primary motor, premotor and supplementary motor areas, send fibers to the ipsilateral caudate nucleus and putamen as the corticostriate fibers [19]. Contralateral projections from these

cortical areas cross the midline in the corpus callosum and enter the caudate nucleus and the putamen as a transhemispheric connection [20]. The globus pallidus, which receives fibers from the caudate nucleus and putamen, is the main receiving center and is connected with the subthalamic nucleus, substantia nigra, reticular formation and red nucleus, which discharge to the lower motor neurons at all levels of the cord via the reticulospinal and rubrospinal tracts. The reticulospinal tract has both crossed and uncrossed fibers at the spinal level. The globus pallidus is connected to the thalamus, which in turn is connected back to the caudate nucleus and the motor-related cortical areas, thus establishing a feedback mechanism [19]. This extrapyramidal tract is correlated with highly coordinated, quick but instinctive movement and crude movement, and thus constitutes a primitive motor tract [19].

The study by Alagona et al. [7], using TMS and motor-evoked potentials, assumed that the corticoreticulospinal tract in the unaffected hemisphere might play a role in stroke recovery. In their recent review, Calautti and Baron [1] concluded that the involvement of the contralesional hemisphere was important for motor recovery, together with the enhanced activity of the ipsilesional motor network. They suggested the corticoreticulospinal tract receiving from premotor areas could subserve the motor recovery after damage of the motor cortices sparing the internal capsule.

In our cases the new lesion spared the internal capsule in the right hemisphere and induced neurological deterioration of the pre-existing right-sided hemiparesis. Patient 1 had a recurrent infarct in the lateral thalamus (fig. 2c), patient 2 in the corona radiata (fig. 2f) and patient 3 in the corona radiata and globus pallidus (fig. 2j, k). Although a recurrent infarct in the corona radiata of patients 2 and 3 might be close to the pyramidal tract [21], the corticostriate fibers should be involved in these lesions [20]. In addition the globus pallidus was affected by the infarct in patient 3. Considering the locations of recurrent infarcts in our patients, extrapyramidal tracts might be more likely to participate in reorganization after the first stroke. It is intriguing that in most of the previously reported cases as well as in our patients [17, 22] the new infarct caused deterioration of ipsilateral previous hemiparesis, but no detectable deficit, contralaterally, which might be a characteristic feature of reorganization in the contralateral side, possibly involving the extrapyramidal motor pathway whose damage would not normally cause a neurological deficit ('silent stroke') but become 'eloquent'.

It would have been of interest to obtain the motor-evoked potentials in our patients to demonstrate the unchanged situation of the CSTs, but this was not possible.

In conclusion this study suggests that the extrapyramidal motor pathway in the contralesional hemisphere is associated with neural reorganization. In the clinical setting neurological deterioration in the original hemiparesis may be useful in clarifying the reorganized motor pathways after stroke.

Acknowledgments

The authors would like to thank the staff of the Department of Radiology, Kansai Rosai Hospital, for their technical support in performing MRI and SPECT imaging and Mr. P. Simon Jones (MSc) at the University of Cambridge for the preparation of the manuscript.

References

- Calautti C, Baron JC: Functional neuroimaging studies of motor recovery after stroke in adults: a review. *Stroke* 2003;34:1553–1566.
- Rossini PM, Calautti C, Pauri F, Baron JC: Post-stroke plastic reorganization in the adult brain. *Lancet Neurol* 2003;2:493–502.
- Calautti C, Leroy F, Guincestre JY, Baron JC: Displacement of primary sensorimotor cortex activation after subcortical stroke: a longitudinal PET study with clinical correlation. *NeuroImage* 2003;19:1650–1654.
- Calautti C, Leroy F, Guincestre JY, Baron JC: Dynamics of motor network overactivation after striatocapsular stroke. *Stroke* 2001;32:2534–2542.
- Cao Y, D'Olhaberriague L, Vikingstad EM, Levine SR, Welch KM: Pilot study of functional MRI to assess cerebral activation of motor function after poststroke hemiparesis. *Stroke* 1998;29:112–122.
- Marshall RS, Perera GM, Lazar RM, Krakauer JW, Constantine RC, DeLaPaz RL: Evolution of cortical activation during recovery from corticospinal tract infarction. *Stroke* 2000;31:656–661.
- Alagona G, Delvaux V, Gerard P, De Pasqua V, Pennisi G, Delwaide PJ, Nicoletti F, Maertens de Noordhout A: Ipsilateral motor responses to focal transcranial magnetic stimulation in healthy subjects and acute-stroke patients. *Stroke* 2001;32:1304–1309.
- Johansen-Berg H, Rushworth MF, Bogdanovic MD, Kischka U, Wimalaratna S, Matthews PM: The role of ipsilateral premotor cortex in hand movement after stroke. *Proc Natl Acad Sci USA* 2002;99:14518–14523.
- Miyai I, Yagura H, Oda I, Konishi I, Eda H, Suzuki T, Kubota K: Premotor cortex is involved in restoration of gait in stroke. *Ann Neurol* 2002;52:188–194.
- Konishi J, Yamada K, Kizu O, Ito H, Sugimura K, Yoshikawa K, Nakagawa M, Nishimura T: MR tractography for the evaluation of functional recovery from lenticulostriate infarct. *Neurology* 2005;64:108–113.
- The NINDS rt-PA Stroke Study Group: Tissue plasminogen activator for acute ischemic stroke. *N Engl J Med* 1995;333:1581–1587.
- Medical Research Council: Aids to Examination of the Peripheral Nervous System. London, HMSO, 1976.
- Carpenter MB, Sutin J: Tracts of the spinal cord; in *Human Neuroanatomy*, ed 8. Baltimore, Williams & Wilkins, 1983, pp 265–314.
- Davidoff RA: The pyramidal tract. *Neurology* 1990;40:332–339.
- Fries W, Danek A, Scheidtmann K, Hamburger C: Motor recovery following capsular stroke. *Brain* 1993;116:369–382.
- Morecraft RJ, Herrick JL, Stilwell-Morecraft KS, Louie JL, Schroeder CM, Ottenbacher JG, Schoolfield MW: Localization of arm representation in the corona radiata and internal capsule in the non-human primate. *Brain* 2002;125:176–198.
- Ago T, Kitazono T, Ooboshi H, Takada J, Yoshiura T, Mihara F, Ibayashi S, Iida M: Deterioration of pre-existing hemiparesis brought about by subsequent ipsilateral lacunar infarction. *J Neurol Neurosurg Psychiatry* 2003;74:1152–1153.
- Fisher CM: Concerning the mechanism of recovery in stroke hemiplegia. *Can J Neurol Sci* 1992;19:57–63.
- Gertz SD: Subcortical motor area; in *Liebman's Neuroanatomy Made Easy and Understandable*, ed 6. Gaithersburg, Aspen, 1999, pp 29–32.
- Carpenter MB, Sutin J: The corpus striatum; in *Human Neuroanatomy*, ed 8. Baltimore, Williams & Wilkins, 1983, pp 579–611.
- Morecraft RJ, Herrick JL, Stilwell-Morecraft KS, Louie JL, Schroeder CM, Ottenbacher JG, Schoolfield MW: Localization of arm representation in the corona radiata and internal capsule in the non-human primate. *Brain* 2002;125:176–198.
- Song YM, Lee JY, Park JM, Yoon BW, Roh JK: Ipsilateral hemiparesis caused by a corona radiata infarct after a previous stroke on the opposite side. *Arch Neurol* 2005;62:809–811.

Copyright: S. Karger AG, Basel 2007. Reproduced with the permission of S. Karger AG, Basel.
Further reproduction or distribution (electronic or otherwise) is prohibited without permission
from the copyright holder.