

# Asymmetric Cerebral Lesion Pattern in X-linked Adrenoleukodystrophy

Shuang Wang\*, Ji-Min Wu, Yuan-Shen Cheng

*Department of Neurology, Second Affiliated Hospital, School of Medicine, Zhejiang University, China.*

X-linked adrenoleukodystrophy (X-ALD) is an inherited disease caused by peroxisomal dysfunction. X-ALD usually involves the cerebral white matter in an approximately symmetric way. We report a 10-year-old boy with the cerebral form of X-ALD who presented with cognitive impairment and left spastic hemiparesis. Brain magnetic resonance imaging (MRI) showed asymmetric lesions, and the lesions in the right hemisphere were predominant. In the late stage of the disease, bilateral limbs were involved. The cerebral lesions enlarged and appeared approximately symmetric on MRI. The purpose of our report is to highlight asymmetric demyelination in initial presentation of X-ALD. [*J Chin Med Assoc* 2006;69(8):383–386]

**Key Words:** adrenoleukodystrophy, hemiparesis, magnetic resonance imaging

## Introduction

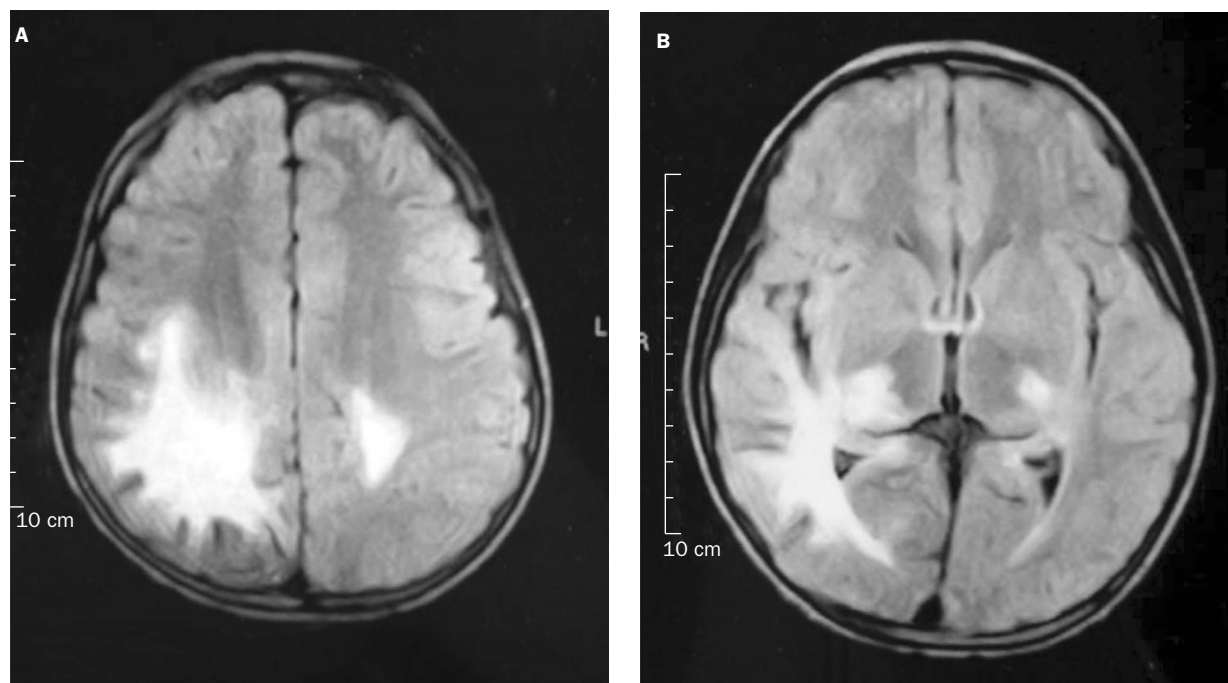
X-linked adrenoleukodystrophy (X-ALD) is a peroxisomal disorder. It is inherited in a X-linked recessive manner. The defective gene in X-ALD maps to Xq28 and codes for adrenoleukodystrophy protein, which is a peroxisomal membrane protein. Deficiency of the protein leads to the accumulation of very-long-chain free fatty acid (VLCFA) in the brain, adrenal cortex, and plasma.<sup>1</sup> Clinically, X-ALD is characterized by progressive demyelination of the nervous system and dysfunction of the adrenal glands. It includes 3 main clinical phenotypes: childhood cerebral form, adrenomyeloneuropathy, and Addison-only form with no neurologic involvement. Usually, X-ALD affects the cerebrum in an approximately symmetric way, and the highly asymmetric pattern of cerebral lesions is rare. In the present report, we describe a 10-year-old boy with the cerebral form of X-ALD who presented with cognitive impairment and left spastic hemiparesis, and consistently with asymmetric lesions predominantly involving the right hemisphere as revealed by brain magnetic resonance imaging (MRI). Previous reports of atypical forms of X-ALD are also reviewed in this article.

## Case Report

A Chinese boy was admitted because of cognitive impairment and left hemiparesis. He was the first child of a healthy 25-year-old mother, who had an uneventful pregnancy, labor, and delivery. His early developmental milestones were normal. The family history was uneventful. Hyperpigmentation was noted at the age of 3 years. The symptom was stable and the boy developed normally. At the age of 8, he showed low scholastic performance. Six months later, a dragging of the left leg and unsteady gait were noted by his parents. He soon got weakness in the left hand, within the next several weeks. Brain MRI in the local hospital revealed diffuse white matter lesion (Figure 1). Gadolinium enhancement was present at the lesion margin (not shown). Three months later, the patient visited our outpatient department. He was alert and cooperative during physical examination. Mild generalized pigmentation of the skin was found. Neurologic examination revealed moderate cognitive impairment, slurred speech, and left homonymous hemianopia. The left limbs and the left side of the patient's face showed spastic hemiparesis and diminished pinprick and temperature sensations. Positive Babinski sign was found

\*Correspondence to: Dr Shuang Wang, Department of Neurology, Second Affiliated Hospital, School of Medicine, Zhejiang University, 88, Jiefang Road, Hangzhou 310009, China.

E-mail: freud\_wang@hotmail.com • Received: May 17, 2005 • Accepted: April 21, 2006



**Figure 1.** Magnetic resonance imaging (TR 2,100 ms, TE 100 ms) disclosed lesions in bilateral thalamus, posterior limb of internal capsule, subcortical areas of the occipito-parieto-temporal region, and midbrain (midbrain not shown in the 2 slices). The lesions were massive and predominantly located in the right hemisphere.

over the left side. Finger-to-nose maneuvers were normal on the right, but unable to be performed on the left because of weakness.

No abnormalities were found during the routine laboratory investigations. Primary adrenal insufficiency was indicated by the following tests. Serum adrenocorticotropin was elevated ( $>1,250$  pg/mL; reference,  $<46$  pg/mL). Morning serum cortisol ( $4.87$   $\mu$ g/dL; reference,  $6.2$ – $19.4$   $\mu$ g/dL), 24-hour urine cortisol excretion ( $11.3$   $\mu$ g; reference,  $21$ – $143$   $\mu$ g), 24-hour urine 17-hydroxysteroid excretion ( $8.8$   $\mu$ mol; reference,  $13.9$ – $38.8$   $\mu$ mol), and 17-ketosteroid excretion ( $12.9$   $\mu$ mol; reference,  $20.8$ – $76.3$   $\mu$ mol) were decreased. No abnormality was found in adrenal ultrasonic scan. Thyroid hormones, postexercise lactate level, and ceruloplasmin were all within normal ranges. Visual evoked potential test revealed that P100 latency was delayed in the left eye ( $121.8$  ms) and normal in the right eye ( $96.6$  ms). Electroencephalogram disclosed diffuse slow waves and sporadic spikes with high voltage over the right temporal and parietal lobes.

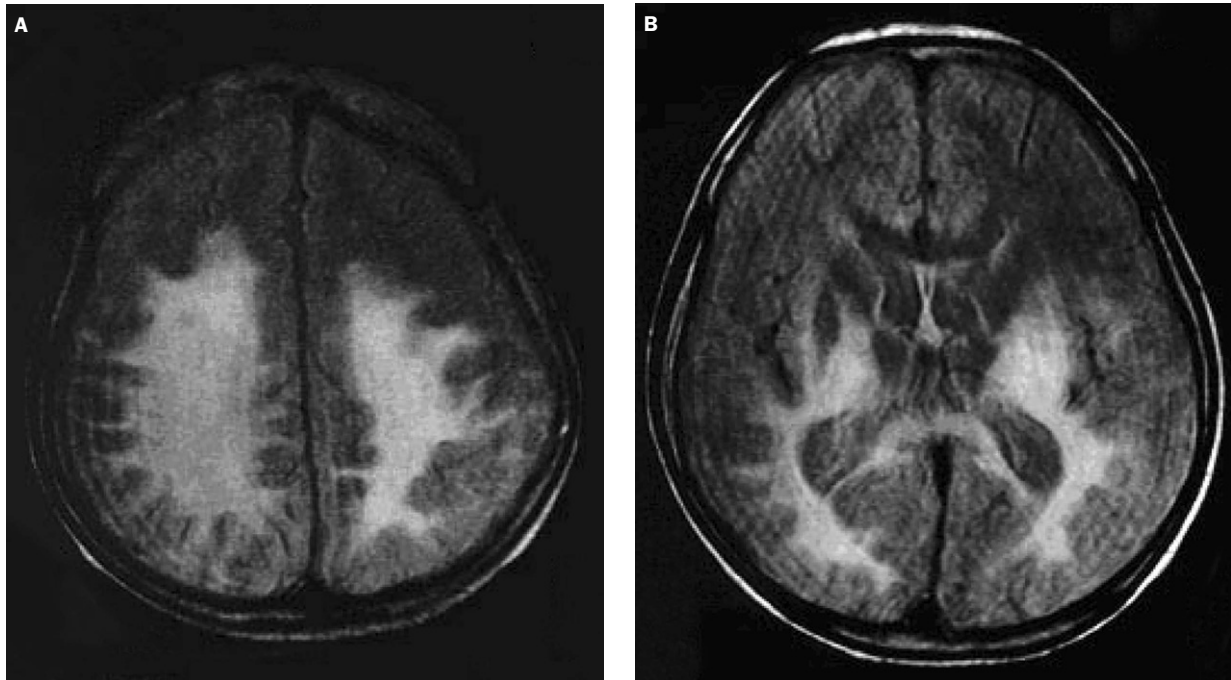
Blood VLCFA assay was performed at the Kennedy Krieger Institute (USA). For the patient's mother, hexacosanoic acid (C26:0) was elevated ( $0.920$   $\mu$ g/mL; reference,  $0.10$ – $0.38$ ) and the ratios of C24/C22 ( $1.241$ ; reference,  $0.68$ – $0.88$ ) and C26/C22 ( $0.051$ ; reference,  $0.007$ – $0.013$ ) were increased. Her results

were consistent with being a carrier of X-ALD. For the patient's father, the results were normal (C26:0,  $0.120$ ; C26/C22,  $0.877$ ; C26/C22,  $0.008$ ). For the patient, both the amount of C26:0 ( $1.410$   $\mu$ g/mL) and the ratios of C24/C22 ( $1.761$ ) and C26/C22 ( $0.105$ ) were much higher than normal references. His results were consistent with the biochemical defect for X-ALD.

According to the biochemical findings, primary adrenal insufficiency and central nervous involvement, the diagnosis of X-ALD (childhood cerebral form) was made when the boy was 9 years old. The patient was given oral prednisone  $15$  mg/day. After a few months, the skin hyperpigmentation was partially reversed, but the neurologic symptoms were exacerbated. The patient gradually got dysphagia and weakness over the right limbs. At the age of 10, severe quadriplegia appeared and he became unresponsive and remained immobilized in bed. When the boy was 11 years old, he developed severe dysphagia and required tube feeding. Brain MRI revealed that the cerebral lesions were significantly enlarged and appeared symmetric (Figure 2).

## Discussion

Typical brain lesions in X-ALD share the same characteristics in different races. In Chinese, X-ALD usually



**Figure 2.** Magnetic resonance imaging (TR 3,640 ms, TE 119 ms) 2 years later showed that the lesions were significantly enlarged. The lateral ventricles were dilated due to atrophy of the brain.

affects the bilateral posterior parieto-occipital white matter in an approximately symmetric way.<sup>2</sup> The lesions can advance anteriorly, affecting the bilateral posterior limbs of the internal capsule and temporal lobes, and inferiorly the brainstem. The splenium of corpus callosum involvement can converge the bilateral lesions into one, giving the “butterfly-like” appearance on MRI. In the childhood cerebral form of X-ALD, enhancement at the margin of the foci is often observed on MRI (also observed in our case) because of the increased permeability of the blood–brain barrier due to inflammatory response in the pathogenesis. Neurologic symptoms of X-ALD include behavioral and cognitive disorder, visual and auditory impairment, quadriplegia, dysphagia, seizure and ataxia.<sup>2,3</sup> However, our patient presented with cognitive impairment and left hemiparesis. Hemiparesis, caused by early involvement of pyramidal tracts in the patient’s right hemisphere, is an unusual manifestation in X-ALD. The highly asymmetric lesion pattern has never been reported in a Chinese population. In our case, the right-sided movement impairment finally appeared together with dysphagia. As brain MRI revealed in the late stage of the disease, the lesions significantly enlarged in both hemispheres, especially the left. It suggests that X-ALD will finally involve the whole cerebral white matter, no matter how the initial lesions are distributed.

Atypical forms of X-ALD have been documented in the literature. Early involvement of the frontal lobe occurs in about 10% of cases.<sup>4,5</sup> Asymmetric cerebral involvement presents in less than 5% of cases. Afifi et al<sup>6</sup> reported a 4.8-year-old boy whose MRI showed a right anterior white matter lesion extending into the ipsilateral putamen and thalamus. Sakakibara et al<sup>7</sup> reported a 25-year-old man with a right caudate head lesion simulating brain tumor. Waragai et al<sup>8</sup> described a case in which the cerebellum and brain stem were predominantly involved. A 13-year-old boy with asymmetric cerebral involvement who presented with generalized seizures was reported by Williams et al.<sup>9</sup>

Atypical forms of X-ALD highlight the fact that the cerebral lesions in X-ALD can present in various patterns. It is easy to misdiagnose patients with no or atypical neurologic symptoms. Since atypical forms of X-ALD have seldom been reported in Chinese populations, X-ALD has probably been underdiagnosed in Chinese. VLCFA assay and mutation analysis are very reliable diagnostic tests. For X-ALD hemizygotes, VLCFA assay is highly reliable. For X-ALD heterozygotes, mutation analysis is the most reliable. However, these tests have not been widely used because few laboratories are validated to perform them. Current therapies such as oral administration of Lorenzo Oil and bone marrow transplantation are effective only in the early stage of X-ALD. Therefore,

these tests should be carried out earlier to reduce delay in diagnosis.

## References

1. Moser H, Dubey P, Fatemi A. Progress in X-linked adrenoleukodystrophy. *Curr Opin Neurol* 2004;17:263–9.
2. Xiong H, Zhang YH, Qin J, Xiao JX, Shi CY, Zhou SM, Wu XR. Clinical characteristics of X-linked adrenoleukodystrophy. *Zhonghua Er Ke Za Zhi* 2003;41:203–7.
3. Zhang J, Chen J, Xue QM. X-linked adrenoleukodystrophy: an analysis of 12 cases. *Chin J Neurol* 2002;35:298–300.
4. Marler JR, O'Neill BP, Forbes GS, Moser HW. Adrenoleukodystrophy (ALD): clinical and CT features of a childhood variant. *Neurology* 1983;33:1203–5.
5. Castellote A, Vera J, Vazquez E, Roig M, Belmonte JA, Rovira A. MR in adrenoleukodystrophy: atypical presentation as bilateral frontal demyelination. *Am J Neuroradiol* 1995;16:814–5.
6. Afifi AK, Menezes AH, Reed LA, Bell W. Atypical presentation of X-linked childhood adrenoleukodystrophy with an unusual magnetic resonance imaging pattern. *J Child Neurol* 1996;11:497–9.
7. Sakakibara R, Fukutake T, Arai K, Katayama K, Mori M, Hattori T. Unilateral caudate head lesion simulating brain tumour in X-linked adult onset adrenoleukodystrophy. *J Neurol Neurosurg Psychiatry* 2001;70:414–5.
8. Waragai M, Takaya Y, Hayashi M. MRI of adrenoleukodystrophy involving predominantly the cerebellum and brain stem. *Neuroradiology* 1996;38:788–91.
9. Williams GA, Pearl GS, Pollack MA, Anderson RE. Adrenoleukodystrophy: unusual clinical and radiographic manifestation. *South Med J* 1998;91:770–4.