

Surgical Treatment of Non-ruptured Giant Occipital Arteriovenous Malformations With Frequent Migraine-Like Headache

—Two Case Reports—

Shinji NAGATA, Takato MORIOKA, Yoshihiro NATORI*, and Tomio SASAKI

Department of Neurosurgery, Kyushu University Graduate School of Medical Sciences, Fukuoka, Fukuoka; *Department of Neurosurgery, Aso Iizuka Hospital, Iizuka, Fukuoka

Abstract

Two patients with giant occipital arteriovenous malformation (AVM) underwent microsurgical treatment among 294 patients with intracranial AVM treated between 1981 and 2004. The patients were aged 52 and 65 years and showed common symptoms consisting of long-term frequent migraine-like headaches with visual aura and recent homonymous hemianopia. Common neuroimaging findings were abundant dural feeders plus feeders from the posterior, middle, and anterior cerebral arteries, and deep drainers to the galenic system. Both patients underwent preoperative staged embolization and total microsurgical removal of the nidus with a neuronavigation system. Both patients returned to ordinary life without the need for assistance. These findings emphasize that giant occipital AVM, even if unruptured, is surgically treatable with acceptable morbidity.

Key words: giant arteriovenous malformation, occipital lobe, migraine, microsurgery

Introduction

Surgical treatment is not recommended for most Spetzler-Martin grade IV and V arteriovenous malformations (AVMs)⁴⁾ because of the generally low rate of hemorrhage, high risk of hemorrhage after incomplete excision of the nidus, and high mortality and morbidity after total resection. The American Heart Association Scientific Statement¹¹⁾ and Japanese Guidelines¹⁴⁾ on the management of intracranial AVMs also recommend conservative follow up for grade IV and V AVMs unless accompanied by massive hematoma, associated aneurysm, or progressive neurological deterioration.^{4,10,12,14,16)} However, giant occipital AVMs are good candidates for microsurgery despite their size.²²⁾ Here we describe two cases of giant occipital AVM cured by microsurgery.

Case Reports

We treated 294 patients with intracranial AVM at

the Department of Neurosurgery, Kyushu University Graduate School of Medical Sciences, and the Department of Neurosurgery, Aso Iizuka Hospital between 1981 and 2004. These cases included 27 occipital AVMs, of which two were Spetzler and Martin grades IV and V. These patients presented with severe frequent migraine-like headaches and complete homonymous hemianopia, so we selected microsurgical treatment combined with staged embolization with n-butyl 2-cyanoacrylate (NBCA).

Case 1: A 52-year-old woman had suffered from severe frequent migraine-like headaches with visual aura for 30 years. She gradually noticed left visual field cut 3 years previously without sudden symptoms or other neurological deficits. She visited a local hospital. Brain computed tomography (CT) and magnetic resonance (MR) imaging showed a giant right occipital AVM (Fig. 1). The maximum diameter of the nidus was more than 6 cm on MR imaging. The nidus partially extended to the major forceps of the corpus callosum and anteriorly compressed the trigone of the lateral ventricle. The main feeders were the posterior cerebral artery and dural feeders from the middle meningeal and

Received September 14, 2005; Accepted April 3, 2006

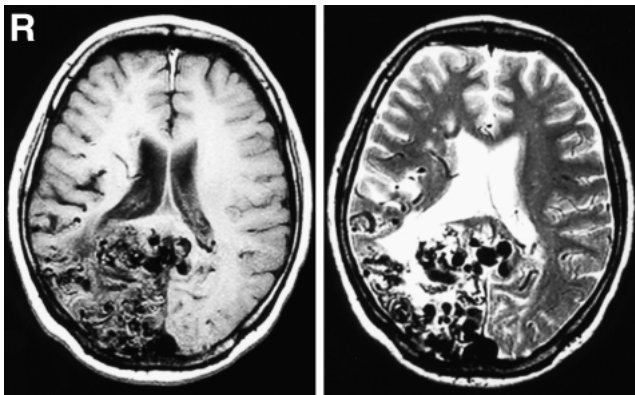


Fig. 1 Case 1. Brain T₁- (left) and T₂-weighted (right) magnetic resonance images showing flow voids in the whole right occipital lobe and enlarged draining veins in the retrosplenial region. The medial wall of the trigone of the lateral ventricle was compressed by the extension of the nidus to the major forceps of the corpus callosum.

vertebral arteries. The anterior two-thirds of the nidus was supplied by pial feeders and the posterior one-third by dural feeders. Deep venous drainage was identified and the perimesencephalic veins were enlarged (Fig. 2). The diagnosis was Spetzler and Martin grade V. She was referred to us for surgery.

On admission, she had complete left homonymous hemianopia confirmed by formal ophthalmologic visual field testing and mild left hemiparesis. To reduce the blood flow and prevent overload of the surrounding brain, preoperative embolization of both pial and dural feeders was performed in six sessions with NBCA. Fifty days after the last embolization, the nidus of the AVM was completely removed with the aid of a neuronavigation system.

Postoperative angiography detected neither the residual nidus nor arteriovenous shunts (Fig. 3). After surgery, she showed deterioration of the left hemiparesis. Rehabilitation helped her recover and return to normal life without the need for assistance in 3 months. The headaches completely disappeared after surgery without the need for medication.

Case 2: A 65-year-old man had suffered from almost daily migraine-like headaches with visual aura for 20 years. He gradually noticed difficulty in driving his car due to visual field cut 3 years previously, without sudden symptoms or other neurological deficits. He visited a local hospital. Brain CT and MR imaging showed a giant left occipital AVM with a maximum diameter of more than 6 cm (Fig. 4). He was referred to us for surgery.

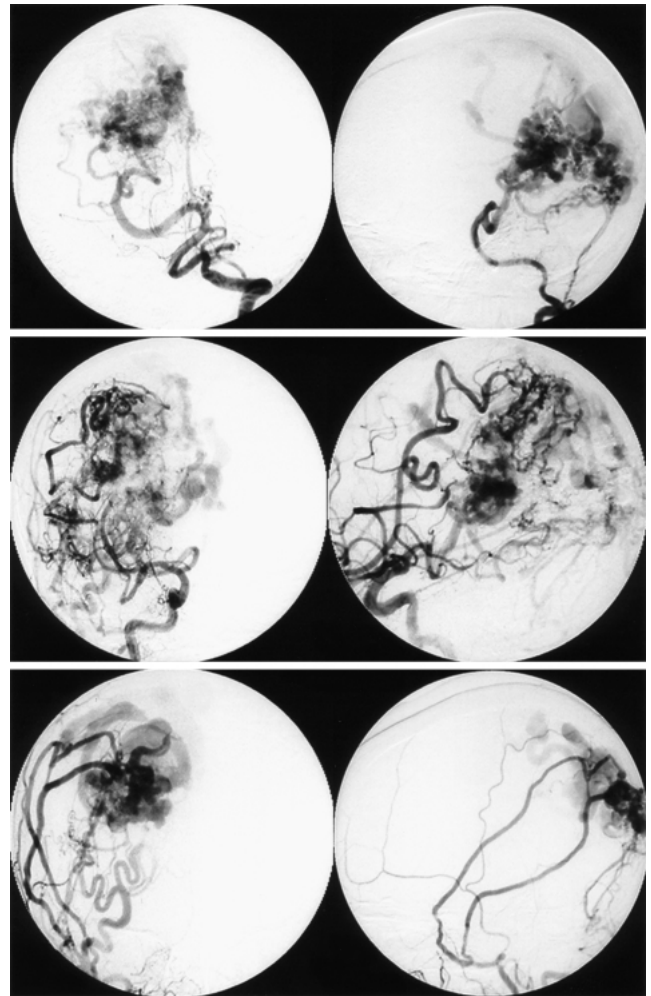


Fig. 2 Case 1. upper row: Preoperative left vertebral angiograms showing enlarged pial feeders from the right posterior cerebral artery and dural feeders from the vertebral artery. middle row: Preoperative right internal carotid angiograms showing participation of the middle cerebral artery in the anterior part of the nidus. The nidus was clearly visualized via the well-developed posterior communicating artery. lower row: Preoperative right external carotid angiograms showing enlarged middle meningeal arteries feeding the torcular portion of the arteriovenous malformation.

On admission, he had no neurological deficits except complete right homonymous hemianopia. Cerebral angiography showed pial feeders mostly from the posterior and middle cerebral arteries supplying the anterior two-thirds of the nidus. Dural feeders from the middle meningeal and vertebral arteries supplied the posterior one-third (Fig. 5). The diagnosis was Spetzler and Martin grade IV

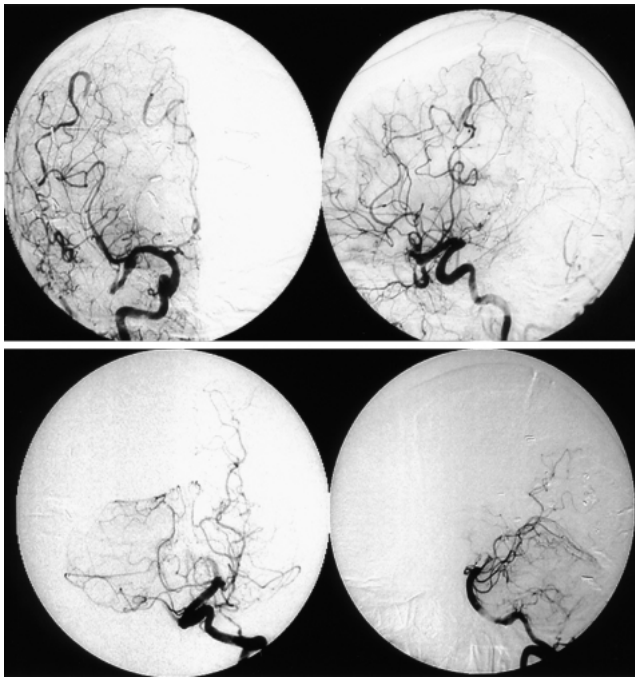


Fig. 3 Case 1. Postoperative right internal carotid (upper row) and left vertebral angiograms (lower row) showing no residual nidus or arteriovenous shunt confirming total removal of the arteriovenous malformation.

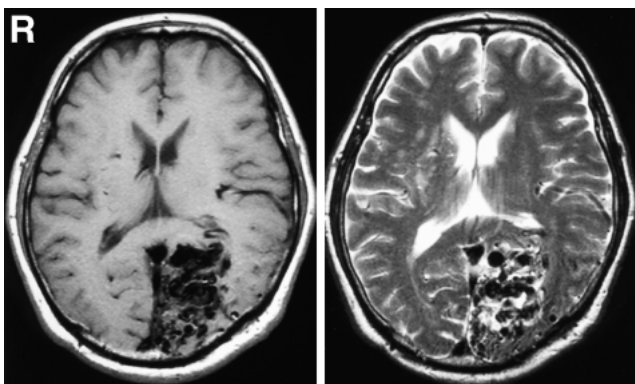


Fig. 4 Case 2. Brain T₁- (left) and T₂-weighted (right) magnetic resonance images showing flow voids in the left occipital lobe and enlarged draining veins in the retrosplenial region. The trigone of the lateral ventricle was anteriorly shifted due to compression of the major forceps of the corpus callosum by the arteriovenous malformation.

because of the complete homonymous hemianopia. Two-stage embolization of the pial and dural feeders with NBCA was performed before surgery. Twenty-seven days after the last embolization, the nidus of

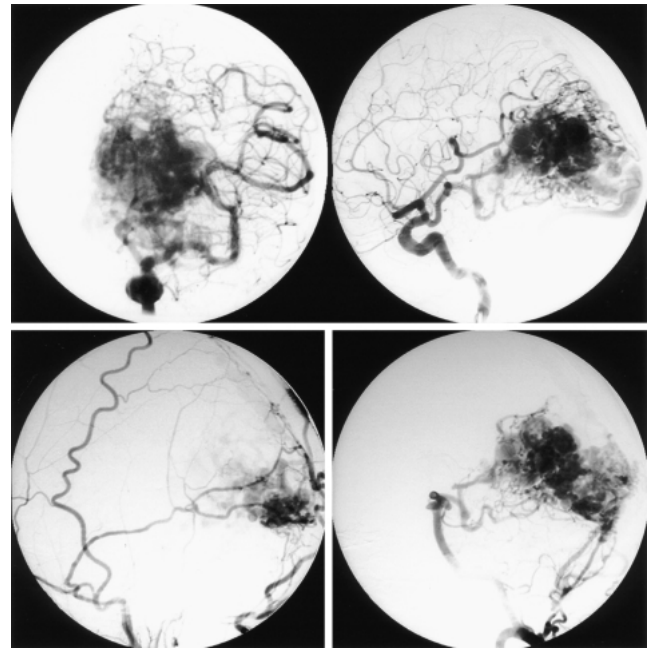


Fig. 5 Case 2. Left internal carotid (upper row), external carotid (lower left), and vertebral angiograms (lower right) showing the anterior two-thirds of the nidus was supplied mainly by the posterior cerebral artery together with the middle and anterior cerebral arteries, and the posterior one-third was supplied by the middle meningeal artery and dural branches of the vertebral artery.

the AVM was completely removed with the aid of the neuronavigation system.

The postoperative course was uneventful and postoperative angiography showed no residual nidus or arteriovenous shunt (Fig. 6). He was discharged without headaches or neurological deficits except the pre-existing right homonymous hemianopia.

Discussion

A large series of 500 intracranial AVMs included 34 occipital AVMs (6.8%), three of which were giant (more than 6 cm in diameter).²²⁾ Surgery in 30 cases including three giant AVMs resulted in favorable outcomes without morbidity or mortality, suggesting that the outcome was independent of size, probably due to the characteristic features of occipital AVMs. The occipital lobe is an eloquent part of the brain, particularly for the optic system. However, optic function has often already been lost in patients with giant occipital AVMs, as in our patients.

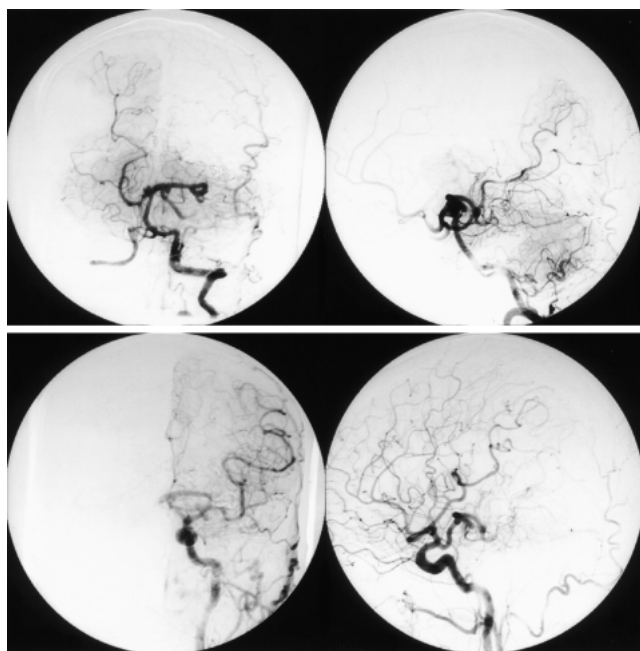


Fig. 6 Case 2. Postoperative left vertebral (upper row) and common carotid angiograms (lower row) showing no residual nidus or arteriovenous shunt, confirming total removal of the arteriovenous malformation.

Moreover, the risk of additional functional deficits is low.

Endovascular embolization is important in multimodality treatment of AVMs, particularly for patients with a nidus volume of more than 10 ml.^{6,13,15,21} Pre-surgical embolization is particularly effective for giant occipital AVMs, because the nidus is usually attached to both the falx and tentorium and receives blood supply from the dural feeders. Both pial and dural feeders are candidates for embolization, but embolization of the dural feeders is reliable and safe, allowing precise obliteration of the compartment of the nidus being fed. Therefore, in contrast to other grade IV and V AVMs, giant occipital AVMs can be cured by surgery with acceptable morbidity.

Headache is a well-known symptom of occipital AVM. Migraine-like headaches occurred in 0–31% of reported cases of intracranial AVM.¹ However, AVM is found in less than 1% of patients with migraine. This symptom is now classified as secondary headache attributed to unruptured AVM.⁵ The pathogenesis of the headache is unclear, but larger nidus volume, tortuous change of the feeding artery, and cortical drainage with reflux in the superior sagittal sinus are associated with higher incidence of headache.⁹ Five of 34 patients with

occipital AVMs had ophthalmic migraine (14.7%).²² Frequent migraine-like headaches prevent a normal life, so resolution by removal of the occipital AVM is desirable.^{3,8,17,20} Frequent migraines or migraine-like headaches should be a factor when considering surgical treatment for occipital AVM, even if the AVM is non-ruptured and/or giant. Middle age is not an indication for more conservative treatment. In fact, patients with AVM identified at higher age show a higher incidence of AVM hemorrhage.¹⁸

The present cases of giant occipital AVM were characterized by recent development of visual field defects and abundant participation of dural feeders. Moreover, both patients noticed gradual visual field cut. Because neither showed signs of AVM rupture, such as sudden headache or other neurological symptoms, the recent visual field cut might be attributable to developmental growth of the AVM. An immunohistochemical study suggested that transient regional hypoxia within the AVM nidus might mediate neoangiogenesis related to growth of the nidus.¹⁹ Previous cases of AVM recurrence after surgical excision and postoperative angiographic disappearance suggest that regrowth of the remnant arteriovenous shunt will result in development of de novo AVM nidus.^{2,7} We speculate that development of the dural feeders might further enhance gradual growth of the nidus, resulting in homonymous hemianopia. Giant occipital AVMs might enlarge beyond the extent of the occipital lobe, becoming inoperable and incurable, and as a result, the severe migraine-like headaches and AVM will persist.

Therefore, microsurgical treatment of giant occipital AVMs is indicated in patients with complete homonymous hemianopia, even if the AVM is not ruptured.

References

- 1) Bruyn GW: Intracranial arteriovenous malformation and migraine. *Cephalalgia* 4: 191–207, 1984
- 2) Gabriel EM, Sampson JH, Wilkins RH: Recurrence of a cerebral arteriovenous malformation after surgical excision. Case report. *J Neurosurg* 84: 879–882, 1996
- 3) Haas DC: Arteriovenous malformations and migraine: case reports and an analysis of the relationship. *Headache* 31: 509–513, 1991
- 4) Han PP, Ponce FA, Spetzler RF: Intention-to-treat analysis of Spetzler-Martin grades IV and V arteriovenous malformations: natural history and treatment paradigm. *J Neurosurg* 98: 3–7, 2003
- 5) Headache Classification Subcommittee of the International Headache Society: The International Classification of Headache Disorders: 2nd edition. *Cephalalgia* 24 Suppl 1: 9–160, 2004
- 6) Hongo K, Koike G, Isobe M, Watabe T, Morota N,

- Nakagawa H: Surgical resection of cerebral arteriovenous malformation combined with pre-operative embolization. *J Clin Neurosci* 7 Suppl 1: 88-91, 2000
- 7) Kader A, Goodrich JT, Sonstein WJ, Stein BM, Carmel PW, Michelson WJ: Recurrent cerebral arteriovenous malformations after negative postoperative angiograms. *J Neurosurg* 85: 14-18, 1996
 - 8) Kurita H, Shin M, Kirino T: Resolution of migraine with aura caused by an occipital arteriovenous malformation. *Arch Neurol* 57: 1219-1220, 2000
 - 9) Kurita H, Ueki K, Shin M, Kawamoto S, Sasaki T, Tago M, Kirino T: Headaches in patients with radiosurgically treated occipital arteriovenous malformations. *J Neurosurg* 93: 224-228, 2000
 - 10) Nozaki K, Hashimoto N, Miyamoto S, Kikuchi H: Resectability of Spetzler-Martin grade IV and V cerebral arteriovenous malformations. *J Clin Neurosci* 7 Suppl 1: 78-81, 2000
 - 11) Ogilvy CS, Stieg PE, Awad I, Brown RD Jr, Kondziolka D, Rosenwasser R, Young WL, Hademenos G: AHA Scientific Statement: Recommendations for the management of intracranial arteriovenous malformations: a statement for healthcare professionals from a special writing group of the Stroke Council, American Stroke Association. *Stroke* 32: 1458-1471, 2001
 - 12) O'Laoire SA: Microsurgical treatment of arteriovenous malformations in critical areas of the brain. *Br J Neurosurg* 9: 347-360, 1995
 - 13) Paulsen RD, Steinberg GK, Norbash AM, Marcellus ML, Marks MP: Embolization of basal ganglia and thalamic arteriovenous malformations. *Neurosurgery* 44: 991-996, 1999
 - 14) Shinohara Y, Yoshimoto T, Fuku-uchi Y, Ishigami S: [Japanese Guideline for the Management of Stroke]. Tokyo, Kyouwa-kikaku, 2004, pp 119-122 (Jpn)
 - 15) Soderman M, Andersson T, Karlsson B, Wallace MC, Edner G: Management of patients with brain arteriovenous malformations. *Eur J Radiol* 46: 195-205, 2003
 - 16) Spetzler RF, Martin NA: A proposed grading system for arteriovenous malformations. *J Neurosurg* 65: 476-483, 1986
 - 17) Spierings EL: Daily migraine with visual aura associated with an occipital arteriovenous malformation. *Headache* 41: 193-197, 2001
 - 18) Stapf C, Khaw AV, Sciacca RR, Hofmeister C, Schumacher HC, Pile-Spellman J, Mast H, Mohr JP, Hartmann A: Effect of age in clinical and morphological characteristics in patients with brain arteriovenous malformation. *Stroke* 34: 2664-2670, 2003
 - 19) Sure U, Butz N, Siegel AM, Mennel HD, Bien S, Bertalanffy H: Treatment-induced neoangiogenesis in cerebral arteriovenous malformations. *Clin Neurol Neurosurg* 103: 29-32, 2001
 - 20) Troost BT, Mark LE, Maroon JC: Resolution of classic migraine after removal of an occipital lobe AVM. *Ann Neurol* 5: 199-201, 1979
 - 21) Valavanis A, Yasargil MG: The endovascular treatment of brain arteriovenous malformations. *Adv Tech Stand Neurosurg* 24: 131-214, 1998
 - 22) Yasargil MG: *Microneurosurgery IIIB*. Stuttgart, New York, Georg Thieme Verlag, 1988, pp 152-167

Address reprint requests to: S. Nagata, M.D., Department of Neurosurgery, Kyushu University Graduate School of Medical Sciences, 3-1-1 Maidashi, Higashi-ku, Fukuoka 812-8582, Japan.
e-mail: snagata@ns.med.kyushu-u.ac.jp