

Case report

Delayed neuropsychiatric syndrome in a child following carbon monoxide poisoning

Akiko Kondo ^{a,*}, Yoshiaki Saito ^a, Ayumi Seki ^a, Chitose Sugiura ^a,
Yoshihiro Maegaki ^a, Yusuke Nakayama ^b, Keiichi Yagi ^b, Kousaku Ohno ^a

^a Divisions of Child Neurology, Institute of Neurological Sciences, Faculty of Medicine, Tottori University, Japan

^b Divisions of Emergency and Disaster Medicine, Faculty of Medicine, Tottori University, Japan

Received 16 May 2006; received in revised form 4 August 2006; accepted 6 August 2006

Abstract

Here, we report the case of a five-year-old boy with carbonic monoxide (CO) poisoning. The patient initially recovered after the initiation of hyperbaric oxygen (HBO) therapy, but lethargy as well as visual and gait disturbances appeared two days later. Left hemiparesis and mood lability also subsequently appeared. Slow frontal activity was noted on electroencephalography, while fluid-attenuation inversion recovery and diffusion-weighted magnetic resonance imaging (MRI) revealed high signal-intensity lesions in the hippocampus and deeper layers of the occipital and frontal cerebral cortex. The neurological symptoms subsided gradually during the 10-day course of HBO therapy, but the left-hand paresis and quadrantic hemianopsia persisted, in association with impaired attention, slow mental processing, and incontinence. Lesions in the globus pallidum were noted on follow-up MRI at 14 days, and cortical lesions became evident as linear, low signal-intensity areas on T1-weighted imaging 4 months after presentation. Delayed neuropsychiatric syndrome in CO poisoning is rare in childhood, although children should be carefully monitored after CO exposure. The finding of cortical laminar necrosis in this patient is quite atypical in CO poisoning, and suggests a broader and previously nonpredicted pathomechanism in this condition.

© 2006 Elsevier B.V. All rights reserved.

Keywords: CO poisoning; Delayed neurological sequelae; Laminar necrosis; Cytotoxic edema; Hyperbaric oxygen

1. Introduction

Carbon monoxide (CO) causes tissue hypoxia because it has a greater affinity for hemoglobin than oxygen. Among causes of anoxia, CO poisoning is characterized by a delayed neuropsychiatric syndrome [1–4], which appears 1–240 days after initial recovery from the acute intoxication [1,2]. Symptoms of cognitive, mechanical, and behavioral deterioration have been described with this syndrome, often in association with demyelinating lesions in the periventricular white matter

[5]. Such delayed neurological sequelae are not uncommon in aged populations, but are extremely rare in victims younger than 20 years of age [2]. In this report, we describe the neuropsychiatric symptoms that appeared in a boy after a lucid period following the initial CO insult, together with cortical lesions that were atypical for CO poisoning.

2. Case report

A five-year-old boy was playing with his friends in his father's car with windows almost closed, in which a power generator was running to operate a welding machine outside the car. The three children were found

* Corresponding author. Tel.: +81 859 38 6777; fax: +81 859 38 6779.

E-mail address: holbergs@nifty.com (A. Kondo).

Table 1
Laboratory findings of children on admission after carbon monoxide poisoning

	Patient	Friend 1	Friend 2
Age	5 years	7 years	5 years
Sex	M	F	M
COHb (%)	20.2	35.3	19.2
pH	7.176	7.290	7.408
pCO ₂ (mmHg)	25.6	37.1	22.0
pO ₂ (mmHg)	200	220	215
HCO ₃ (mmol/l)	8.9	17.3	13.6
BE (mmol/l)	-18.1	-8.2	-9.0
Lactate (mmol/l)	12.0	5.9	6.6
CK (IU/l)	698	146	NE

One hundred percentage oxygen had been applied to the children in the ambulance. BE, base excess; CK, creatine kinase; NE, not examined.

unconscious one and half hours later, and were admitted to our hospital. The patients were comatose, but retained spontaneous respiration. Blood lactate was elevated in all three patients, with the boy reported here having the highest level (Table 1). Serum creatine kinase was elevated to 698 IU/l in this patient with MM isozyme predominance (MB isozyme, 15 IU/l). Other laboratory examinations, as well as electrocardiography, showed no further abnormalities. After hyperbaric oxygen (HBO) therapy of 2.0 atmospheres absolute for 1 h, his CO-hemoglobin (CO-Hb) decreased from 20.2% to 0.7%, and the boy appeared fully recovered by the next morning. HBO therapy was continued daily.

Appetite loss and decreased activity was noted on day 3 after the poisoning, while apathy, lethargy, and visual disturbances appeared on day 4 (Fig. 1). Clinical examination revealed that the patient could walk, talk in single words, and track moving objects with both eyes; however his facial expressions appeared apathetic. Electroencephalography (EEG) revealed high-voltage slow activity in the bifrontal and left parietal areas. Visual

disturbances became more severe thereafter, and temper outbursts appeared. Magnetic resonance imaging (MRI) and fluid-attenuation inversion recovery (FLAIR) diffusion-weighted imaging on day six showed high signal intensity in the hippocampus, and occipital and frontal cerebral cortex, respectively (Figs. 2A to C). An apparent diffusion coefficient (ADC) map showed decreased diffusivity in these lesions (Fig. 2D). Purposeful body movements had almost disappeared by this time, particularly in the left extremities, and the Babinski response of the left toe returned on day 7. From then onwards, the patient gradually improved, being able to talk and walk normally by day 14 and run by day 20 of admission. Only the left-hand paresis and left lower-quadrantic hemianopsia persisted. HBO therapy was terminated after 10 days, and the boy was discharged on day 31, when his developmental quotient was estimated as 76. Follow-up MRI on day 17 revealed high signal intensity in the globus pallidus (Fig. 2E) and substantia nigra on T2-weighted and FLAIR images, while the hippocampal and cortical lesions were no longer detected. SPECT showed patchy hypoperfusion in the cerebral cortex on day 19, predominantly over the frontal and parieto-occipital areas, as well as in the cerebellar cortex.

After discharge, the left-hand paresis and quadrantic hemianopsia persisted, along with impaired attention and hyperactivity. Urinary and fecal incontinence also appeared (Fig. 1). At four months of illness, EEG showed a normal waking background but revealed occasional frontal spike-wave discharges with left-sided predominance. MRI showed mild, diffuse atrophy of the cerebral and cerebellar cortex. Abnormal signal intensity at the hippocampus and the globus pallidum had disappeared, but T1-low, T2-high and FLAIR-low signal changes were prominent in the deep cortical layers of the frontal and parieto-occipital areas that had shown low diffusivity at the initial examination (Figs. 2F to

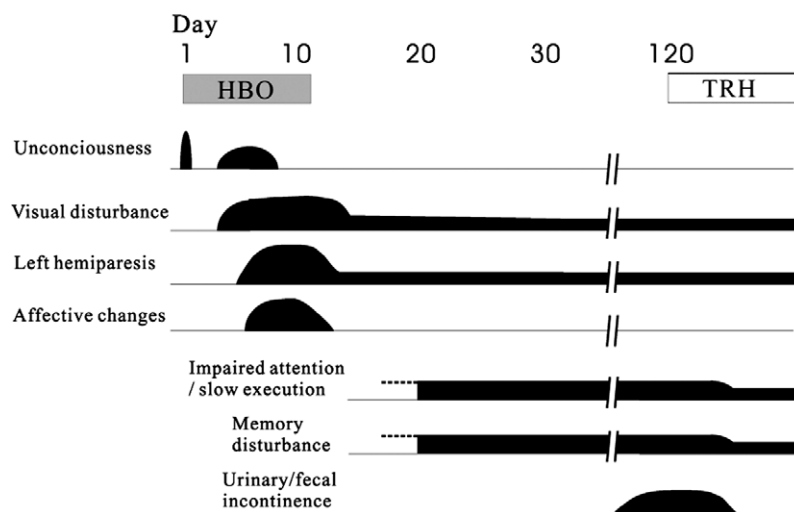


Fig. 1. Clinical course of the patient. HBO, hyperbaric oxygen therapy; TRH, thyrotropin-releasing hormone.

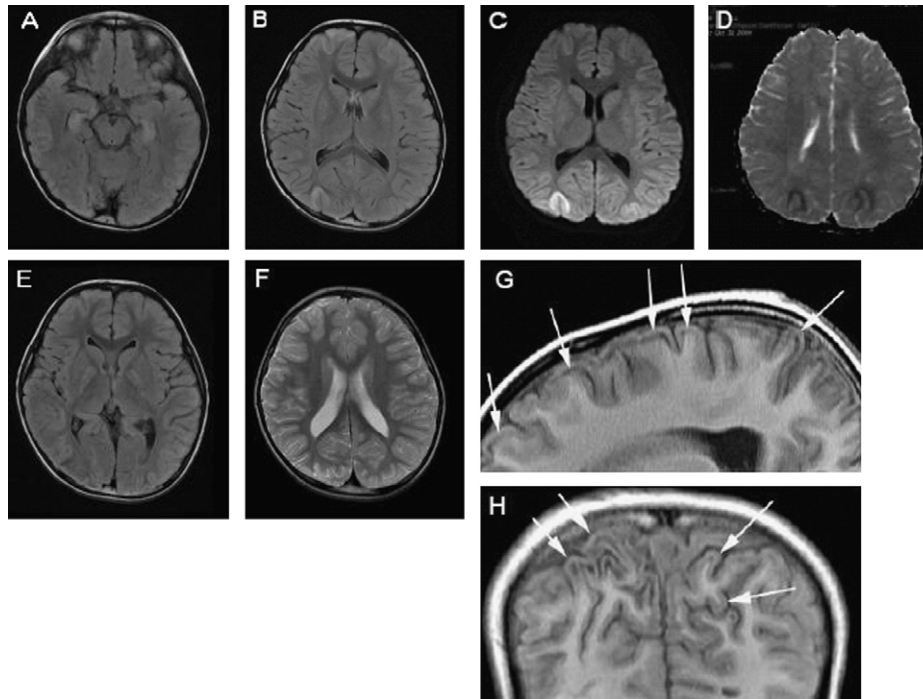


Fig. 2. Brain MRI at day 6 (A to D), day 17 (E), and day 122 (F to H) of illness. (A and B) Fluid-attenuation inversion recovery (FLAIR) images showing high signal intensity in the bilateral hippocampus, right occipital, and right frontal deep layers of cerebral cortex. (C and D) Diffusion-weighted image (DWI, C) shows high intensity at the occipital lesions with right-sided predominance. Decreased diffusivity is noted in these areas on the ADC map (D). (E) Symmetrical, high intensity lesions on FLAIR imaging appeared in the globus pallidus during the recovery phase of delayed encephalopathy. (F to H) Lesions in the deep cortical layers became prominent on follow-up MRI, with high intensity on T2-weighted images (F) and low intensity on T1-weighted images (G and H, arrows).

H). Hypoperfusion of the cerebral cortex was comparable to the initial examination by SPECT study, although cerebellar perfusion was further decreased. Administration of thyrotropin-releasing hormone, 0.05 mg/kg/day for 14 days, resolved the incontinence and improved spatial executive memory scores, although the SPECT findings did not change. The other two children, who showed comparable blood CO–Hb concentrations to the present patient, but milder degree of lactic acidosis, on admission, showed an immediate and full recovery after HBO therapy with no delayed neurological sequelae.

3. Discussion

The biphasic course in certain cases of CO poisoning may stem not only from the anoxia but also from biochemical mechanisms including lipid peroxidation, increased neurotransmitter release, binding of CO to certain intracellular proteins, as well as disruption in cerebrovascular compensation [1,3]. Although periventricular white matter lesions are characteristic in this type of delayed encephalopathy [4], linear lesions in the deeper cerebral cortex layer were prominent in the present patient, and correlated with the clinical symptoms. The distribution of these lesions resembled those

reported with laminar necrosis [6], which occasionally accompanies other types of hypoxic events or metabolic disturbances such as hypoglycemia, but is not usually observed in either monophasic or biphasic CO poisoning. In the present case, however, the hypoxia was most likely a consequence of the CO intoxication, for the following two reasons: (1) the lesions and symptoms appeared after a lucent period, which is characteristic in CO poisoning, and (2) cardiopulmonary involvement was minimal and comparable to that in the other children who were exposed to CO for a similar length of time. In addition, the cortical areas in the case discussed here did not show the high signal intensity on T1-weighted imaging that is typical of laminar necrosis and may represent the presence of fat-laden macrophages. The curvilinear cortical lesions did, however, show decreased diffusivity at the onset of the delayed neuropsychiatric syndrome, suggesting cytotoxic edema [4]. The signal changes may therefore have indicated the formation of cavities at necrotic foci. The presence of patients with cortical laminar necrosis after cyanide intoxication [7] may support that laminar necrosis can result from pure tissue anoxia without ischemia, which is common to CO poisoning.

Inhibition of heme protein cytochrome oxidase [8], which constitutes the last step of mitochondrial electron transport, may have played a role in the elevation of

serum lactate in this patient. Such dysfunction of mitochondrial respiratory chain leads to injury of energy production, and cellular oxidative stress by production of superoxide and hydrogen peroxide. Resultant increase of oxidative stress may be related to the delayed neurological symptoms in CO poisoning [9]. Sakamoto et al. showed that the lactate level in the cerebral white matter on MR spectroscopy had a predictive value for the prognosis of delayed neuropsychiatric sequelae in CO poisoning [10]. The severity of lactic acidosis at initial examination, rather than the CO–Hb level, might be also predictive for the outcome of victims with CO poisoning.

Despite above considerations, the exact pathophysiology of cortical laminar necrosis in this patient, with spared white matter, remains unclear. The biphasic clinical course at the young age of the patient was also atypical in CO poisoning. These findings suggest a broader pathomechanism in this type of intoxication than previously hypothesized, and caution for careful monitoring and appropriate follow-up of children after CO exposure for signs of such late complications.

References

- [1] Ernst A, Zibrak JD. Carbon monoxide poisoning. *N Engl J Med* 1998;339:1603–8.
- [2] Choi IS. Delayed neurologic sequelae in carbon monoxide intoxication. *Arch Neurol* 1983;40:433–5.
- [3] Gorman D, Drewry A, Huang YL, Sames C. The clinical toxicology of carbon monoxide. *Toxicology* 2003;187:25–38.
- [4] Kim J-h, Chang K-H, Song IC, Kim KH, Kwon BJ, Kim H-C, et al. Delayed encephalopathy of acute carbon monoxide intoxication: diffusivity of cerebral white matter lesions. *Am J Neuroradiol* 2003;24:1592–7.
- [5] Lapresle J, Fardeau M. The central nervous system and carbon monoxide poisoning II. Anatomical study of brain lesions following intoxication with carbon monoxide (22 cases). *Prog Brain Res* 1967;24:31–74.
- [6] Takahashi S, Higano S, Ishii K, Matsumoto K, Sakamoto K, Iwasaki Y, et al. Hypoxic brain damage: cortical laminar necrosis and delayed changes in white matter at sequential MR imaging. *Radiology* 1993;189:449–56.
- [7] Riudavets MA, Aronica-Pollak P, Troncoso JC. Pseudolaminar necrosis in cyanide intoxication: a neuropathology case report. *Am J Forensic Med Pathol* 2005;26:189–91.
- [8] Miró Ò, Casademont J, Barrientos A, Urbano-Márquez Á, Cardellach F. Mitochondrial cytochrome c oxidase inhibition during acute carbon monoxide poisoning. *Pharmacol Toxicol* 1998;82:199–202.
- [9] Zhang J, Plantadosi CA. Mitochondrial oxidative stress after carbon monoxide hypoxia in the rat brain. *J Clin Invest* 1992;90:1193–9.
- [10] Sakamoto K, Murata T, Omori M, Kimura H, Noshio M, Murata I, et al. Clinical studies on three cases of the interval form of carbon monoxide poisoning: serial magnetic resonance spectroscopy as a prognostic predictor. *Psychiatr Res Neuroimaging Sect* 1998;83:179–92.