

Vascular

Successful emergent angioplasty of neurosarcoid vasculitis presenting with strokes

Jonathan L. Brisman, MD^{a,*}, Archana Hinduja, MD^b,
James S. McKinney, MD^b, Brian Gerhardstein, MD, PhD^b

^aDepartments of Cerebrovascular and Endovascular Neurosurgery and ^bNeurology, New Jersey Neuroscience Institute at JFK Medical Center, Edison, NJ 08818, USA

Received 31 December 2005; accepted 21 February 2006

Abstract

Background: Sarcoidosis is a systemic disease with neurologic involvement in approximately 5% of cases. Ischemic events related to neurosarcoid vasculitis are rare. We report the successful treatment of symptomatic neurosarcoid vasculitis with angioplasty.

Case Description: A 41-year-old African American with a diagnosis of neurosarcoid presented with aphasia and right-sided weakness. He was treated medically with antiplatelet agents, heparinization, and hypertensive therapy. Despite this treatment, he experienced clinical worsening and radiographic extension of his infarcts. He underwent successful angioplasty of a severe focal stenosis of the left middle cerebral artery. After the procedure, he experienced marked improvement in his symptoms and at follow-up continues to improve.

Conclusions: We report the angiographic demonstration of neurosarcoidosis with large vessel changes and resultant strokes and its successful treatment with balloon angioplasty.

© 2006 Elsevier Inc. All rights reserved.

Keywords:

Angioplasty; Neurosarcoid; Vasculitis; Stroke; Endovascular

1. Introduction

Sarcoidosis is a systemic disease of unknown etiology characterized by noncaseating epithelioid granulomas. Neurological involvement occurs in about 5% of patients with sarcoidosis [9].

Despite evidence for granulomatous involvement of cerebral vessels, ischemic events related to neurosarcoid vasculitis are rare and limited to case reports [1–4,7]. We report the successful angioplasty of a severe focal stenosis of the MCA in a man with presumed neurosarcoid vasculitis and multiple recurrent strokes despite aggressive medical management.

2. Case description

This 41-year-old African American with a diagnosis of neurosarcoidosis, based on a mediastinal lymph node biopsy showing noncaseating granulomatous lymphadenitis, bilateral sensorineural hearing loss, left eye blindness, and an MRI showing diffuse leptomeningeal enhancement, presented with the acute onset of right-sided weakness and aphasia.

Diffusion-weighted MRI showed acute infarction in watershed areas of the left MCA and ACA territories (Fig. 1). Intracranial MRA showed severe stenosis of the proximal left M1 and A1 segments. Cerebrospinal fluid analysis demonstrated an elevated protein and a lymphocytic pleocytosis. He was treated with high-dose steroids, aspirin, and clopidogrel. Three days later the patient experienced worsening of his symptoms and MRI documented extension of his watershed infarcts. A trial of intravenous heparinization and permissive hypertension was instituted.

Abbreviations: ACA, anterior cerebral artery; MCA, middle cerebral artery; MRI, magnetic resonance imaging; MRA, magnetic resonance arteriography.

* Corresponding author. Tel.: +1 732 320 7010; fax: +1 732 632 1584.

E-mail address: jbrisman@solarishs.org (J.L. Brisman).

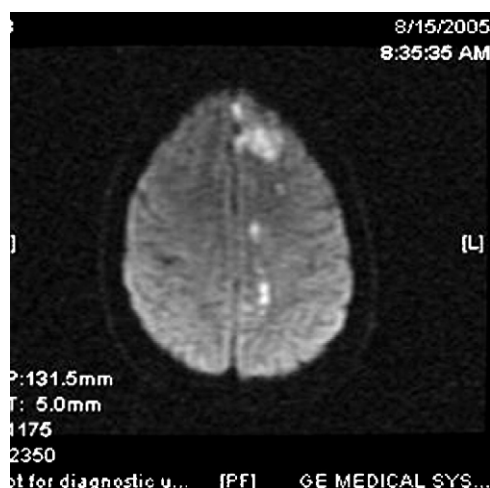


Fig. 1. Acute infarction in the left MCA and ACA watershed territory on diffusion-weighted MRI of the brain.

The following morning, the patient became hemiplegic and mute. Angiography confirmed a very tight focal stenosis of the left M1 and A1 segments (Fig. 2A). Additional areas of smaller vessel “beading” in the posterior circulation consistent with vasculitis were identified (Fig. 2B). Dilatation of the left M1 segment with a compliant Sentry balloon (Boston Scientific/Target Therapeutics) was first attempted. This was unsuccessful and therefore a noncompliant coronary Maverick balloon (Boston Scientific/Target Therapeutics) measuring 3×30 mm was used and a moderate dilatation of the stenosis was achieved (Fig. 2C). Because of the uncertainty in the response of the narrowed vessel to manipulation, angioplasty as opposed to stent placement was chosen as the more conservative approach. The intention was to place a stent at a later date based on the patient’s recovery and the result of follow-up angiography.

The patient experienced immediate improvement with increased right-sided strength and began to speak a few

words. At 5 months’ follow-up, the patient has normal function of his right arm and leg, and is conversant with a mild expressive aphasia. The patient’s plavix had to be discontinued because of gastrointestinal bleeding. Because of this, and because the patient has a stable neurologic exam, we have decided not to place a stent in the MCA at this time.

3. Discussion

Neurosarcoidosis most often presents with cranial palsies, predominantly affecting the optic and facial nerves, reflecting its predilection for the base of the brain. Hypothalamic and pituitary involvement is also common as is the development of lesions in the spinal cord, cerebellum, hemispheres, and peripheral nerves as the disease progresses [1,9].

Involvement of the leptomeninges results in a typical appearance of thickening and enhancement on MRI and an associated angiitis [8,9]. Perivascular infiltration with granulomas associated with neurosarcoid tends to affect the smaller perforating arteries, with involvement of larger arteries being much less common [8]. Symptoms of neurosarcoid such as progressive encephalopathy, confusion, and dementia have been ascribed to long-standing microvascular changes of presumed granulomatous angiitis. Despite the description of cerebral vasculitis as a well-known pathologic component of neurosarcoid, however, clinical manifestations of acute ischemia or territorial infarction appear rare and have been limited to case reports [1-4,7]. We report the first instance of angiographic demonstration of large vessel vasculopathic changes with resultant strokes and its successful treatment with balloon angioplasty.

Intracranial angioplasty and/or stent placement for intracranial vascular stenoses is an accepted technique to achieve revascularization in patients with lesions resulting in cerebral ischemia despite best medical efforts [5]. Unlike

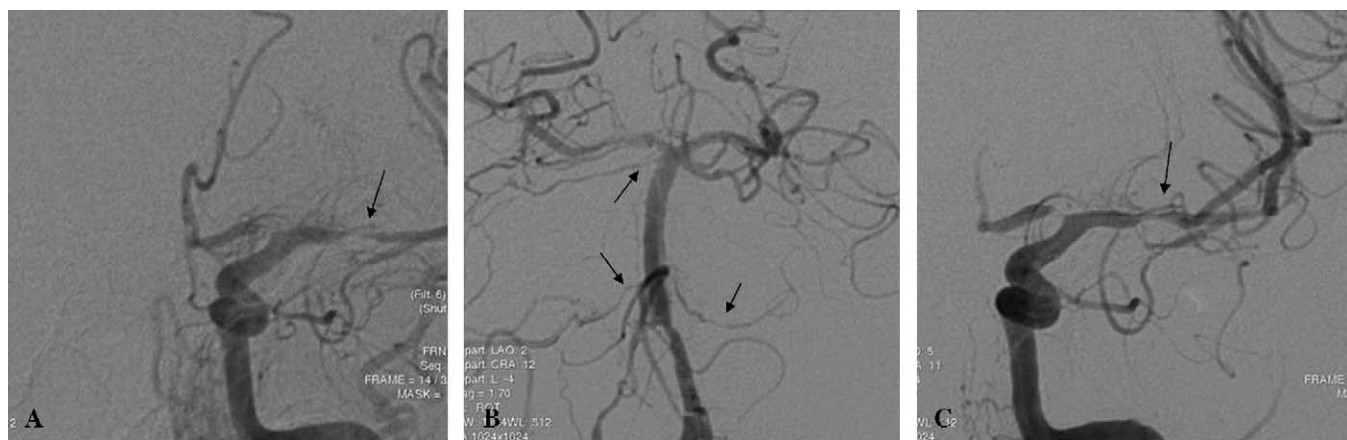


Fig. 2. A: Left internal carotid artery angiogram (posterior-anterior view) showing severe focal stenosis of the left M1 (arrow) and A1 segments. B: Left vertebral angiogram showing “beading” in multiple areas (arrows). C: Left internal carotid artery angiogram (same view as in A) after angioplasty of the M1 segment (arrow).

intracranial angioplasty for atherosclerotic disease, little has been reported about its use for vasculitis. One recent report documented angioplasty of intracranial vasculitis in 5 patients in the acute phase. Although technical success was achieved, all ultimately progressed to vessel occlusion and the authors advised against the use of angioplasty in the acute period because of the fragility of the vessel wall and susceptibility to dissection and occlusion [6].

We found the stenosis of neurosarcoid vasculitis to be firm, much like that found with atherosclerotic disease, requiring the use of noncompliant balloons. Successful angioplasty was performed with a good radiographic and clinical result. Whereas stent placement is a preferred modality by some [5] to treat intracranial vascular stenoses secondary to atherosclerotic disease, because of the presumed lower rate of restenosis compared with angioplasty alone, the use of a stent for intracranial vasculitis has not been reported. We chose angioplasty as a safer procedure in this situation where we felt that we could not predict the vessel response to endovascular manipulation. Repeat angiography with possible stent placement at a later date was considered.

4. Conclusions

Cerebral ischemia secondary to stenoses of the larger vessels at the base of the brain can occur in patients with neurosarcoid and this should be part of the differential diagnosis in patients with sarcoid who present with new

focal neurologic deficits. Emergent MRI/MRA can rapidly make the diagnosis. If symptoms worsen despite aggressive medical therapy, angiography and angioplasty should be strongly considered.

References

- [1] Brown MM, Thompson AJ, Wedzicha JA, et al. Sarcoidosis presenting with stroke. *Stroke* 1989;20:400-5.
- [2] Corse AM, Stern BJ. Neurosarcoidosis and stroke. *Stroke* 1990; 21(1):152-3.
- [3] Das SK, Sinha I, Kundu TN, et al. Two cases of neurosarcoidosis presenting as peripheral neuropathy and stroke in young. *J Assoc Phys India* 1998;46(5):479-81.
- [4] Duffey P, Bates D. Transient focal neurological deficit in sarcoidosis. *Sarcoidosis Vasc Diffuse Lung Dis* 1997;14(2):171-2.
- [5] Higashida RT, Meyers PM, Connors JJ, et al. Intracranial angioplasty and stenting for cerebral atherosclerosis: a position statement of the American Society of Interventional and Therapeutic Neuroradiology, Society of Interventional Radiology, and the American Society of Neuroradiology. *J Vasc Interv Radiol* 2005;16:1281-5.
- [6] McKenzie JD, Wallace RC, Dean BL, et al. Preliminary results of intracranial angioplasty for vascular stenosis caused by atherosclerosis and vasculitis. *AJNR Am J Neuroradiol* 1996;17:263-8.
- [7] Michotte A, Dequenne P, Jacobovitz D, et al. Focal neurological deficit with sudden onset as the first manifestation of sarcoidosis: a case report with MRI follow-up. *Eur Neurol* 1991;31(6):376-9.
- [8] Reske-Nielsen E, Harmsen A. Periangiitis and panangiitis as a manifestation of sarcoidosis of the brain: report of a case. *J Nerv Ment Dis* 1962;135:399-412.
- [9] Stern BJ, Krumholz A, Johns C, et al. Sarcoidosis and its neurological manifestations. *Arch Neurol* 1985;42:909-17.