

Aneurysm—Technique

Arterial suturing followed by clip reinforcement with circumferential wrapping for blister-like aneurysms of the internal carotid artery

Sung-Pil Joo, MD, Tae-Sun Kim, MD*, Kyung-Sub Moon, MD, Hyoung-Jun Kwak, MD, Jung-Kil Lee, MD, Jae-Hyoo Kim, MD, Soo-Han Kim, MD

Department of Neurosurgery, Chonnam National University Hospital and Medical School, Gwangju, Republic of Korea

Received 16 November 2005; accepted 19 January 2006

Abstract

Objective: Blister-like aneurysms of the internal carotid artery (ICA) are very fragile, thin-walled aneurysms. These lesions are susceptible to premature rupture intraoperatively. We describe two cases of successful arterial suturing of these blister-like aneurysms of the ICA, followed by a clip reinforcement technique and circumferential wrapping with a silastic sheet.

Methods: Two young men presented with a diffuse and dense subarachnoid hemorrhage (SAH) in the basal cistern. The initial angiogram obtained soon after the SAH showed a broad-based, small bulging appearance of the dorsal wall of the ICA. Intraoperatively, a very thin-walled aneurysm was identified on the C2 and C1 segment of the ICA. The aneurysms ruptured abruptly during surgical manipulation. After application of temporary clips, an aneurysmal tear of the ICA was repaired with 8-0 nylon. To prevent the regrowth of the aneurysm, clip reinforcement, by circumferential wrapping with a transparent silicone sheet, was added.

Results: The postoperative clinical course was uneventful, although one patient showed transient right hemiparesis due to cerebral vasospasm. Angiographic studies performed postoperatively showed complete obliteration of the aneurysm as well as a patent ICA lumen in one case and total occlusion of the ICA in the other case. Both patients were discharged with no neurological deficits.

Conclusion: This technique can be a useful treatment option for these fragile aneurysms in cases where other options, such as direct clips or encircling clips, may be impossible.

© 2006 Elsevier Inc. All rights reserved.

Keywords:

Blister-like aneurysm; Suturing; Silicone sheet; Wrapping; Internal carotid artery

1. Introduction

Aneurysms arising from the dorsal wall of the ICA, known as blister-like aneurysms, have been reported to have extremely thin, fragile walls with a marked tendency to rupture intraoperatively [1,2,5,7,10,11,14,16]. These lesions rupture easily with surgical manipulation, resulting in an arterial wall defect in the ICA. In such situations [1,5,7], it is very difficult to reconstruct the ICA while preserving patency of the parent artery. Recently, we had an intraoperative arterial tear at the base of a blister-like

aneurysm. We report two cases of a useful technique where direct suture of the arterial tear on the blister-like aneurysm, followed by a clip reinforcement technique and circumferential wrapping with silastic sheet, was successfully used.

2. Case reports

2.1. Case 1

2.1.1. History and examination

This 30-year-old man had a sudden onset of headache and vomiting. He was initially transported to a local hospital before he was referred to our hospital for further management of SAH. On admission, his neurological symptoms were unremarkable except for drowsiness. His condition was graded as Hunt and Hess grade III.

Abbreviations: ACA, anterior cerebral artery; BBA, blood blister-like aneurysm; ICA, internal carotid artery; MCA, middle cerebral artery; Pcom, posterior communicating artery; SAH, subarachnoid hemorrhage.

* Corresponding author. Tel.: +82 62 220 6607; fax: +82 62 224 9865.

E-mail address: taesun@yahoo.co.kr (T.-S. Kim).

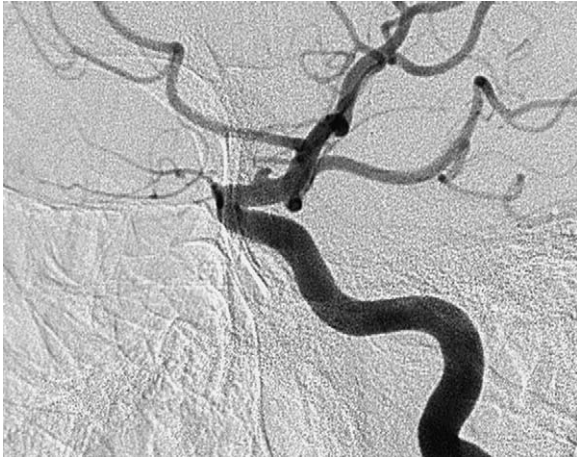

Fig. 1. Cerebral angiographic studies demonstrated a broad-based faint bulge on the anteromedial wall of the left ICA.

Computerized tomography showed a dense and diffuse SAH at the basal cistern and sylvian fissure that was slightly more prominent on the left side. Cerebral angiographic studies demonstrated a broad-based faint bulge on the anteromedial wall of the left ICA (Fig. 1); a blister-like aneurysm was suspected.

2.1.2. Operation

Two days after onset of symptoms, surgery was performed. The cervical ICA was exposed for proximal control in case of premature rupture. After a left orbitopterional craniotomy, the sylvian fissure was opened widely, and the left frontal lobe was carefully elevated to expose the left ICA. The left ICA was slightly elongated and C-shaped in form. The sclerotic anteromedial wall was covered with a tough and fibrinous clot. The neck of the aneurysm was exposed on the C2 segment of the ICA. It had no relation to any of the carotid branches and its wall seemed to be very thin (Fig. 2A). When the removal of the local blood clot and aneurysmal neck dissection was done, massive arterial bleeding occurred. The apparent aneurysmal sac was not seen; therefore, temporary clips were applied to the ICA to obstruct the ruptured portion of the artery. A curved Sugita clip was applied parallel to the arterial wall and covered with a beam sheet so that the clip blade could catch the arterial wall below the lesion. Microdoppler was applied to confirm patency of distal ICA; unfortunately, blood flow was not detected. Several attempts to apply various clips failed to close the aneurysmal tear. We then tried to repair the wall with 8-0 nylon sutures (Fig. 2B); although the suture procedure was difficult, we succeeded in repairing the torn arterial vessel wall (Fig. 2C). The collapsed vessel then returned to a tubular form suitable for the application of combined wrapping and clipping. Finally, the sutured vessel wall was wrapped with a transparent silicone sheet (Medical grade silicone sheet, size 20-05, Bioplexus Corporation, Los Angeles, CA), and a curved Sugita clip was applied parallel

to the arterial wall to prevent the regrowth of the aneurysm (Fig. 2D). Operative procedures were summarized in Fig. 2E. The clipped wall was covered with a Bemsheet and fibrin glue. The total time for the temporary clipping was approximately 20 minutes.

2.1.3. Postoperative course

The postoperative course was uneventful. However, the patient deteriorated on postoperative day 4. Angiography obtained 5 days after surgery demonstrated severe vasospasm of the left ACA and MCA (Fig. 3A). Angioplasty with intra-arterial papaverine was performed, and the severe vasospasm improved (Fig. 3B). Repeat CT scans revealed cerebral infarction of the left frontal and temporal lobe. The patient recovered gradually and was discharged with a mild hemiparesis on the right side (grade IV). Follow-up angiography obtained 9 months later demonstrated total occlusion of left ICA just distal to ophthalmic artery (Fig. 4A and B). However, his neurological symptoms showed no change.

2.2. Case 2

2.2.1. History and examination

This 33-year-old man developed a sudden onset of headache and vomiting after drinking alcohol. On the following day, he was admitted to our hospital with mild drowsiness but no other neurological deficits. There was no specific medical problem except for hypertension. Computerized tomography revealed a Fisher grade III SAH at the basal cistern and sylvian fissure that was slightly more prominent on the right side. Initial CT angiographic studies were negative. Angiography demonstrated a supraclinoid ICA aneurysm just proximal to the ICA bifurcation.

2.2.2. Operation

An emergent right pterional craniotomy was performed after exposure of the right cervical ICA, and the right frontal lobe was carefully elevated. A 3-mm-sized small blister-like aneurysm was encountered at the anteromedial wall of the C1 portion of the ICA. After temporary occlusion of the cervical ICA, we initially tried to clip the aneurysm with a Bemsheet because it seemed to have a neck, but clip slippage resulted in massive arterial bleeding. Under temporary trapping of the ICA and Pcom, a ruptured aneurysmal neck was successfully sutured with 8-0 nylon sutures. Three stitches were sufficient to obliterate the arterial wall defect; the sutured vessel wall was then wrapped with a silicone sheet, then a curved Sugita clip was applied parallel to the arterial. Pentothal sodium and mannitol were infused during the procedure to reduce the risk of ischemic insults. The total time for temporary clipping was approximately 18 minutes.

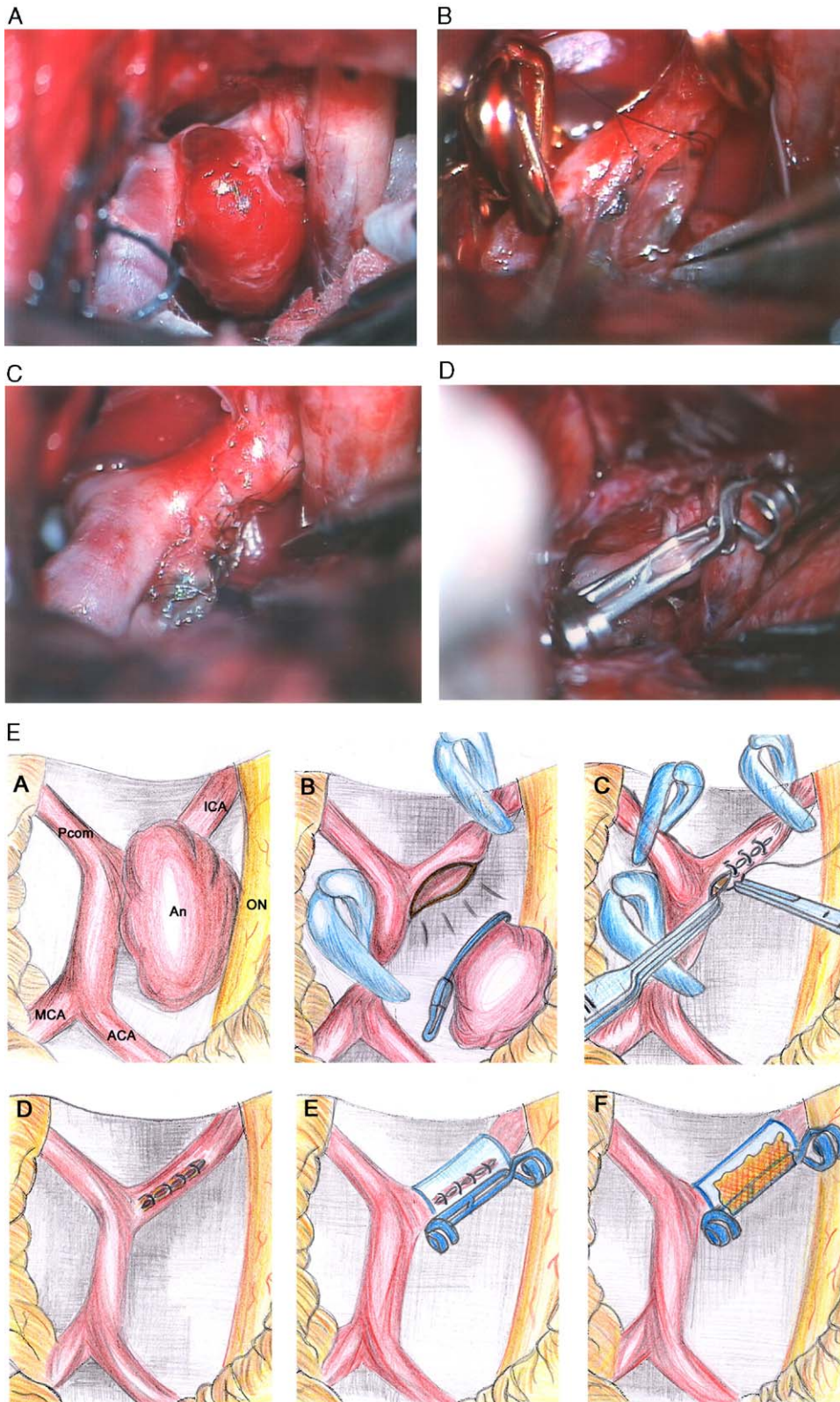
2.2.3. Postoperative Course

The patient's clinical condition gradually improved postoperatively. Angiography on the 30th day after surgery

demonstrated total obliteration of the aneurysm with a patency of the arterial lumen to its normal configuration. The patient was discharged without any neurological deficits.

3. Discussion

Aneurysms arising from the dorsal wall of the ICA are quite rare; they are reported to comprise 0.3% to 1% of all intracranial aneurysms or 0.9% to 6.5% of aneurysms of the



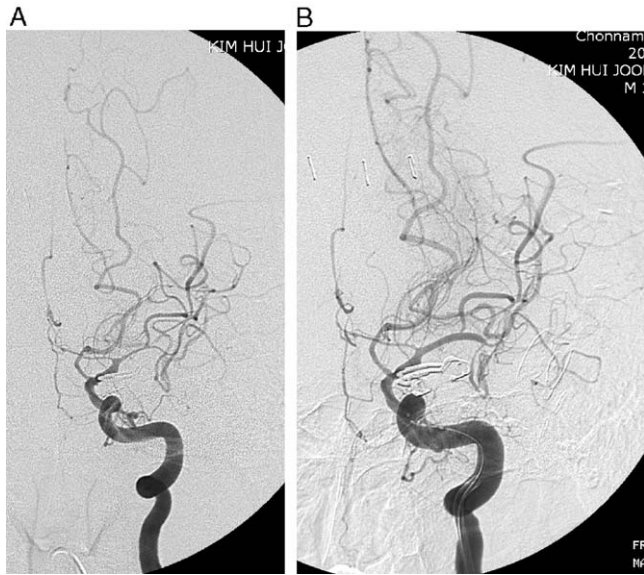


Fig. 3. A: Postoperative left carotid angiogram obtained on the fifth day postsurgery, anteroposterior view, and demonstrating severe vasospasm in the ACA and MCA. B: Vasospasm was improved after intravenous papaverine injection in MCA.

ICA [15]. These aneurysms have been classified into two groups according to shape: one is a small hemispherical bulge that is called “blood blister-like aneurysm” (BBA) [1] and the other is a saccular type aneurysm. A BBA is also called a semifusiform aneurysm [7,11] or a blister-like aneurysm [5]. Blister-like aneurysms of the ICA have unique characteristics: (1) a high risk of intraoperative rupture; (2) the wall of the aneurysm is too fragile to clip while preserving the parent artery; and (3) morphologically, it is small with a broad base and is thus difficult to place coils in the cavity [13]. In previous reports, several groups have reported various surgical techniques that have consisted of parallel clip placement, wrapping, and the combination of both techniques as well as trapping with or without bypass surgery [2,6,8,11,14,17]. These lesions are easy to rupture intraoperatively, resulting in the formation of small to large defects in the ICA. In such a situation, it is very difficult to reconstruct the ICA while preserving patency of the parent artery. Suturing or wrapping with hemostatic clips has been used to repair arterial tears at the base of an aneurysm [4,5,12,16]. Several studies have been reported that describe successful arterial repair by suturing or vessel wrapping [8,9,15]. Okuchi et al [10] reported the case of a blister-like aneurysm in which the laceration of the arterial wall was repaired with nylon

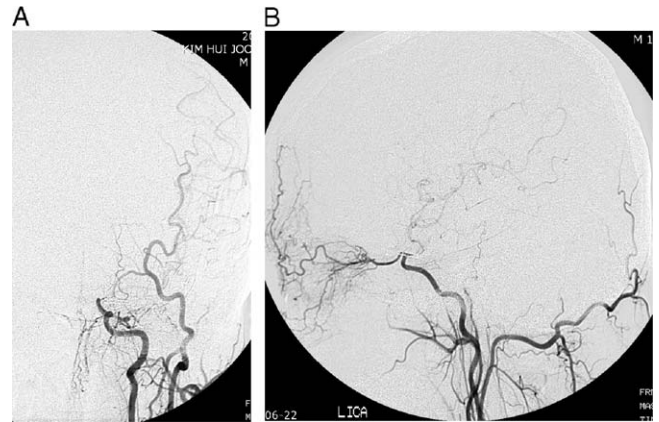


Fig. 4. A and B: Follow-up angiography obtained 9 months later demonstrating the total occlusion of the left ICA just distal to ophthalmic artery.

thread. However, the occlusion time for repair was too long (50 minutes) and resulted in a massive cerebral infarction. The repair of the arterial tear in the ICA can be very difficult because the operation field is deep and narrow at the acute stage. However, in our cases, successful arterial suture was done. In this situation, we placed three or four 8-0 nylon microsuture stitches in the ICA to reform the parent artery rather than completely suture the tear. It is not necessary to obliterate the arterial wall defect completely. Three stitches were sufficient to obliterate the arterial wall defect. Therefore, temporary occlusion time could be shortened considerably. The total time for temporary trapping was approximately 20 minutes. We thought that a successful outcome could be achieved because the temporary trapping time was short and the arterial tear small in our cases. If the arterial perforation is large, it will take a longer time to repair, and the outcome is less certain. Yanaka et al [14] has advocated for a combined suture and encircling clip method that might result in a shorter occlusion time than suture alone, thus avoiding potentially disastrous ischemic complications.

Many reports have described the successful use of wrapping materials such as gauze, muscle, muscle fascia, cellulose fabric, and Gore-Tex (WL Gore and Associates, Inc, Flagstaff, Ariz) [7]. Abe et al [1] reported two cases in which wrapping with a strip of gauze could not prevent the growth of aneurysms. It appeared that wrapping with a strip of gauze was not sufficient to reinforce the very fragile aneurysm wall. Also, it is often difficult to select the most appropriate wrapping material and to cover the entire lesion with that wrapping material. The primary advantage of the silicone sheet is that it is thin, flexible, and

Fig. 2. A: Intraoperative photograph showing an aneurysm covered with a tough and fibrinous blood clot. B: Intraoperative photograph demonstrating direct repair of the arterial wall with 8-0 nylon after temporary trapping. C: Successful arterial suturing of the torn arterial vessel wall. The collapsed vessel returned to a tubular form suitable for application of combined wrapping and clipping. D: Intraoperative photograph obtained after the sutured vessel wall was reinforced with application of combined wrapping and clipping. E: Schematic drawings of suturing and clipping procedure. A, An aneurysm is seen on the anteromedial wall of the ICA. B, Aneurysm is separated from its base. C, Three or four 8-0 nylon suture stitches are placed on the tear. D, Completion of repairing the torn vessel wall. E, The sutured vessel wall is wrapped with a transparent silicone sheet and two angled clips are catching the ICA wall beyond the silicone sheet. F, Finally, the clipped wall is covered with a Bemsheet and fibrin glue. An, aneurysm; ON, optic nerve.

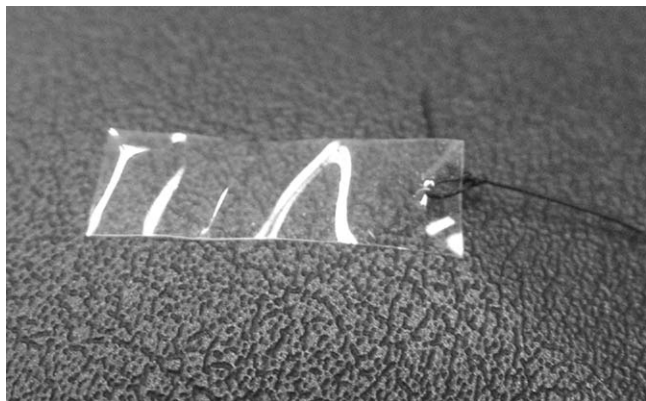


Fig. 5. Photograph of the silicone sheet (Medical grade silicone sheet, size 20-05, Bioplexus Corporation). Because the sheet is thin, flexible, and transparent, it can easily be tailored to incorporate perforating branches and other arteries.

transparent (Fig. 5). Therefore, branches around the aneurysm encircled with the sling can be seen. A secondary advantage is that the sling can be easily tailored to incorporate perforating branches and other arteries; these factors make it a useful alternative tool for arterial repair. Disadvantages of clip reinforcement with the wrapping sheet are as follows: (1) the possibility of narrowing or occluding the parent artery; (2) need for circumferential dissection of the entire aneurysm before passage of the sling; and (3) formation of foreign-body granuloma [3]. We assume that the cause of the occlusion of the ICA in case 1 was from the formation of a granuloma from the Bemsheet and fibrin glue.

4. Conclusion

We have successfully used a technique of direct suture of the blister-like aneurysm in the ICA followed by clip reinforcement and circumferential wrapping. This method can be a useful treatment option for these fragile aneurysms in cases where other options, such as direct clips and encircling clips (which are not generally available in modern aneurysm clip trays), may be impossible. Aneurysmal rupture at the neck of the vessel does occur occasionally and can be treated using the described suture and clip reinforcement strategy. Long-term follow-up with cerebral angiography is mandatory because the clip reinforcement technique can cause stenosis of the parent artery or a remnant aneurysm may be present; these findings should be ruled out by angiography before discharge.

References

- [1] Abe M, Tabuchi K, Yokoyama H, Uchino A. Blood blisterlike aneurysms of the internal carotid artery. *J Neurosurg* 1998;89:419–24.
- [2] Cantore GP, Santoro A. Treatment of aneurysms unsuitable for clipping or endovascular therapy. *J Neurosurg Sci* 1998;42:71–5.

- [3] Haisa T, Matsumiya K, Yoshimasu N, Kuribayashi N. Foreign-body granuloma as a complication of wrapping and coating an intracranial aneurysm. Case report. *J Neurosurg* 1990;72:292–4.
- [4] Heifetz MD. A new intracranial aneurysm clip. *J Neurosurg* 1969;30:753.
- [5] Ishikawa T, Nakamura N, Houkin K, Nomura M. Pathological consideration of a “blister-like” aneurysm at the superior wall of the internal carotid artery: case report. *Neurosurgery* 1997;40:403–5 [discussion 405–6].
- [6] Miyazawa N, Nukui H, Mitsuka S, Hosaka T, Kakizawa T, Nishigaya K, Horikoshi T, Yagi S, Sugita M. Treatment of intradural paraclinoidal aneurysms. *Neurol Med Chir (Tokyo)* 1999;39:727–32 [discussion 724–32].
- [7] Nakagawa F, Kobayashi S, Takemae T, Sugita K. Aneurysms protruding from the dorsal wall of the internal carotid artery. *J Neurosurg* 1986;65:303–8.
- [8] Ogawa A, Suzuki M, Ogasawara K. Aneurysms at nonbranching sites in the supraclinoid portion of the internal carotid artery: internal carotid artery trunk aneurysms. *Neurosurgery* 2000;47:578–83 [discussion 576–83].
- [9] Ogilvy CS. Repair of an arterial perforation of the internal carotid artery using Hemashield wrapping with aneurysm clip reinforcement: technical note. *Neurosurgery* 1997;40:1312–4.
- [10] Okuchi K, Fujioka M, Maeda Y, Nonaka M, Sakaki T. Surgical treatment of internal carotid artery anterior wall aneurysm with extravasation during angiography—case report. *Neurol Med Chir (Tokyo)* 1999;39:40–4.
- [11] Shigeta H, Kyoshima K, Nakagawa F, Kobayashi S. Dorsal internal carotid artery aneurysms with special reference to angiographic presentation and surgical management. *Acta Neurochir (Wien)* 1992;119:42–8.
- [12] Sundt Jr TM, Nofzinger JD. Clip-grafts for aneurysm and small vessel surgery. 1. Repair of segmental defects with clip-grafts; laboratory studies and clinical correlations. 2. Clinical application of clip-grafts to aneurysms; technical considerations. *J Neurosurg* 1967;27:477–89.
- [13] Tanoue S, Kiyosue H, Matsumoto S, Yamashita M, Nagatomi H, Mori H. Ruptured “blisterlike” aneurysm with a pseudoaneurysm formation requiring delayed intervention with endovascular coil embolization. Case report. *J Neurosurg* 2004;101:159–62.
- [14] Yanaka K, Meguro K, Nose T. Repair of a tear at the base of a blister-like aneurysm with suturing and an encircling clip: technical note. *Neurosurgery* 2002;50:218–21.
- [15] Yasargil MG. *Microneurosurgery: clinical consideration, surgery of the intracranial aneurysm s result*, vol. II. Stuttgart: Georg Thieme; 1984; 58–9.
- [16] Yokoo A, Sugita K, Kobayashi S, Matsuo K. A simple hemostatic method using a metal shield for injury of a major cerebral artery. *J Neurosurg* 1982;57:323–7.
- [17] Yoshimoto Y, Ochiai C, Nagai M. Cerebral aneurysms unrelated to arterial bifurcations. *Acta Neurochir (Wien)* 1996;138:958–63 [discussion 954–63].

Commentary

The authors describe the technical aspects of a surgical treatment of ruptured, blister-like aneurysms of the ICA in two cases. Both aneurysms inadvertently ruptured while being exposed. However, the surgeon was able to control bleeding as well as obliterate the aneurysms by means of a combination of arterial suture, wrapping, and clip placement. Although a delayed occlusion of the affected ICA