

COATING THE WALL OF AN INJURED INTRACRANIAL CAROTID ARTERY DURING TUMOR REMOVAL WITH N-BUTYL-2-CYANOACRYLATE: TECHNICAL CASE REPORT

Flavio Requejo, M.D.

Department of Neuroradiology,
University Hospital Freiburg,
Freiburg, Germany

Martin Schumacher, M.D.

Department of Neuroradiology,
University Hospital Freiburg,
Freiburg, Germany

Vera van Velthoven, M.D.

Department of Neurosurgery,
University Hospital Freiburg,
Freiburg, Germany

Reprint requests:

Flavio Requejo, M.D.,
Department of Neuroradiology,
Freiburg University Neurocenter,
Breisacher Straße 64,
79106 Freiburg, Germany.
Email: frequejo@intramed.net

Received, January 5, 2006.

Accepted, June 6, 2006.

OBJECTIVE: Carotid artery injury close to the clinoid process is difficult to repair, and is even more so when the vessel is firmly attached to a calcified tumor. We treated a patient with an intraoperative carotid lesion by coating the vessel wall with *n*-butyl-2-cyanoacrylate (NBCA).

CLINICAL PRESENTATION: A 7-year-old boy was referred to our clinic with a 3-month history of somnolence, apathy, and headache. Neurological examination revealed bitemporal hemianopsia. The cranial magnetic resonance imaging and computed tomographic scans showed a sellar and suprasellar calcified mass with heterogeneous contrast enhancement, a cyst component in the upper part of the tumor displaced upward and back from the mesencephalic and diencephalic structures.

INTERVENTION: The patient underwent a pterional craniotomy. Using a microsurgical technique, the suprasellar part of the craniopharyngioma was removed. In an attempt to dissect the calcified mass from the carotid artery on the right side, the vessel was unintentionally injured, followed by severe bleeding. Temporary occlusion and suturing of the vessel was impossible because of the overlying hard mass. To avoid a permanent occlusion, we decided to coat the injured artery wall with 100% NBCA. For this, 0.5 ml of NBCA was distributed on the surface of the injured segment and surrounding subarachnoid space by injection through a needle. An excellent hemostasis could be obtained immediately after coating. The patient woke up with no new neurological deficits. A digital cerebral angiogram obtained a few days after the procedure did not show vasospasm, stenosis, or pseudoaneurysm in the supraclinoidal segment of the carotid artery. A magnetic resonance angiogram obtained 3 years later showed a normal shape of the internal carotid artery and a stable residual tumor without inflammatory signs. The child is now attending school and is under hormonal therapy.

CONCLUSION: For hemostatic purposes, the technique of coating an injured arterial wall with NBCA may be useful in cases in which a microsuture is impossible and a permanent artery occlusion is unwanted because of a risk of an ischemic stroke. It could serve as a transitory measure until a microsurgical bypass or the balloon test occlusion tolerance allow the trapping of the affected artery.

KEY WORDS: Carotid artery, Coating, Craniopharyngioma, *n*-butyl-2-cyanoacrylate

Neurosurgery 59(ONS Suppl 4):ONS-484–ONS-485, 2006

DOI: 10.1227/01.NEU.0000232769.86686.96

Intraoperative bleeding owing to an accidental cut of an artery at the cranial base is usually controlled with microsutures or permanent vessel occlusion. This last option carries a risk of ischemic stroke when there is no previous knowledge of the cerebral interhemispheric circulation of the patient (10). We present a case of intraoperative carotid artery injury during tumor removal that was managed by application of *n*-butyl-2-cyanoacrylate (NBCA) on

the injured vessel wall in the surrounding subarachnoid space.

Illustrative Case

A 7-year-old boy presented with a 3-month history of apathy, somnolence, and headache. Neurological examination revealed a bitemporal hemianopsia. Computed tomographic (CT) and magnetic resonance imaging (MRI) scans showed a sellar and suprasellar cal-

cified mass with a cyst displacing the mesencephalic and diencephalic structures (Fig. 1, A–C).

Surgery

After a pterional craniotomy, the tumor was removed microsurgically in its suprasellar portion. In an attempt to separate the tumor from the carotid artery on the right side, the vessel was partially injured. Because of the tightly adherent and overlying calcified mass, it was impossible to dissect the vessel and perform a microsurgical suture. To avoid a permanent vessel occlusion with subsequent risk of an ischemic stroke, we decided to coat the arterial wall by injecting NBCA. The neighboring tissue, including the optic chiasm and nerve, were protected by cotton. The bleeding was controlled by temporal tamponade with cottonoid and suction over the carotid artery encased by the tumor. Meanwhile, 0.5 ml of glue in a pure form was injected through a long 20-gauge needle over the injured wall and partially into the surrounding subarachnoid space. An excellent hemostasis was achieved immediately after hardening of the NBCA. The patient woke up with no new neurological deficits.

The day after the procedure, a CT scan showed the NBCA over the clinoid process and the rest of the partially removed calcified neoplasm. Both the cyanoacrylate and the calcium had the same appearance on the CT scan (Fig. 2, A and B). A digital cerebral angiogram obtained 1 week after the operation did not show vasospasm, stenosis, or pseudoaneurysm in the

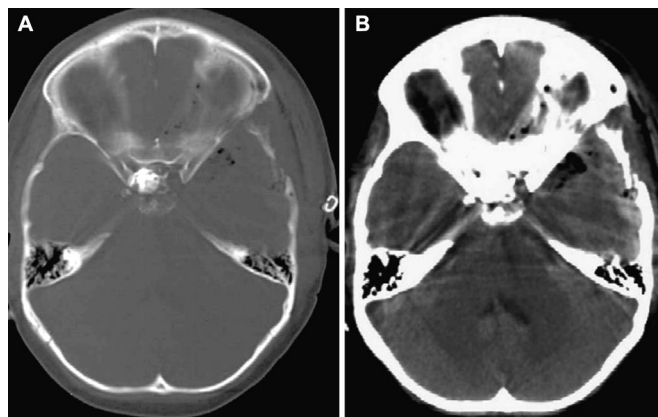


FIGURE 2. Axial CT scans in bone (A) and the parenchymal (B) window demonstrating the NBCA over the clinoid process and the calcified mass. Compare with Figure 1C.

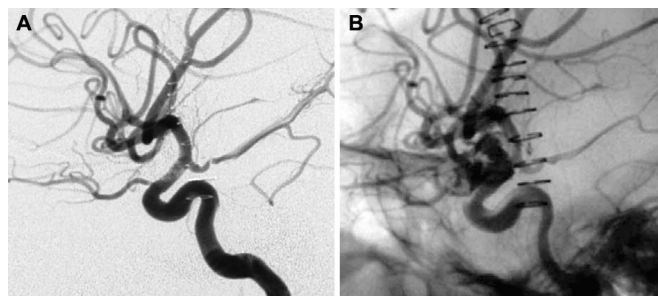


FIGURE 3. A, digital subtracted angiogram obtained after surgery and vessel repair showing a normal intracranial carotid artery. B, non-subtracted angiogram showing tumor calcification and NBCA over the carotid artery.

supraclinoid carotid artery (Fig. 3, A and B). The histopathology of the tumor revealed a craniopharyngioma.

During the follow-up period, the patient persisted with some visual deficit. He is currently receiving hormonal therapy and lives a normal life. The last magnetic resonance angiogram obtained 3 years after the operation did not show any sign of alteration in the carotid artery wall or lumen. MRI scans obtained at the same time showed a residual, but stable, tumor (Figs. 4 and 5).

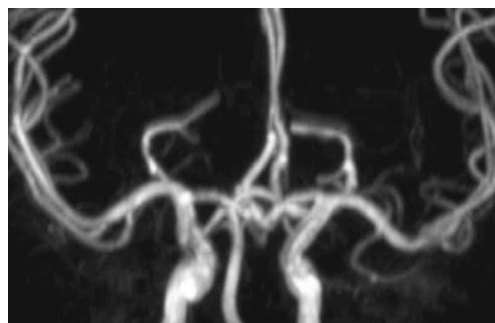


FIGURE 4. Magnetic resonance angiogram obtained 3 years after the procedure.

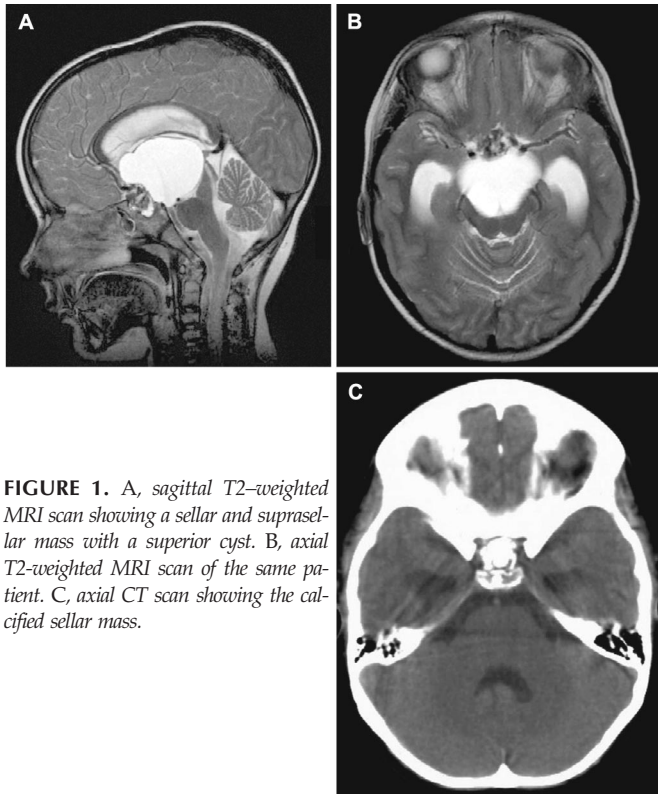


FIGURE 1. A, sagittal T2-weighted MRI scan showing a sellar and suprasellar mass with a superior cyst. B, axial T2-weighted MRI scan of the same patient. C, axial CT scan showing the calcified sellar mass.

DISCUSSION

NBCA is a vinyl monomer of alkyl 2-cyanoacrylate and it polymerizes on contact with ionic solutions (blood, contrast medium). The polymerization (hardening) is almost immediate when used in its pure form or can be prolonged by a few seconds with the addition of ethiodized oil or iophendylate (4, 23).

NBCA is used extensively in the treatment of the cerebral and spinal arteriovenous malformations and dural arteriovenous fistulas because it is the only embolizing agent to give permanent vessel occlusion (19, 22, 26). The extravascular use of NBCA is gaining acceptance for the treatment of hypervascularized tumors of the head and the neck. Percutaneous use of this substance makes surgery easier and bloodless (5). The hemostatic property of this agent has been described in oral and vascular surgery (2, 12, 20). This substance is also used widely for endoscopic sclerotherapy of esophageal and gastric varices and for the sealing of enterocutaneous and gastrointestinal fistulas (15–25).

For the central nervous system, the cyanoacrylates were used extravascularly in the past to coat cerebral unclippable aneurysms to prevent rebleeding (6–8). To the best of our knowledge, no deleterious effects directly attributable to this substance have been reported during the follow-up period (16–27), even if, in animal models, the cyanoacrylates may cause an inflammatory reaction and damage to the vessel wall (6, 8, 9, 13, 16, 17, 18, 19, 24, 26).

In our patient, the encasement of the carotid artery in the calcified tumor and the proximity to the clinoid process made the application of temporary clips and microsurgical suture of the vessel wall impossible. The second option we had to stop the bleeding was the permanent occlusion of the artery, but we had no previous knowledge about the cerebral collateral circulation of the patient. It was decided to manage the arterial injury by coating the vessel wall with NBCA. The effective application of the cyanoacrylate over the arterial wall requires the stop of the bleeding for a few seconds. This can be achieved by compressing the tumor over the vessel or by compressing the vessel itself. In contact with the residual blood on the arterial wall, 100% NBCA hardens immediately, producing an efficient hemostasis.

This technique is applicable in cases in which the arterial wall is partially cut, but would be not as effective in a completely lacerated vessel wall. The calcified tumor was helpful to keep the NBCA in place.

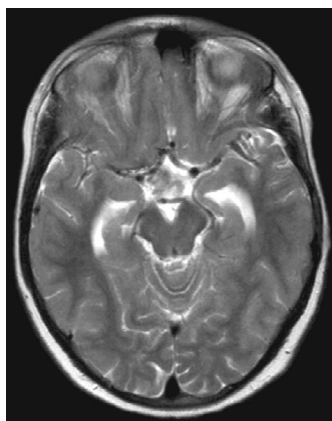


FIGURE 5. Axial T2-weighted MRI scan showing a residual tumor without inflammatory signs.

During 3 years of follow-up for our patient, the glue produced neither any change in the carotid artery nor any inflammatory reaction of the brain or subarachnoid space. Even if long-term treatment was achieved in this case, we do not recommend this procedure as a permanent measure. It was performed to stop life-threatening intraoperative bleeding. Trapping of the affected segment of the artery can be performed in patients with good cerebral interhemispheric circulation, as certified by a balloon test occlusion. In patients with poor collaterals, bypass microsurgery is mandatory before the sacrifice of the injured vessel (14–21).

Taking our experience into account, previous knowledge of the cerebral circulation is desirable in patients with a calcified sellar mass involving the carotid artery. Preparation for a possible microsurgical bypass is strongly recommended in cases with balloon test occlusion intolerance. Although the extravascular sealant properties of the cyanoacrylates, when applied over arteries, is well known in vascular surgery and animal experiments, more studies are needed to evaluate the long-term performance of these agents in injured intracranial arteries (1, 3, 11, 12, 20). A potential disadvantage of this procedure is the hardened NBCA mass that will make it difficult for an eventual reintervention in the site where it was applied (Fig 2, A and B).

CONCLUSION

The application of NBCA over an intraoperatively injured or ruptured brain vessel may be useful in cases in which microsuture is impossible and a permanent occlusion carries a risk of an ischemic stroke. This procedure is recommended as a transitory solution to stop life-threatening intraoperative bleeding. Trapping of the affected segment of the artery is an effective method in patients who previously tolerated a balloon test occlusion. Bypass surgery is mandatory in those cases with poor cerebral interhemispheric circulation.

REFERENCES

1. Ang E, Tan K, Tan LH, Ng R, Song I: 2-octylcyanoacrylate-assisted microvascular anastomosis: Comparison with a conventional suture technique in rat femoral arteries. *J Reconstr Microsurg* 17:193–201, 2001.
2. Al-Belasy F, Armer M: Hemostatic effect of n-butyl-2-cyanoacrylate (histoacryl) glue in warfarin-treated patients undergoing oral surgery. *J Oral Maxillofac Surg* 2003 Dec;61:1405–1409, 1999.
3. Bastiaanse J, Borst C, van der Helm Y, Loo K, Grundeman P: Arteriotomy closure by glued patch in the porcine carotid artery. *Ann Thorac Surg* 70:1384–1388, 2000.
4. Brothers M, Kaufmann J, Fox A, Deveikis JP: n-butyl-2-cyanoacrylate substitute for IBCA in interventional neuroradiology: Histopathologic and polymerization time studies. *AJNR Am J Neuroradiol* 10:777–786, 1989.
5. Chaloupka J, Mangla S, Huddle D, Roth T, Mitra S, Ross D, Sasaki S: Evolving experience with direct puncture therapeutic embolization for adjunctive and palliative management of head and neck neoplasms. *Laryngoscope* 109:1864–1872, 1999.
6. Coe J, Boundurant C: Late thrombosis following the use of autogenous fascia and cyanoacrylate (Eastman 910 monomer) for the wrapping of an intracranial aneurysm. *J Neurosurg* 21:884–886, 1964.

7. Cossu M, Pau A, Turtas S, Viola C, Viale G: Subsequent bleeding from ruptured intracranial aneurysms treated by wrapping or coating: A review of the long-term results in 47 cases. *Neurosurgery* 32:344–347, 1993.
8. Dutton J: Acrylic investment of intracranial aneurysm. A report of 12 years' experience. *J Neurosurg* 31:652–657, 1969.
9. Ebina K, Iwabuchi T, Suzuki S: A clinico-experimental study on various wrapping materials of cerebral aneurysms. *Acta Neurochir (Wien)* 72:61–71, 1984.
10. Eckard D, Purdy P, Bonte F: Temporary balloon occlusion of the carotid artery combined with brain blood flow imaging as a test to predict tolerance previous to permanent carotid sacrifice. *AJNR Am J Neuroradiol* 13:1565–1569, 1992.
11. Ellman P, Brett Reece T, Maxey TS, Tache-Leon C, Taylor JL, Spinosa DJ, Pineros-Fernandez AC, Rodeheaver GT, Kern JA: Evaluation of an absorbable cyanoacrylate adhesive as a suture line sealant. *J Surg Res* 125:161–167, 2005.
12. Goossens D, Brutel de la Riviere A, Ernst S, Vermeulen F: Reoperative aortic root surgery late after use of histo-acryl. *Eur J Cardiothorac Surg* 11:194–195, 1997.
13. Kaplan M, Bozkurt S, Kut MS, Kullu S, Demirtas M: Histopathological effects of ethyl 2-cyanoacrylate tissue adhesive following surgical application: an experimental study. *Eur J Cardiothorac Surg* 25:167–172, 2004.
14. Linskey M, Jungries C, Yonas H, et al: Stroke risk after abrupt internal carotid artery sacrifice: Accuracy of preoperative assessment with balloon test occlusion and stable Xenon-enhanced CT. *AJNR Am J Neuroradiol* 15:829–843, 1994.
15. Lux G, Retterspitz M, Stabenow-Lohbauer U, Langer M, Altendorf-Hofmann A, Bozkurt T: Treatment of bleeding esophageal varices with cyanoacrylate and polidocanol alone: Results of a prospective study in an unselected group of patients with cirrhosis of the liver. *Endoscopy* 29:241–246, 1997.
16. Ogilvy C, Poletti C: Clipping of an aneurysm 20 years after encasement with methacrylate. Case report. *J Neurosurg* 75:305–307, 1991.
17. Rosengren A, Danielsen N, Bjursten L: Inflammatory reaction dependence on implant localization in rat soft tissue models. *Biomaterials* 18:979–987, 1997.
18. Sadato A, Numaguchi Y, Taki W, Iwata H, Yamashita K: Nonadhesive liquid embolic agent: Role of its components in histologic changes in embolized arteries. *Acad Radiol* 5:198–206, 1998.
19. Sadato A, Wakhloo AK, Hopkins LN: Effects of a mixture of a low concentration of n-butyl-cyanoacrylate and ethiodol on tissue reactions and the permanence of arterial occlusion after embolization. *Neurosurgery* 47:1197–1205, 2000.
20. Schenk W 3rd, Spotnitz W, Burks S, Lin P, Bush R, Lumsden A: Absorbable cyanoacrylate as a vascular hemostatic sealant: A preliminary trial. *Am Surg* 71:658–661, 2005.
21. Sekhar LN, Bucur SD, Bank WO, Wright DC: Venous and arterial bypass grafts for difficult tumors, aneurysms and occlusive vascular lesions: Evolution of operative management and improvement results. *Neurosurgery* 44:1207–1224, 1999.
22. Söderman M, Andersson T, Karlsson B, Wallace M, Edner G: Management of patients with brain arteriovenous malformations. *Eur J Radiol* 46:195–205, 2003.
23. Spiegel SM, Viñuela F, Goldwasser JM, Fox AJ, Pelz DM: Adjusting the polymerization time of isobutyl-2-cyanoacrylate. *AJNR Am J Neuroradiol* 7:109–112, 1986.
24. Stöwsand D, Buhl K: Early and late results of coating intracranial aneurysms with biobond [in German]. *Acta Neurochir (Wien)* 32:73–82, 1975.
25. Wu C, Yeh H, Chen G: Pharmacological efficacy in gastric variceal rebleeding and survival: Including multivariate analysis. *J Clin Gastroenterol* 35:127–132, 2002.
26. Wikholm G: Occlusion of cerebral arteriovenous malformations with N-butyl-cyanoacrylate is permanent. *AJNR Am J Neuroradiol* 16:479–482, 1995.
27. Yashon D, Jane J, Gordon M, Hubbard J, Sugar O: Effects of methyl-2-cyanoacrylate adhesives on somatic vessels and the central nervous system of animals. *J Neurosurg* 24:883–888, 1966.

COMMENTS

The authors report their experience with n-butylcyanoacrylate (NBCA), which they successfully applied periadventitially to a lacerated and diseased internal carotid artery wall. This compound has been studied and used widely in alternate applications. Although the use of NBCA may be an adjunct in certain adverse open surgical situations, we recommend primary repair of a lacerated vessel whenever possible.

Robert F. Spetzler
Vini G. Khurana
Phoenix, Arizona

The authors provide an interesting description of the use of cyanoacrylate. They reference the literature regarding the dangers of older glues in arterial repair, given the inflammatory action that can occur. Although there is no way to know the type of inflammation that the NBCA might incite in the long term, I think the authors' caution in using this type of strategy as a long-term fix is a good one. This is particularly true given the high flow and shear rates associated with the internal carotid artery as it exits the cranial base. Every surgeon has a mental list of plans for catastrophe management in the setting of working around large intracranial vessels. The authors provide us with one more potential solution to the terrible problem of an intracranial arterial tear or laceration.

Christopher S. Ogilvy
Boston, Massachusetts