

# Successful Recanalization by In-Stent Percutaneous Transluminal Angioplasty With Distal Protection for Acute Carotid Stent Thrombosis

## —Case Report—

Osamu MASUO, Tomoaki TERADA, Yoshikazu MATSUDA, Mitsuhiro OGURA, Tomoyuki TSUMOTO, Hiroo YAMAGA, and Toru ITAKURA

Department of Neurological Surgery, Wakayama Medical University, Wakayama

### Abstract

A 71-year-old male presented with severe left cervical internal carotid artery stenosis manifesting as repeated transient ischemic attacks consisting of right hemiparesis and motor aphasia. Carotid artery stenting (CAS) under distal protection was performed to prevent further ischemic events. This procedure was uneventful. However, the patient exhibited progressive right hemiparesis and motor aphasia 3 days after CAS. Emergent angiography revealed carotid artery occlusion due to in-stent thrombosis. In-stent percutaneous transluminal angioplasty (PTA) was performed under distal protection. The carotid artery was recanalized with small residual thrombus. The neurological deficits almost completely disappeared after PTA. Follow-up angiography 9 months after stenting showed restenosis but no in-stent thrombosis. Carotid thrombosis after CAS can be resolved by in-stent PTA under distal protection and subsequent treatment with antithrombotic agents.

Key words: carotid artery stenosis, carotid artery stenting, acute thrombosis, in-stent percutaneous transluminal angioplasty, recanalization

### Introduction

Carotid artery stenting (CAS) shows potential as an effective and safe treatment to alleviate internal carotid artery (ICA) stenosis and prevent future ischemic stroke as well as the need for carotid endarterectomy (CEA).<sup>5,8,13,21,23-26,28,30</sup> Various clinical trials are in progress to establish the indications for CAS.<sup>28,30</sup> Carotid stent thrombosis is a rare complication,<sup>4,6,12,24-26</sup> observed in only one of 146 procedures.<sup>24</sup> The reported incidence of carotid thrombosis after CAS ranges from 0.04% to 2%.<sup>8,21,24</sup> However, carotid thrombosis can cause severe neurological deficits. The standard strategy for treatment of carotid thrombosis has not yet been established, and the outcome after successful recanalization remains unclear. We have performed CAS for 307 patients with ICA stenosis in our institute using various protection devices since 1997.

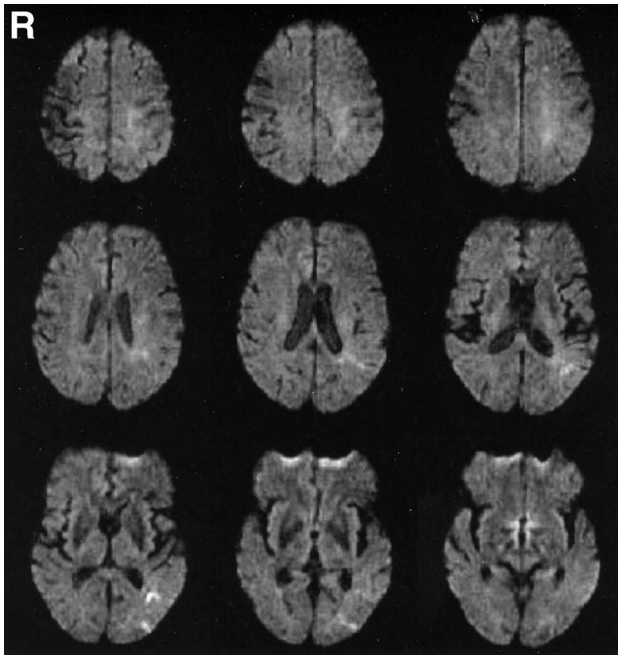
Here we describe a case of CAS complicated with stent thrombosis treated by in-stent percutaneous

transluminal angioplasty (PTA) under distal protection.

### Case Report

A 71-year-old man was admitted to our hospital with recurrent transient right hemiparesis and motor aphasia. Computed tomography (CT) on admission did not reveal any abnormal density areas. Diffusion-weighted magnetic resonance (MR) imaging showed a small high intensity area at the watershed territory of the ICA (Fig. 1). Emergent angiography revealed severe left ICA stenosis with thrombus (Fig. 2). Immediately after confirmation of the diagnosis, antiplatelet therapy (ticlopidine 200 mg/day, aspirin 100 mg/day) and systemic heparinization were started to maintain the activated clotting time between 200 and 250 seconds. However, transient ischemic attacks (TIAs) recurred 5 days after admission. Emergent angiography showed progressive stenosis with enlarged thrombus (Fig. 3).

CAS with distal protection was performed to alleviate the ischemia. First, pre-dilation was performed using a SAVVY balloon catheter (4.5 × 40



**Fig. 1** Diffusion-weighted magnetic resonance images on admission showing a high intensity area at the watershed territory of the internal carotid artery.

mm; Johnson & Johnson, New Brunswick, N.J., U.S.A.) under distal protection using the PercuSurge Guardwire system (Medtronic AVE, Danvers, Mass., U.S.A.). A SMARTer stent (8 × 40 mm; Johnson & Johnson) was then placed. After withdrawing the stent delivery system, the blood was aspirated using an export catheter. The aspirated blood contained a lot of thrombi. Angiography performed immediately after CAS revealed sufficient dilation without thrombus (Fig. 4). The patient's neurological status did not change after the procedure. Argatroban (60 mg/day) (anti-thrombin agent) was administered intravenously for 24 hours, with continuous antiplatelet therapy. No TIAs were observed after the treatment.

Three days after CAS, the patient developed progressive right hemiparesis and motor aphasia. CT did not reveal any abnormal density areas. Emergent angiography revealed stent occlusion due to in-stent thrombosis (Fig. 5). The distal ICA was supplied retrogradely from the external carotid artery via the ophthalmic artery.

We decided to attempt in-stent PTA to recanalize the occluded ICA. First, a microguidewire (Transend soft tip; Boston Scientific, Natick, Mass., U.S.A.) was easily introduced into the distal ICA beyond the thrombus. Then, a microcatheter (Rapidtransit; Johnson & Johnson) was gently advanced over the microguidewire, passing beyond

the stent. Angiography using the microcatheter confirmed that the thrombus did not extend to the distal ICA beyond the distal edge of the stent. Next, a PercuSurge Guardwire was easily passed through the thrombus and positioned at the distal ICA. Then, in-stent PTA was performed using a SAVVY balloon catheter (5 × 40 mm) for 2 minutes at 6 atm under distal balloon protection provided by the Guardwire. The PTA balloon catheter was withdrawn, and 40 ml of blood between the protective balloon and ICA bifurcation was aspirated using an export catheter. A lot of thrombi were detected in the aspirated blood by filtration. Angiography just after PTA showed recanalization of the occluded carotid artery with some residual thrombus (Fig. 6). Thus, the procedure was finished without additional stent placement in stent. Unfortunately, intravascular ultrasonography was not available because of the emergent procedure.

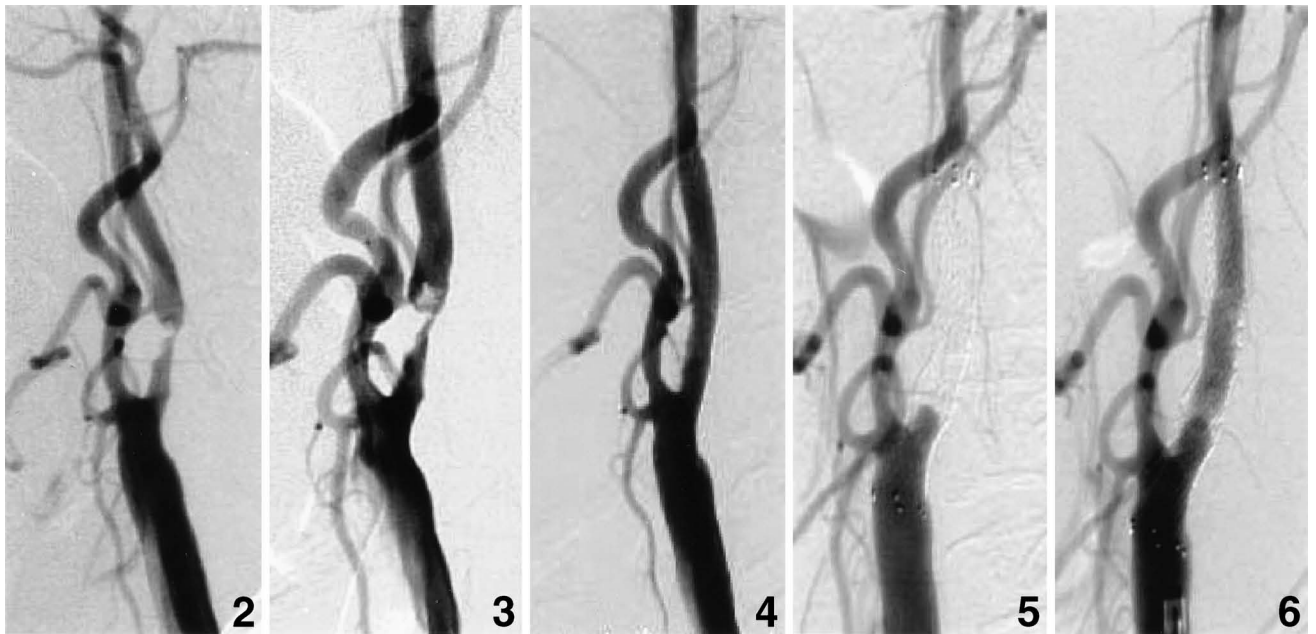
The neurological deficits improved immediately after PTA. Systemic heparinization was performed for 7 days after the PTA procedure. Diffusion-weighted MR imaging 2 days after recanalization revealed enlargement of the high intensity area at the watershed zone (Fig. 7). Follow-up angiography 1 week after recanalization showed reduced thrombus. Intravascular ultrasonography showed no floating thrombus around the stent. Ultrasonography 10 days after PTA showed that the stent was patent without remarkable thrombus. The patient was discharged with very mild right hemiparesis 14 days after the PTA procedure.

Follow-up ultrasonography 1 month after discharge did not show any thrombus or restenosis. The patient's hemiparesis disappeared. However, follow-up angiography 9 months after stenting showed 60% restenosis (Fig. 8). The patient had not developed any new neurological deficits. His progress has been closely observed continuing two antiplatelet agents without further treatment.

## Discussion

Two patients died of carotid thrombosis after CAS,<sup>6)</sup> but neither received adequate periprocedural antithrombotic medication. All other reported cases of carotid stent thrombosis have also involved insufficient antithrombotic medication.<sup>4,12,27)</sup> Acute thrombosis after intervention is the result of aggregation of activated platelets.<sup>14,20)</sup> Medication with a combination of aspirin and ticlopidine after coronary artery stenting prevented thrombus formation more effectively than medication with heparin only or with aspirin and warfarin.<sup>16)</sup> Therefore, combination antiplatelet therapy is currently recommended as the standard periprocedural medication.

In the present case, CAS was performed in the acute stage due to recurrent transient hemiparesis and progression of stenosis with enlarged thrombus,



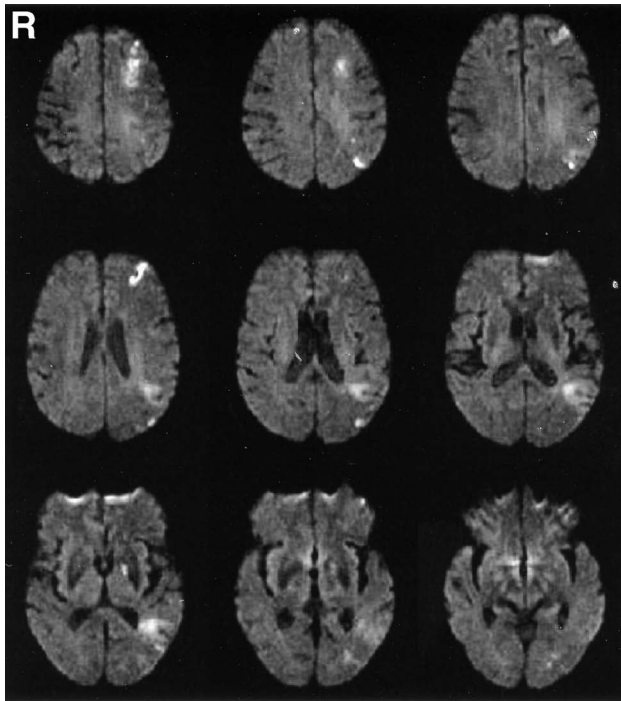
- Fig. 2** Left carotid angiogram on admission revealing severe left internal carotid artery stenosis with thrombus.
- Fig. 3** Left carotid angiogram before carotid artery stenting showing progressive stenosis with enlarged thrombus.
- Fig. 4** Left carotid angiogram immediately after carotid artery stenting revealing sufficient dilation without thrombus.
- Fig. 5** Left carotid angiogram before in-stent percutaneous transluminal angioplasty revealing stent occlusion due to in-stent thrombosis.
- Fig. 6** Left carotid angiogram after in-stent percutaneous transluminal angioplasty revealing recanalization of the occluded carotid artery with some residual thrombus.

which was refractory to antithrombotic treatment. The reasons why CAS was selected rather than CEA were that intraluminal thrombus was also one of high risk factors of CEA,<sup>10)</sup> and CAS had the advantage that we could easily detect the patient's neurological changes during procedure, because CAS could be performed under local anesthesia. The present patient received two antiplatelet agents immediately after admission, but these two agents apparently did not alleviate the TIAs. Thus, insufficient periprocedural antithrombotic medication appears to be a risk factor for development of carotid thrombosis after CAS.

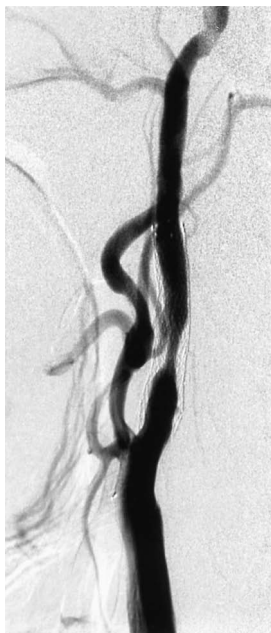The major risk factors for subacute stent thrombosis after coronary angioplasty are urgency of the procedure, inappropriate pretreatment, dissection at the uncovered stented portion, and a high degree of residual stenosis.<sup>17)</sup> The concept of "aspirin non-responder" also requires attention. So-called "aspirin non-responders" have a higher incidence of clinical ischemic events.<sup>2,11)</sup> Accordingly, aspirin resistance is another risk factor for stent thrombosis. Quantitative assessment of preoperative platelet function, for example with PFA-100, might be necessary to predict aspirin treatment failure.

Recent findings indicate that abciximab, which binds to the membrane surface glycoprotein IIb/IIIa platelet receptor, not only prevents thromboembolic complications after CAS but also facilitates recanalization for acute ischemic stroke.<sup>1,9,15,29)</sup> In fact, abciximab administration has achieved successful recanalization of occluded cerebral vessels in some cases.<sup>4,12,27)</sup> Systemic abciximab injection can dissolve carotid thrombosis without new neurological deficits,<sup>27)</sup> and carotid recanalization was achieved by percutaneous thrombectomy with AngioJet (Possis Medical Inc., Minneapolis, Minn., U.S.A.) and intravenous abciximab injection.<sup>4)</sup> However, abciximab is currently not available in Japan. In addition, hemorrhagic complications have been associated with the use of abciximab, although a randomized trial has shown that no additional hemorrhagic risk is associated with dose-escalation abciximab treatment.<sup>3,7,19)</sup> Therefore, abciximab is currently of limited use in cerebrovascular applications, because its safety has not been firmly established.

In the present case, we performed in-stent PTA under distal protection with PercuSurge, because Parodi's proximal protection system was not availa-



**Fig. 7** Diffusion-weighted magnetic resonance images 2 days after recanalization revealing enlargement of the high intensity area at the watershed zone.



**Fig. 8** Follow-up left carotid angiogram 9 months after stenting showing 60% restenosis.

ble at that time. A proximal flow control system such as Parodi's system is generally considered superior to distal protection for prevention of embolic complications during lesion crossing.<sup>22)</sup> Diffusion-weighted MR imaging after recanalization showed enlargement of the high intensity area at the watershed zone, but whether this increase was the result of carotid thrombosis or the PTA procedure was unclear. Fortunately the patient's neurological status improved dramatically after recanalization. Recurrence of carotid artery occlusion due to thrombosis was prevented by combined antithrombotic medication. In-stent PTA under distal balloon protection is one of the possible procedures for resolving carotid stent occlusion.

The outcome after successful rescue of carotid thrombosis remains unclear. In the present case, follow-up angiography 9 months after the CAS procedure revealed moderate restenosis without neurological symptoms. Activated platelets can cause carotid thrombosis formation, which can enhance the chemotactic and migratory properties of smooth muscle cells.<sup>18)</sup> The available evidence strongly suggests that activated platelets can lead to restenosis, and thus indicates that carotid thrombosis may be a risk factor for restenosis. Strict postoperative management is also needed after rescue from carotid thrombosis.

Carotid thrombosis after CAS can be resolved by a combination of in-stent PTA under distal protection and subsequent treatment with antithrombotic agents. Postprocedural management after recanalization is also important for the prevention of rethrombosis and restenosis.

## References

- 1) The Abciximab in Ischemic Stroke Investigators: Abciximab in acute ischemic stroke: a randomized, double-blind, placebo-controlled, dose-escalation study. *Stroke* 31: 601-609, 2000
- 2) Andersen K, Hurlen M, Arnesen H, Seljeflot I: Aspirin non-responsiveness as measured by PFA-100 in patients with coronary artery disease. *Thromb Res* 108: 37-42, 2002
- 3) Blankenship JC: Bleeding complications of glycoprotein IIb/IIIa receptor inhibitors. *Am Heart J* 138: 287-296, 1999
- 4) Bush RL, Bhama JK, Lin PH, Lumsden AB: Transient ischemic attack due to early carotid stent thrombosis: successful rescue with rheolytic thrombectomy and systemic abciximab. *J Endovasc Ther* 10: 870-874, 2003
- 5) CAVATAS Investigators: Endovascular versus surgical treatment in patients with carotid stenosis in the Carotid and Vertebral Artery Transluminal Angioplasty Study (CAVATAS): a randomised trial. *Lancet* 357: 1729-1737, 2001
- 6) Chaturvedi S, Sohrab S, Tselis A: Carotid stent thrombosis: report of 2 fatal cases. *Stroke* 32: 2700-2702, 2001
- 7) Cheung RT, Ho DS: Fatal hemorrhagic transforma-

- tion of acute cerebral infarction after the use of abciximab. *Stroke* 31: 2526-2527, 2000
- 8) Diethrich EB, Ndiaye M, Reid DB: Stenting in the carotid artery: initial experience in 110 patients. *J Endovasc Surg* 3: 42-62, 1996
  - 9) Eckert B, Koch C, Thomalla G, Roether J, Zeumer H: Acute basilar artery occlusion treated with combined intravenous Abciximab and intra-arterial tissue plasminogen activator: report of 3 cases. *Stroke* 33: 1424-1427, 2002
  - 10) Goldstein LB, McCrory DC, Landsman PB, Samsa GP, Ancukiewicz M, Oddone EZ, Matchar DB: Multicenter review of preoperative risk factors for carotid endarterectomy in patients with ipsilateral symptoms. *Stroke* 25: 1116-1121, 1994
  - 11) Grundmann K, Jaschonek K, Kleine B, Dichgans J, Topka H: Aspirin non-responder status in patients with recurrent cerebral ischemic attacks. *J Neurol* 250: 63-66, 2003
  - 12) Hamann GF, Liebetrau M, Pfefferkorn T, Heiss MM: Successful systemic thrombolysis for carotid stent thrombosis. *Eur Neurol* 48: 37-39, 2002
  - 13) Henry M, Polydorou A, Henry I, Polydorou A, Hugel M: Carotid angioplasty under cerebral protection with the PercuSurge GuardWire System. *Catheter Cardiovasc Interv* 61: 293-305, 2004
  - 14) Jeong MH, Owen WG, Staab ME, Srivatsa SS, Sangiorgi G, Stewart M, Holmes DR Jr, Schwartz RS: Porcine model of stent thrombosis: platelets are the primary component of acute stent closure. *Cathet Cardiovasc Diagn* 38: 38-43, 1996
  - 15) Kapadia SR, Bajzer CT, Ziada KM, Bhatt DL, Wazni OM, Silver MJ, Beven EG, Ouriel K, Yadav JS: Initial experience of platelet glycoprotein IIb/IIIa inhibition with abciximab during carotid stenting: a safe and effective adjunctive therapy. *Stroke* 32: 2328-2332, 2001
  - 16) Leon MB, Baim DS, Popma JJ, Gordon PC, Cutlip DE, Ho KK, Giambartolomei A, Diver DJ, Lasorda DM, Williams DO, Pocock SJ, Kuntz RE: A clinical trial comparing three antithrombotic-drug regimens after coronary-artery stenting. Stent Anticoagulation Restenosis Study Investigators. *N Engl J Med* 339: 1665-1671, 1998
  - 17) Lesiak M, Grajek S, Pyda M, Skorupski W, Mitkowski P, Grygier M, Prech M, Paradowski S, Cieslinski A: Subacute stent thrombosis following coronary angioplasty: incidence and risk factors. *Kardiolog Pol* 59: 408-416, 2003
  - 18) Massberg S, Vogt F, Dickfeld T, Brand K, Page S, Gawaz M: Activated platelets trigger an inflammatory response and enhance migration of aortic smooth muscle cells. *Thromb Res* 110: 187-194, 2003
  - 19) Moshiri S, Di Mario C, Liistro F, Melissano G, Chiesa R, Colombo A: Severe intracranial hemorrhage after emergency carotid stenting and abciximab administration for postoperative thrombosis. *Catheter Cardiovasc Interv* 53: 225-228, 2001
  - 20) Moussa I, Oetgen M, Roubin G, Colombo A, Wang X, Iyer S, Maida R, Collins M, Kreps E, Moses JW: Effectiveness of clopidogrel and aspirin versus ticlopidine and aspirin in preventing stent thrombosis after coronary stent implantation. *Circulation* 99: 2364-2366, 1996
  - 21) New G, Roubin GS, Iyer SS, Vitek JJ: Carotid artery stenting: rationale, indications, and results. *Compr Ther* 25: 438-445, 1999
  - 22) Ohki T, Parodi J, Veith FJ, Bates M, Bade M, Chang D, Mehta M, Rabin J, Goldstein K, Harvey J, Lipsitz E: Efficacy of a proximal occlusion catheter with reversal of flow in the prevention of embolic events during carotid artery stenting: an experimental analysis. *J Vasc Surg* 33: 504-509, 2001
  - 23) Reimers B, Schluter M, Castriota F, Tubler T, Corvaja N, Cernetti C, Manetti R, Picciolo A, Liistro F, Di Mario C, Cremonesi A, Schofer J, Colombo A: Routine use of cerebral protection during carotid artery stenting: results of a multicenter registry of 753 patients. *Am J Med* 15: 217-222, 2004
  - 24) Roubin GS, New G, Iyer SS, Vitek JJ, Al-Mubarak N, Liu MW, Yadav J, Gomez C, Kuntz RE: Immediate and late clinical outcomes of carotid artery stenting in patients with symptomatic and asymptomatic carotid artery stenosis: a 5-year prospective analysis. *Circulation* 103: 532-537, 2001
  - 25) Roubin GS, Yadav S, Iyer SS, Vitek JJ: Carotid stent-supported angioplasty: a neurovascular intervention to prevent stroke. *Am J Cardiol* 78(3A): 8-12, 1996
  - 26) Terada T, Tsuura M, Matsumoto H, Masuo O, Yamaga H, Tsumoto T, Itakura T: Results of endovascular treatment of internal carotid artery stenoses with a newly developed balloon protection catheter. *Neurosurgery* 53: 617-625, 2003
  - 27) Tong FC, Cloft HJ, Joseph GJ, Samuels OB, Dion JE: Abciximab rescue in acute carotid stent thrombosis. *AJNR Am J Neuroradiol* 21: 1750-1752, 2000
  - 28) Wholey MH, Wholey M, Mathias K, Roubin GS, Diethrich EB, Henry M, Bailey S, Bergeron P, Dorros G, Eles G, Gaines P, Gomez CR, Gray B, Guimaraens J, Higashida R, Ho DS, Katzen B, Kambara A, Kumar V, Laborde JC, Leon M, Lim M, Londero H, Mesa J, Musacchio A, Myla S, Ramee S, Rodriguez A, Rosenfield K, Sakai N, Shawl F, Sievert H, Teitelbaum G, Theron JG, Vaclav P, Vozzi C, Yadav JS, Yoshimura SI: Global experience in cervical carotid artery stent placement. *Catheter Cardiovasc Interv* 50: 160-167, 2000
  - 29) Winkley JM, Adams HP Jr: Potential role of abciximab in ischemic cerebrovascular disease. *Am J Cardiol* 85: 47C-51C, 2000
  - 30) Yadav JS, Roubin GS, Iyer S, Vitek J, King P, Jordan WD, Fisher WS: Elective stenting of the extracranial carotid arteries. *Circulation* 95: 376-381, 1997

---

Address reprint requests to: O. Masuo, M.D., Department of Neurological Surgery, Wakayama Medical University, 811-1 Kimiidera, Wakayama 641-8509, Japan.  
e-mail: omasuo@wakayama-med.ac.jp