

# A Case of Postpartum Cerebral Venous Thrombosis

Betty Cole, Laura M. Criddle

**Abstract:** Cerebral venous thrombosis, also known as cortical venous, cerebral sinus, cerebral venous sinus, or dural sinus thrombosis, results from clot formation in one of the many outflow tracts of the brain. Obstruction of flow causes venous hypertension, which is responsible for clinical findings associated with this condition. Signs and symptoms of cerebral venous thrombosis include headache, nausea, mental status changes, seizures, and focal neurologic deficits. Although cerebral venous thrombosis can occur at any time during life, women are particularly vulnerable before delivery and during the postpartum period because of the hypercoagulable state that accompanies pregnancy. This case study describes the challenging clinical course of one postpartum patient who developed venous thrombosis of the sagittal sinus.

## Case Report

Two weeks after the uncomplicated delivery of her fourth child, 32-year-old J. L. started experiencing severe headaches. On the day of presentation, J. L. was at home when she became increasingly disoriented and developed left upper-extremity uncoordination followed by a generalized seizure. After 911 was called, J. L. was transported to the healthcare facility in her rural community.

At the hospital, J. L. exhibited confusion, minimal left-side movement, and additional seizure activity. She was immediately intubated and sedated for seizure management. A computed tomography (CT) scan of her head did not detect any abnormalities, so brain magnetic resonance imaging (MRI) was performed. The MRI scan identified thrombosis of the anterior superior sagittal sinus with bifrontal infarctions. An intravenous loading dose of 5,000 units of heparin was given, followed by an infusion of 1,000 units per hour. J. L. was then transferred to a regional facility, where a repeat CT scan of her brain showed hemorrhagic transformation of her right frontal stroke. The heparin infusion was immediately discontinued, and preparations were made for fixed-wing transport to a neuroscience center in a neighboring state.

J. L. arrived at the tertiary facility intubated and sedated, with purposeful movement only in her right arm

and leg. She was quickly taken to the angiography suite, where a microcatheter was inserted in her femoral vein and threaded into the superior sagittal sinus to facilitate urokinase infusion (50,000 units per hour) directly to the site of the clot (Figs. 1, 2). This treatment was continued for 45 hours, until repeat angiography showed the sinus was once again patent. During fibrinolytic infusion, J. L. was observed closely for any evidence of hemorrhage. This observation included frequent neurologic assessment and serial CT scans to identify potential evolution of her intracranial hemorrhage. Daily laboratory values were monitored for changes in hemoglobin, hematocrit, and coagulation status.

Shortly after J. L. was admitted to the trauma-neurosciences intensive care unit (ICU), a subarachnoid intracranial pressure (ICP) monitoring device was placed. J. L.'s opening pressure was higher than 40 mm Hg. During the next several days, her persistently elevated ICP was treated with mannitol, paralytics, mechanical ventilation, and sedation (i.e., propofol, fentanyl, midazolam). She experienced occasional seizures and remained weak on the left side, but sedation and endotracheal intubation made it difficult to fully assess her mental status.

One week after arrival, J. L. was extubated. She demonstrated spontaneous eye opening but could not follow commands. On day 12, J. L. was transferred from the ICU to the neuroscience ward, still exhibiting left-side neglect and left-arm apraxia. Her speech was intact, but she had no memory of recent events, including the birth of her baby. On day 14, J. L. was stable enough for transfer to an inpatient rehabilitation unit near her home town. A follow-up report from her physician indicated that J. L. was eventually able to return home and resume care of her children.

## Discussion

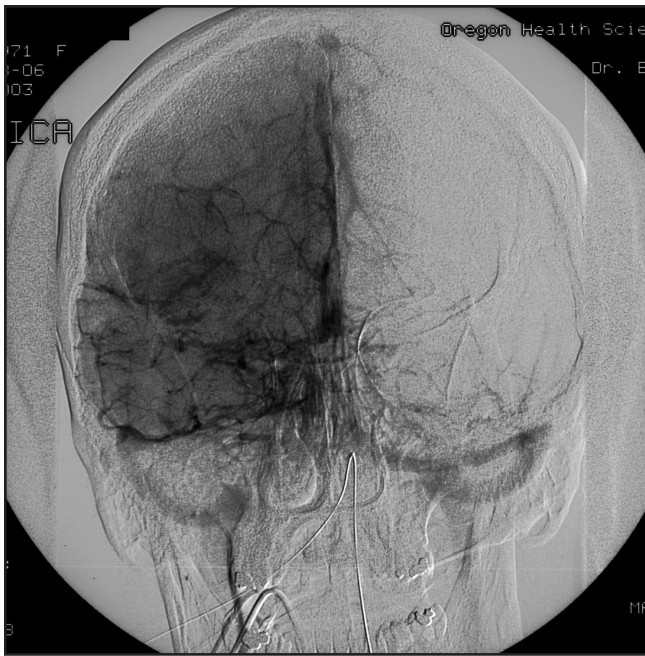
### Pathophysiology

The cerebral venous system is unique (Fig. 3). Unlike most vessels, the major veins of the brain are composed of dural folds called sinuses. The sinuses lack muscular walls, cannot contract, and contain no valves. The sinuses facilitate large amounts of venous drainage from the brain but also provide an excellent place for blood to pool. Sinus thrombosis occurs when a blood clot occludes one of the sinuses, obstructing venous return. The resulting intracranial hypertension can lead to brain edema, infarction, hemorrhage, and even death (Soleau, Schmidt, Stevens, Osborn, & MacDonald, 2003). *Cerebral venous thrombosis* (CVT) is the term collectively used to include clots not only of

Questions or comments about this article may be directed to Betty Cole, BSN RN CNRN, at colebe@ohsu.edu. She is the nursing practice and education coordinator for the trauma/neurosciences intensive care unit at Oregon Health & Science University, Portland, OR.

Laura M. Criddle, MS RN CNRN, is a doctoral student at Oregon Health & Science University, Portland, OR.

Copyright © 2006 American Association of Neuroscience Nurses 0047-2606/06/3805/00XX\$5.00



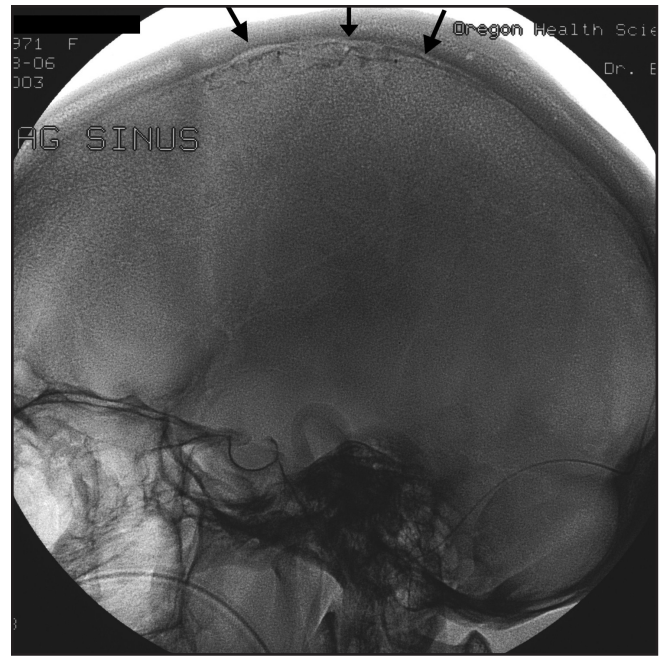
**Fig 1.** Cerebral angiogram showing right-sided injection (late venous phase). Image taken approximately 36 hours after urokinase treatment was initiated. The beaded appearance along the sagittal sinus is indicative of partial thrombosis.

the sagittal sinus but also of the cavernous sinus and parietooccipital regions. This condition is also referred to as cortical venous, cerebral sinus, cerebral venous sinus, or dural sinus thrombosis.

### Risk Factors

Three patient populations are at particular risk for CVT. The first comprises individuals with a blood-flow disturbance that increases. For example, increased blood viscosity can occur in patients with dehydration or polycythemia. Cases of CVT have been reported in persons living at high altitude, who commonly experience both polycythemia and dehydration (Basnyat, Wu, & Gertsch, 2004). The second at-risk group includes individuals with conditions that cause infection or fibrosis of the venous walls. Bacterial meningitis and frontal sinusitis are the most common sources of infection. The third at-risk group comprises patients who have an increased thrombotic tendency that is due to an inherited or acquired clotting disorder, such as the factor-V Leiden gene or antiphospholipid syndrome, or due to pregnancy (Horne & McCloskey, 2006).

Gravid patients have an elevated CVT risk because of the normal alterations in the coagulation process associated with pregnancy. During pregnancy, the patient experiences dramatic hematologic changes that prevent hemorrhage at the time of delivery, and these changes persist for several weeks postpartum. Fibrinogen, platelets, and most factor levels (VII, VIII, IX, X, and XII) are elevated, and fibrinolytic activity is reduced (Bousser & Russell, 1997). These

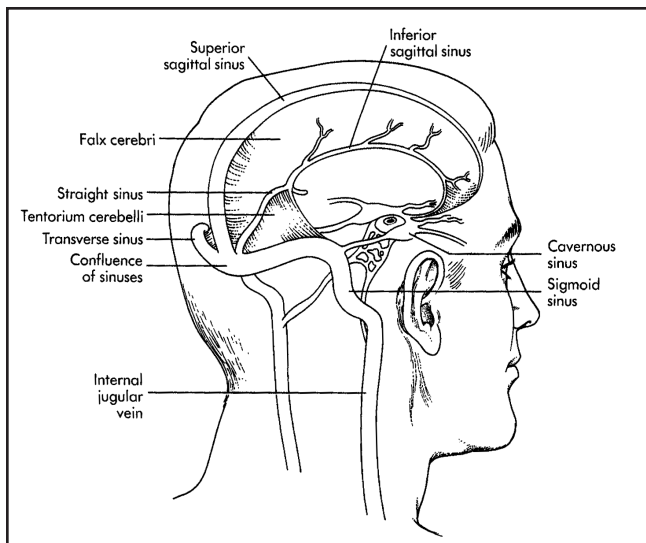


**Fig 2.** Cerebral angiogram (noncontrast study) showing the catheter in the jugular vein, sigmoid sinus, transverse sinus, and the sagittal sinus. Arrows indicate site of thrombus.

normal hematologic changes as well as other conditions that may be present, such as venous stasis, increased venous capacity, multiparity, and advanced age, combine to produce prime conditions for clot formation during the puerperium. This hypercoagulable state predisposes pregnant patients and new mothers to CVT. Cases of CVT have been reported as long as 3 months after delivery (Nazziola, 2003). In this state, the risk of a thromboembolic disease is three to four times greater than for other women (Chan & Ginsberg, 2002). Although CVT is much less common, in general, than deep vein thrombosis or pulmonary embolism, gravid patients are particularly susceptible to this condition. In some puerperal women with CVT, a deficiency of one or more coagulation factors was noted before pregnancy, but in most instances prepregnancy coagulation studies were completely normal.

### Clinical Findings

Cases of CVT have been documented in the medical literature since the early 1940s. However, until the mid-1980s, the diagnosis was made postmortem (Bousser & Russell, 1997). Symptoms produced by venous hypertension included headache, nausea, vomiting, motor weakness, decreased level of consciousness, visual complaints, photophobia, aphasia, ataxia, and seizures. The clinical presentation of CVT varies greatly; findings are not distinct, and they resemble those of many other neurologic conditions. In some patients, headache is the sole complaint.



**Fig 3.** Diagram showing the pattern of distribution of the major dural venous sinuses and their connection to the internal jugular veins. From *Cerebral Venous Thrombosis*, by M.-G. Boussier and R. R. Russell (p. 175), 1997, Philadelphia: Saunders. Copyright 1997 by Elsevier. Reprinted with permission.

One published case (Nazziola, 2003) illustrates how difficult it can be to establish a diagnosis of CVT when patients present with vague initial symptoms. A postpartum woman arrived in an emergency department complaining of headache and nausea. She had no alteration in level of consciousness and no focal neurologic deficits. The patient was discharged home when her brain CT scan was interpreted as normal. This woman returned to the emergency department the following day, complaining of the same symptoms. Once again, she was sent home after a normal lumbar puncture. On the third day, the woman arrived by ambulance following a generalized seizure. A repeat CT scan of the brain (with and without contrast) showed some ischemic changes. A magnetic resonance venogram was performed next; it revealed thrombosis of both the transverse and sigmoid sinuses. As this incident illustrates, because CVT symptoms can be vague, variable, and nonspecific, adequate radiologic imaging is essential. In one small series, 60% of CVT patients whose only presenting symptom was headache had initial CT scans that were interpreted as negative (Cumurciuc, Crassard, Sarov, Valade, & Boussier, 2005).

### Nursing Interventions

Nursing care of the individual with a CVT is similar to that of other patients with central nervous systems disorders and must be tailored to individual needs. In J. L.'s case, we used mechanical ventilation to ensure adequate oxygenation. Cerebral perfusion was supported by keeping the head of J. L.'s bed at 30 degrees, minimizing external stimulation, and maintaining her mean arterial pressure above 70 mm Hg. Intracranial pressure was monitored with a subarachnoid bolt. Spikes in ICP were treated

with mannitol, paralytics, sedation, analgesics, and positioning. These interventions were effective in keeping J. L.'s cerebral perfusion pressure within the target range. Other interventions for intracranial hypertension that are sometimes used in CVT patients include corticosteroids, diuretics, and barbiturate-induced coma.

Dysphagia is a common complication of CVT. To prevent aspiration, J. L. was given nothing by mouth for the first few days following extubation. Nutritional support was initiated early in the course of her illness and provided by tube feedings. Our patient's care included seizure prophylaxis with phenytoin (Dilantin); serum levels were monitored daily to ensure they remained in a therapeutic range. While she was receiving thrombolytic therapy, J. L. required regular nursing assessment to monitor for signs of blood in her gastrointestinal or urinary tracts. To prevent iatrogenic coagulopathies, J. L.'s prothrombin time-international normalized ratio (PT/INR) and partial thromboplastin time (PTT) were monitored daily. Ongoing discussions of prognosis and plans for long-term rehabilitation were held during frequent conferences with J. L.'s husband and family.

### Medical Interventions

Heparin administration is the standard treatment for CVT. Although lysis of the sinus thrombus does not occur with systemic anticoagulation, prevention of new thrombus formation is essential. The goal of heparin therapy is to halt clot proliferation and prevent worsening of clinical symptoms (Boussier & Russell, 1997; Chow et al., 2000). Heparin is generally continued until the patient stabilizes (Boussier & Russell). However, intracranial hemorrhage (as occurred in J. L.'s case) is a significant potential consequence of this therapy, and the benefits of anticoagulation must be carefully weighed against the risks.

Fibrinolytic drug therapy for CVT is provided by using a microcatheter to infuse a clot-dissolving agent into the dural sinus. This technique has been shown to be highly effective; however, access to therapy is currently limited to tertiary care centers, and this intervention is commonly reserved for patients with significant neurologic deficits.

Mechanical thrombolysis, with or without fibrinolytic drug therapy, can be accomplished by several mechanisms. Guidewires have been used for mechanical interruption of the thrombus. Interventional neuroradiologists can insert microcatheter balloons (e.g., coronary artery balloons) to dislodge or compress clots. Rheolytic thrombectomy catheters are also a treatment option for patients with CVT. The AngioJet<sup>®</sup>, the most commonly used rheolytic catheter, is a 5-french, 140-cm device that uses small saline jets to disrupt the clot. Mechanical intervention is indicated for patients in whom fibrinolytics are contraindicated, and for those who demonstrate poor response to local urokinase infusion or experience rapid neurological decline. When



interventional radiologic techniques are not available, craniectomy and thrombectomy have sometimes been used. It is important to note that many of these invasive procedures are still considered investigational (Baker, Opatowsky, Wilson, Glazier, & Morris, 2001).

Long-term medical therapy for CVT patients includes systemic anticoagulation with warfarin for an average of 6 months (Cakmak et al., 2003). Fortunately, the risk of CVT recurrence during subsequent pregnancies is low (Mehraein et al., 2003), and patients are not routinely counseled against future pregnancies. At present, insufficient data exists to determine the benefit of prophylactic anticoagulation in the gravid patient with a history of CVT (van der Stege, Engelen, & van Eyck, 1997).

### Prognosis

CVT associated with pregnancy is reported to have a better prognosis than CVT arising from other causes, with a mortality rate of approximately 10% (van der Stege et al., 1997). Researchers have estimated all-cause CVT mortality as 10%–30% (Baker et al., 2001; Chow et al., 2000). In a retrospective review of 170 peripartum patients with CVT, Lanska and Kryscio (2000) reported that more than 93% of patients were discharged home, and there were no deaths in their series. Although many CVT patients experience some persistent neurologic deficits, most will return to their previous level of function.

### Summary

Nursing care of the postpartum patient with CVT is similar to that of other patients with CVT. Neuroscience nurses caring for these patients can be instrumental in the prevention of secondary brain insult by performing frequent neurological assessments for signs of change, providing rapid interventions as appropriate, and carefully monitoring coagulation studies to prevent complications associated with anticoagulation therapies.

## End-of-Life Concepts *continued from page 348*

### References

- American Association of Colleges of Nursing. (1998). *Peaceful death: Recommended competencies and curricular guidelines for end-of-life nursing care*. Washington, DC: Author.
- Cassel, C. K., & Foley, K. M. (1999). *Principles of care of patients at the end-of-life: An emerging consensus among the specialties of medicine*. New York: Milbank Memorial Fund.
- City of Hope. (1999). *End-of-life care content guideline*. Duarte, CA: Author.
- English, N., & Yocum, C. (1996). *Guidelines for curriculum development on end-of-life and palliative care in nursing education*. Alexandria, VA: National Hospice Organization.
- Ferrell, B. R., & Coyle, N. (2002). An overview of palliative nursing care. *Lippincott's Case Management*, 7, 163–168.
- Ferrell, B. R., Virani, R., & Grant, M. (1999a). Analysis of symptom assessment and management content in nursing textbooks. *Journal of Palliative Medicine*, 2, 161–172.
- Ferrell, B. R., Virani, R., & Grant, M. (1999b). Analysis of end-of-life content in nursing textbooks. *Oncology Nursing Forum*, 26, 869–876.

### References

- Baker, M. D., Opatowsky, M. J., Wilson, J. A., Glazier, S. S., & Morris, P. P. (2001). Rheolytic catheter and thrombolysis of dural venous sinus thrombosis: A case series. *Neurosurgery*, 48, 487–493.
- Basnyat, B., Wu, T., & Gertsch, J. H. (2004). Neurological conditions at altitude that fall outside the usual definition of altitude sickness. *High Altitude Medical Biology*, 5(2), 171–179.
- Bousser, M. G., & Russell, R. R. (1997). *Cerebral venous thrombosis*. London: Saunders.
- Cakmak, S., Derex, L., Berruyer, M., Nighoghossian, N., Philippeau, F., Adeleine, P., et al. (2003). Cerebral venous thrombosis: Clinical outcome and systematic screening of prothrombotic factors. *Neurology*, 60, 1175–1178.
- Chan, W. S., & Ginsberg, J. S. (2002). Diagnosis of deep vein thrombosis and pulmonary embolism in pregnancy. *Thrombosis Research*, 107, 85–91.
- Chow, K., Gobin, Y. P., Saver, J., Kidwell, C., Dong, P., & Vinuela, F. (2000). Endovascular treatment of dural sinus thrombosis with rheolytic thrombectomy and intra-arterial thrombolysis. *Stroke*, 31, 1420–1425.
- Cumurciuc, R., Crassard, I., Sarov, M., Valade, D., & Bousser, M. G. (2005). Headache as the only neurological sign of cerebral venous thrombosis: A series of 17 cases. *Journal of Neurology, Neurosurgery, and Psychiatry*, 76, 1084–1087.
- Horne, M. K., & McCloskey, D. J. (2006). Factor V Leiden as a common genetic risk factor for venous thromboembolism. *Journal of Nursing Scholarship*, 38(1), 19–25.
- Lanska, D. J., & Kryscio, R. J. (2000). Risk factors for peripartum and postpartum stroke and intracranial venous thrombosis. *Stroke*, 31, 1274–1282.
- Mehraein, S., Ortwein, H., Busch, M., Weih, M., Einhaupl, K., & Masuhr, F. (2003). Risk of recurrence of cerebral venous and sinus thrombosis during subsequent pregnancy and puerperium. *Journal of Neurology, Neurosurgery, and Psychiatry*, 74, 814–816.
- Nazziola, E. (2003). Dural sinus thrombosis presenting three months postpartum. *Annals of Emergency Medicine*, 42, 592–595.
- Soleau, S. W., Schmidt, R., Stevens, S., Osborn, A., & MacDonald, J. D. (2003). Extensive experience with dural sinus thrombosis. *Neurosurgery*, 52, 542–544.
- van der Stege, J. G., Engelen, M. J. A., & van Eyck, J. (1997). Uncomplicated pregnancy and puerperium after puerperal CVT. *European Journal of Obstetrics, Gynecology, and Reproductive Biology*, 71, 99–100.

- Ferrell, B. R., Virani, R., & Grant, M. (1999c). Review of communication and family caregiver content in nursing texts. *Journal of Hospice and Palliative Nursing*, 1, 97–107.
- Field, M. J., & Cassel, C. K. (Eds.). (1997). *Approaching death: Improving care at the end of life*. Washington, DC: National Academy Press.
- Joint Commission on the Accreditation of Healthcare Organizations. (1999). *New JCAHO standards, intents, examples, and scoring questions for pain assessment and management in hospitals*. Oakbrook Terrace, IL: Author.
- Lewis, L. (2001). Toward a good death in the nursing home: Pain management and hospice are key. *Caring for the Ages*, 2(7), 24–26.
- National Consensus Project. (2004). *Clinical practice guidelines for quality palliative care*. Brooklyn, NY: Author.
- Rabow, M. W., Hardie, G. E., Fair, J. M., & McPhee, S. J. (2000). An evaluation of end-of-life care content in 50 textbooks from multiple specialties. *Journal of the American Medical Association*, 283, 771–778.