

Letter to the Editor

Documentation of dynamic electrocardiographic changes shortly after the onset of tako-tsubo cardiomyopathy

Satoshi Kurisu*, Ichiro Inoue, Takuji Kawagoe, Masaharu Ishihara, Yuji Shimatani, Takaki Hata, Yasuharu Nakama, Yasufumi Kijima, Eisuke Kagawa

Department of Cardiology, Hiroshima City Hospital, 7-33, Moto-machi, Naka-ku, Hiroshima, 730-8518 Japan

Received 6 March 2006; received in revised form 21 July 2006; accepted 29 July 2006

Available online 31 October 2006

Abstract

A 76-year-old female with atrial fibrillation and prior cerebral infarction had chest discomfort during rehabilitation for left hemiparesis, and visited the nearby hospital. Her ECG, which was obtained 10 min after the onset, showed marked ST-segment elevation in leads I, II, III, aV_F and V₂₋₆, and she was referred to our hospital for cardiac examination. On admission, her ECG, which was obtained 50 min after the onset, showed poor R wave progression and mild ST-segment elevation in leads V₅₋₆. During only 10 min after the admission, the ST-segment level increased dynamically, and it decreased spontaneously again. Left ventriculography showed akinesia of the mid-to-distal portion and hyperkinesia of the basal portion of the left ventricular chamber, and coronary angiography showed no significant coronary artery disease despite of significant ST-segment elevation. We diagnosed her as having tako-tsubo cardiomyopathy. She was discharged well 10 days later.

© 2006 Elsevier Ireland Ltd. All rights reserved.

Keywords: Electrocardiogram; Tako-tsubo; ST-segment

1. Introduction

Tako-tsubo cardiomyopathy, which was first reported by Sato et al in 1990 [1], has been gradually recognized worldwide through reports mainly from Japan [1–4]. Nowadays, tako-tsubo cardiomyopathy should be involved in differential diagnoses for acute myocardial infarction (AMI) especially in elderly females. Several studies have demonstrated that electrocardiographic (ECG) changes of tako-tsubo cardiomyopathy mimics those of acute myocardial infarction during early phase. However, it remains unclear how ECG changes shortly after the onset of tako-tsubo cardiomyopathy.

We report a patient with tako-tsubo cardiomyopathy in whom serial ECG could be obtained from the time shortly after the onset.

2. Case report

A 76-year-old female with atrial fibrillation and prior cerebral infarction had chest discomfort during rehabilitation for left hemiparesis, and visited the nearby hospital. Her ECG, which was obtained 10 min after the onset, showed marked ST-segment elevation in leads I, II, III, aV_F and V₂₋₆ (Fig. 1). She was referred to our hospital for cardiac examination.

On admission, she was conscious, her blood pressure was 130/70 mmHg, and pulse rate was 72 beats/min. Her hematological test results were normal, and chest X-ray showed no pulmonary edema or cardiac enlargement. Her ECG, which was obtained 50 min after the onset, showed atrial fibrillation, poor R wave progression and mild ST-segment elevation in leads V₅₋₆. Transthoracic echocardiography showed akinesia of the mid-to-distal portion of the left ventricular chamber with an ejection fraction of 46%. During only 10 min after the admission, the ST-segment level increased dynamically, and it decreased spontaneously again (Fig. 1). She complained of only mild chest discomfort with a smile on her face even at the time when the ST-segment level increased to 10 mm.

* Corresponding author. Tel.: +81 82 221 2291; fax: +81 82 223 1447.

E-mail address: skurisu@nifty.com (S. Kurisu).

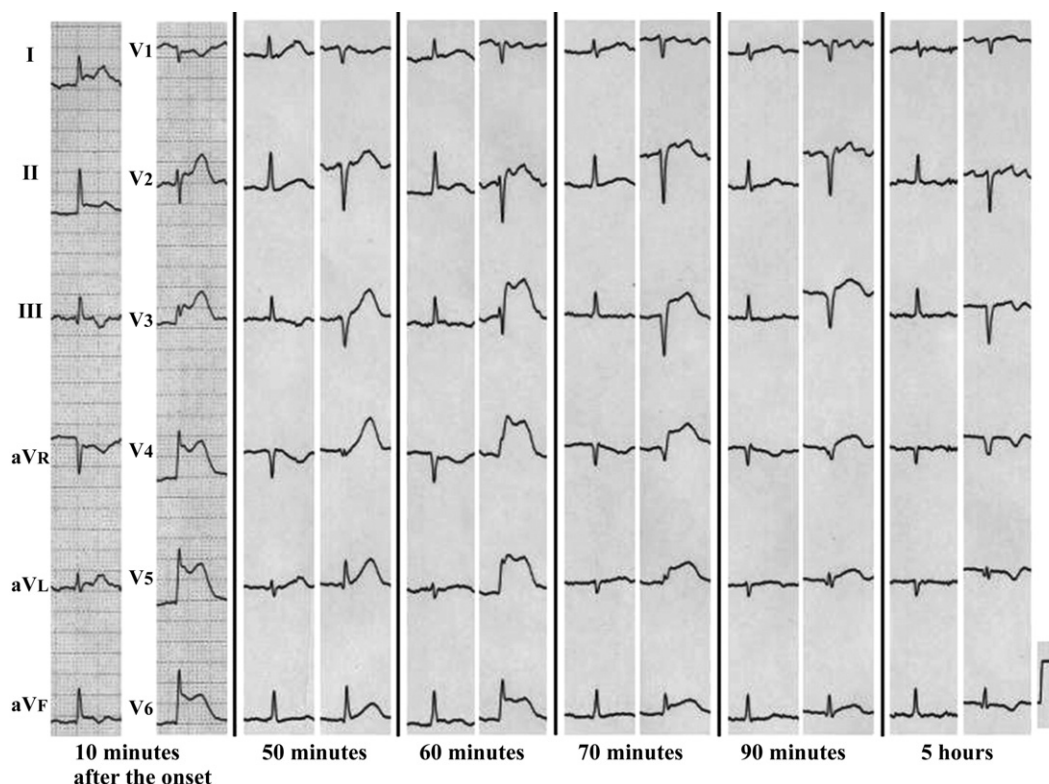


Fig. 1. Serial electrocardiogram after the onset of tako-tsubo cardiomyopathy. The ST-segment level increased dynamically, and it decreased spontaneously again. No reciprocal change of ST-segment was found.

After written informed consent was obtained, emergency cardiac catheterization was performed 80 min after the onset when ST-segment elevation was still found. Left ventriculography showed akinesia of the mid-to-distal portion and hyperkinesia of the basal portion of the left ventricular chamber. Left ventricular outflow tract obstruction or mitral regurgitation was not found. Coronary angiography showed no significant coronary artery disease despite of significant ST-segment elevation. We diagnosed her as having tako-tsubo cardiomyopathy (Fig. 2).

Her ECG, which was obtained 5 h after the onset, showed poor R wave progression and T wave inversion in leads V_{3–6}, but did not show ST-segment elevation in any leads. The value of creatine phosphokinase increased to 1520 IU/L 5 h after the onset. No reciprocal change of ST-segment or malignant arrhythmia was found during the follow-up. Follow-up transthoracic echocardiography 7 days later showed improvement of left ventricular function with an ejection fraction of 76%. She was discharged 10 days later.

3. Discussion

In the current report, we first demonstrated serial dynamic ECG changes from the time shortly after the onset of tako-tsubo cardiomyopathy.

Tako-tsubo cardiomyopathy has become accepted as a distinct clinical entity through many reports [1–6], and it should be involved in differential diagnoses for AMI now-

adays. Ogura et al recently reported that the absence of reciprocal change and the ratio of ST-segment elevation in leads V_{4–6} to V_{1–3} ≥ 1 showed a high sensitivity and specificity for diagnosing tako-tsubo cardiomyopathy [3]. These findings were found in our patient's ECG during early phase.

There has been no report demonstrating ECG change shortly after the onset of tako-tsubo cardiomyopathy in detail. One possible reason is that patients with tako-tsubo cardiomyopathy may not take medical advice immediately after the onset, because chest symptom is not generally as serious as that in AMI. The other is that it may take a long time to make the diagnosis of tako-tsubo cardiomyopathy because of mild symptom. In the current report, we first demonstrated serial dynamic ECG changes from the time shortly after the onset.

During follow-up of tako-tsubo cardiomyopathy, ECG changes mimic those of AMI, including ST-segment elevation, T wave inversion and QT interval prolongation. We previously reported that ST-segment elevation was found in 100% and T wave inversion was found in 39% of 30 patients with tako-tsubo cardiomyopathy [2]. On the other hand, Wittstein et al recently reported that ST-segment elevation was found in only 11% and T wave inversion was found in 100% of 19 patients [6]. Because ST-segment elevation is known to be followed by T wave inversion [4], this discrepancy may be due to the difference of time from the onset to the presentation among reports.

Several possible mechanisms have been proposed, including epicardial coronary spasm [2], microvascular coronary

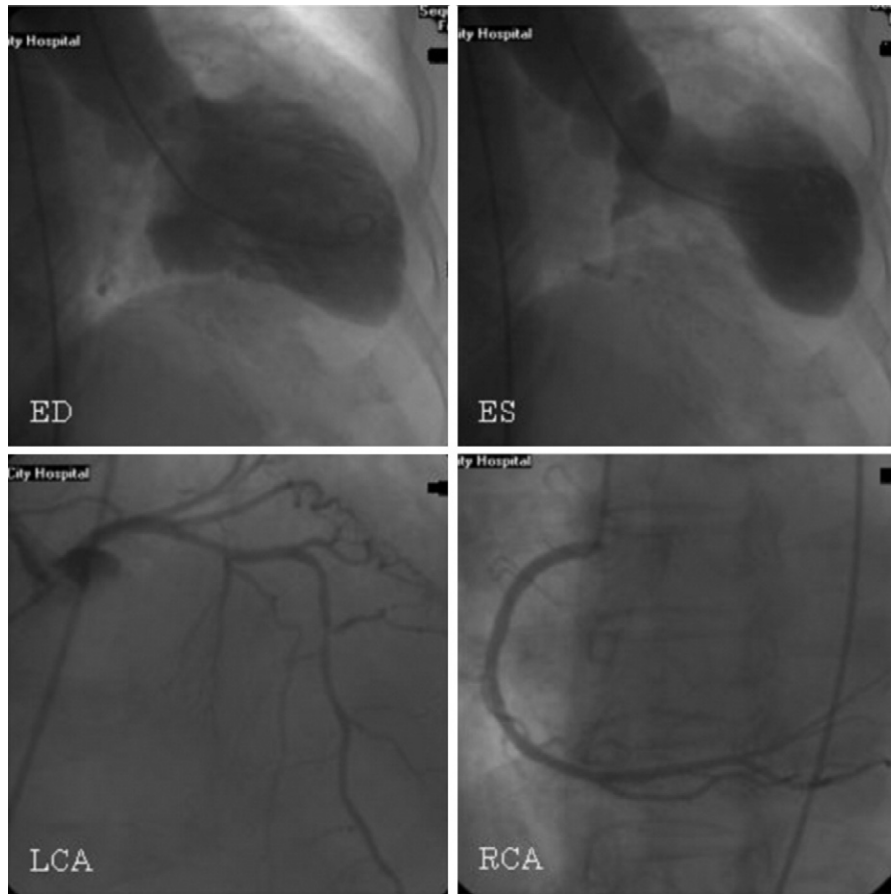


Fig. 2. Emergency cardiac catheterization 80 min after the onset. Left ventriculography showed akinesia of the mid-to-distal portion and hyperkinesia of the basal portion of the left ventricular chamber (upper panels). Coronary angiography showed no significant coronary artery disease (lower panels). ED = end-diastole; ES = end-systole; LCA = left coronary artery; RCA = right coronary artery.

spasm [2] or catecholamine-mediated toxicity [6]. In the current patient, epicardial coronary spasm did not appear to be the causative mechanism, because coronary angiography showed no significant coronary artery disease during dynamic ECG changes. In addition, we did not measure catecholamine levels regrettably. Although the precise causative mechanism remains unclear, dynamic ECG changes shortly after the onset appears to mean ongoing myocardial injury. Clinicians should recognize that tako-tsubo cardiomyopathy is one of the etiologies of dynamic ECG changes. This may allow the early and precise diagnosis of tako-tsubo cardiomyopathy.

Further studies are necessary to clarify what kind of drug can prevent ongoing myocardial injury during early phase of tako-tsubo cardiomyopathy.

References

- [1] Sato H, Tateishi H, Uchida T, Dote K, Ishihara M. Tako-tsubo-like left ventricular dysfunction due to multivessel coronary spasm. In: Kodama K, Haze K, Hori M, editors. Clinical aspect of myocardial injury: from ischemia to heart failure. Tokyo: Kagakuhyoronsha Publishing Co.; 1990. p. 56–64. (in Japanese).
- [2] Kurisu S, Sato H, Kawagoe T, et al. Tako-tsubo-like left ventricular dysfunction with ST segment elevation: a novel cardiac syndrome mimicking acute myocardial infarction. *Am Heart J* 2002;143:448–55.
- [3] Ogura R, Hiasa Y, Takahashi T, et al. Specific findings of the standard 12-lead ECG in patients with 'takotsubo' cardiomyopathy: comparison with the findings of acute anterior myocardial infarction. *Circ J* 2003;67:687–90.
- [4] Kurisu S, Inoue I, Kawagoe T, et al. Time course of electrocardiographic changes in patients with tako-tsubo syndrome: comparison with acute myocardial infarction with minimal enzymatic release. *Circ J* 2004;68:77–81.
- [5] Desmet WJ, Adriaenssens BF, Dens JA. Apical ballooning of the left ventricle: first series in white patients. *Heart* 2003;89:1027–31.
- [6] Wittstein IS, Thiemann DR, Lima JA, et al. Neurohumoral features of myocardial stunning due to sudden emotional stress. *N Engl J Med* 2005;352:539–48.