

CASE REPORTS

From the Society for Clinical Vascular Surgery

Correction of symptomatic cerebral malperfusion due to acute type I aortic dissection by transcrotid stenting of the innominate and carotid arteries

Glen S. Roseborough, MD, Kieran P. Murphy, MD, Peter B. Barker, DPhil, and Marc Sussman, MD, Baltimore, Md

Introduction: Acute proximal aortic dissection may be complicated by stroke due to malperfusion of the arch vessels. We report a novel case of successful endovascular treatment of acute cerebral malperfusion due to a dissection involving the aortic arch.

Case Report: A 66 year old man was transferred from another hospital with an acute type I aortic dissection and underwent emergent repair of the aortic valve and ascending aorta with a composite graft. Left hemiplegia and altered cognitive function were noted on postoperative day 1. A carotid duplex scan showed partial thrombosis of the right carotid artery with very slow flow and reversal of flow in the right vertebral artery. A head CT was normal, while a head MRI and MR angiogram showed intraluminal defects in the innominate and right carotid arteries and perfusion abnormality of the entire right middle cerebral artery territory, but only small infarcts of watershed areas. The patient underwent stenting of the right carotid and innominate arteries through the right carotid artery with complete resolution of a large pressure gradient that was noted prior to stenting. The patient's left hemiplegia and cognitive impairment subsequently resolved during his inpatient hospitalization. On follow up five months later, he had a normal neurologic exam and MRI showed old watershed infarcts but no perfusion abnormality. On most recent follow-up 2.5 years after treatment, he remains well and a CT angiogram shows that his stented vessels remain patent.

Conclusion: Endovascular techniques may be safely applied to correct cerebral malperfusion that results from type I aortic dissection. (J Vasc Surg 2006;44:1091-6.)

Acute dissection of the ascending aorta and aortic arch is complicated by stroke in 6% to 20% of cases, either at presentation or in the postoperative period.¹⁻³ Stroke at presentation is usually a complication of malperfusion of the aortic arch vessels, whereas postoperative stroke complicating a surgical repair can be multifactorial. In either situation, the occurrence of stroke is a strong predictor of adverse outcomes from aortic dissection.²⁻¹¹ When recognized at the time of operation, arch vessel malperfusion can be corrected surgically, but this is not always feasible, and although aortic procedures such as open surgical or percutaneous fenestration have been performed successfully to

relieve visceral, renal, and extremity malperfusion, there is no published evidence that performing additional procedures at the time of ascending aortic repair, such as arch repair or arch vessel bypass, improves outcomes in the setting of an acute neurologic deficit.

We report a case wherein a patient developed a right hemispheric stroke in the setting of profound malperfusion of the innominate and right carotid artery after undergoing surgical repair of a type I dissection, which was successfully managed with transarterial stenting of the right carotid and innominate arteries.

CASE REPORT

The patient was a 66-year-old black man who presented to a community hospital complaining of sudden-onset chest and back pain. He was found to have an ischemic right lower extremity and underwent transfemoral thrombectomy of the right leg, with apparent retrieval of some proximal and distal clot and improvement in the right leg perfusion. Doppler signals were restored in the pedal vessels where they were previously absent. After surgery, his chest and back pain worsened, so he underwent a magnetic

From the Johns Hopkins Hospital, Baltimore, Md.

Competition of interest: none.

Presented as a poster at the Thirty-fourth Annual Meeting of the Society for Clinical Vascular Surgery, Las Vegas, Nev, March 8-10, 2006.

Reprint requests: Glen S. Roseborough, MD, Johns Hopkins Hospital, Johns Hopkins University, 600 N Wolfe St, Harvey 611, Baltimore, MD 21287 (e-mail: gsrosebo@jhmi.edu).

0741-5214/\$32.00

Copyright © 2006 by The Society for Vascular Surgery.

doi:10.1016/j.jvs.2006.05.053

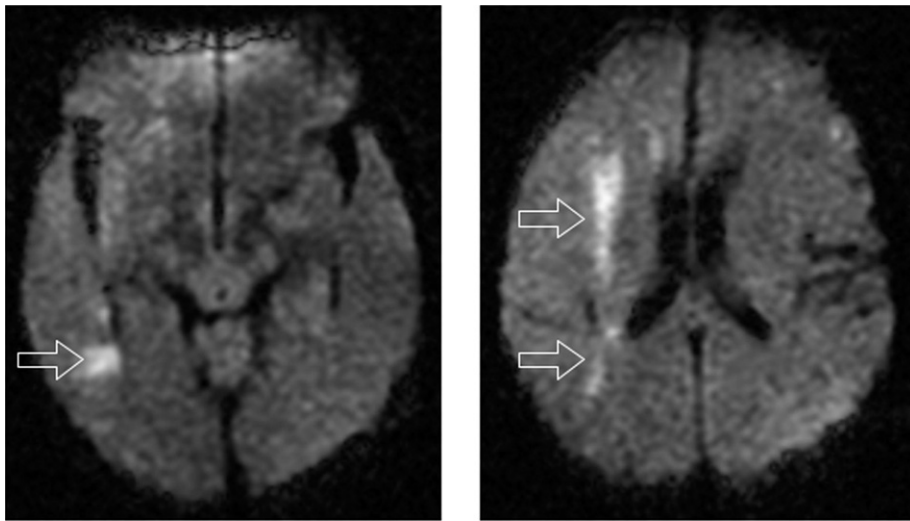


Fig 1. Diffusion-weighted magnetic resonance images of the brain performed 3 days after aortic reconstruction, before carotid stenting. Arrows point to multiple areas of restricted diffusion in the anterior and posterior watershed areas of the right cerebral hemisphere, consistent with acute infarcts.

resonance imaging (MRI) scan of the chest that showed a type I aortic dissection. This study showed patent arch vessels with intimal flaps extending into the innominate, left carotid, and left subclavian arteries. The next day, he was transferred to a second hospital and then subsequently to our facility later that night for definitive therapy. Before transfer to our facility, he became hypoxic and was intubated. On admission to our hospital, he was obtunded and unresponsive to commands (presumably from the sedation he had received for intubation and ventilation), but he had palpable bilateral carotid and radial artery pulses, palpable left leg pulses, and good Doppler signals in the right leg.

The patient was taken to the operating room that night and underwent a composite repair of the aortic root with a prosthetic aortic valve. Cardiopulmonary bypass was performed with arterial perfusion via the left femoral and right subclavian arteries. The distal ascending aorta was transected and opened under circulatory arrest after the patient had been cooled on cardiopulmonary bypass for 40 minutes. During circulatory arrest, perfusion of the right hemisphere of the brain was maintained with the bypass circuit via a Dacron graft (DuPont, Wilmington, Del) that was sutured to the right subclavian artery. The innominate artery and left common carotid arteries were clamped at their bases while the right subclavian artery was perfused. A Dacron valve conduit was sewn end to end to the distal ascending aorta after the intima and adventitia were reapproximated and reinforced with Bioglue (Cordis Neurovascular Inc., Miami, Fla). The graft was clamped, and full bypass was recommenced. The aortic valve was then replaced with reimplantation of the coronary ostia. As the patient was separated from bypass, severe bleeding was noted at the aortic root anastomosis. Also at this time, it was noted that the blood pressure and waveform in a right radial arterial line were lost and that there was no pulse in the right carotid artery. To control bleeding, it was necessary to go back on bypass and revise the anastomosis to the aortic root. By the time the revision was completed, the patient was severely coagulopathic. Although the patient still had no right radial or carotid pulse at this

time, the decision was made to defer carotid revascularization because of the coagulopathy and because, since the carotid artery had been malperfused for several hours by this point, it was believed that the patient may already have suffered a stroke and may not benefit from revascularization.

The patient's chest was packed with sponges and he was returned to the intensive care unit, where he continued to bleed, early the morning after admission. Later that day he experienced an asystolic arrest from which he was successfully resuscitated. He was returned to the operating room urgently for re-exploration. Bleeding at the distal anastomosis to the ascending aorta was found and controlled. The chest was packed again, and he was returned to the operating room 2 days later for washout and definitive closure.

After the second operation, no spontaneous movement was noted on the patient's left side. A carotid duplex scan obtained the day after his second operation showed very slow flow (10 cm/s) in the right common carotid artery. A head computed tomograph (CT) obtained the next day was basically normal. The day after his chest was closed, a carotid and brain MRI/magnetic resonance angiograph was obtained. This study showed multiple foci of hyperintense signals on diffusion-weighted images consistent with small watershed infarcts in the right hemisphere (Fig 1), as well as malperfusion of the entire right hemisphere on perfusion-weighted images (Fig 2, A).

Vascular surgery and neuroradiology were consulted for revascularization of the right carotid system. Because of the complex dissection involving the aortic arch (Fig 3), a percutaneous femoral approach was believed to be problematic. The patient was taken to the operating room the following day (4 days after his initial aortic operation). The right common carotid artery was explored and found to be pulseless. It was accessed with a 6F sheath. Retrograde angiography showed a tight stenosis at the origin of the right common carotid artery. A 0.014-inch Luge wire was passed into the descending thoracic aorta, and an 8 mm × 2-cm Wallstent (Boston Scientific Corp., Natick, Mass) was deployed across the

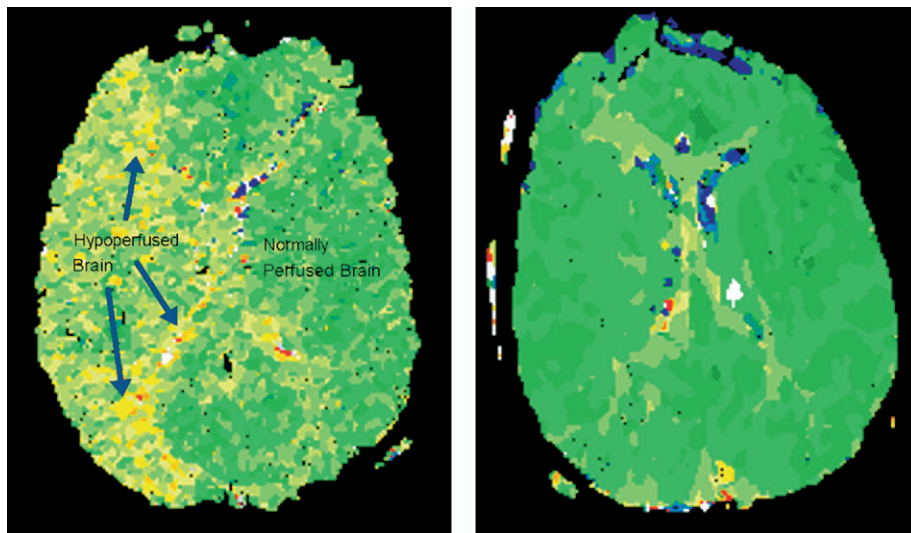


Fig 2. A, Magnetic resonance imaging (MRI) perfusion-weighted images of the patient's brain before revascularization with transcatheter stenting. Yellow regions represent hypoperfused areas of right hemisphere of the brain. B, Follow-up MRI 5 months after revascularization showing symmetrical perfusion of both hemispheres.

innominate artery bifurcation and origin of the right common carotid artery. Repeat angiography showed resolution of the stenosis in the carotid artery, but contrast did not reflux through the innominate artery. Transduction of the carotid sheath showed that the arterial pressure in the sheath was 48/40 mm Hg, compared with a pressure of 120/80 mm Hg by left radial artery catheter, and the right carotid artery remained pulseless. A 10 mm × 4-cm Wallstent was then deployed in the innominate artery. This resulted in equalization of pressures between the carotid sheath and the radial artery catheter and restoration of a pulse in the carotid artery. Completion retrograde angiography showed contrast refluxing through the innominate artery into the aortic arch (Fig 4). Intracerebral angiography showed markedly improved filling of the right hemisphere after stenting compared with that before stenting (Fig 5).

The patient was returned to the intensive care unit, where his mental status started to improve immediately. He was extubated 2 days later. Over the next several days, he started to regain some strength in the left arm and leg. By 8 days after his revascularization, he could stand with full assist and recovered some left arm strength but had left-sided neglect. Six days later, he could walk 5 feet with moderate assist. At that time, he was transferred to an inpatient rehabilitation unit. He remained there for 20 days, during which time he progressed from a moderate assist level with mobility and self-care to a modified independent level. He was discharged home at that point, and over the next several months he recovered completely. A follow-up MRI 5 months after his acute dissection showed old watershed infarcts in his right cerebral hemisphere but no diffusion-perfusion abnormality (Fig 2, B). A follow-up CT angiogram performed almost 2.5 years later showed patent stents in the right carotid and innominate arteries (Fig 6).

DISCUSSION

Catheter-based interventions, including aortic fenestration and branch vessel stenting, have been used to ad-

dress malperfusion complicating aortic dissection in distal vascular territories.¹²⁻¹⁹ To our knowledge, this is the first reported case in which an ischemic stroke caused by malperfusion of arch vessels was successfully reversed by stenting of the involved arch vessels. In this case, the technique was used to treat hemiplegia that became apparent after surgery, after the patient had experienced hemorrhage, hypotension, and a cardiac arrest.

Experience with acute carotid artery revascularization in the setting of stroke has been derived mainly from three clinical situations: carotid thromboendarterectomy for thrombotic stroke, intravenous or intra-arterial thrombolysis for thrombotic stroke, and urgent carotid artery repair for carotid trauma. Although several studies have documented a significant association of carotid artery thrombosis with perioperative stroke in acute aortic dissection, there is very little published experience with acute carotid revascularization to correct stroke from acute aortic dissection. In 1988, Cambria et al² reported on vascular complications associated with spontaneous aortic dissection in 325 patients over 21 years at the Massachusetts General Hospital. Strokes occurred in 17 (15%) of 116 type I dissections, and of 26 patients in the entire series who had acute carotid occlusions, completed strokes occurred in 22 patients (85%). Carotid occlusion occurred on the right in two thirds of cases and was frequently associated with innominate artery occlusion. Only 1 of 22 patients with stroke had a patent ipsilateral carotid artery. The exception was an occipital infarction from a basilar artery embolism. Two patients in this series underwent extra-anatomic revascularization of the involved carotid artery without aortic reconstruction, with no improvement in their clinical picture.

Lauterbach et al²⁰ updated the Massachusetts General Hospital experience through the 1990s and found that carotid artery occlusion was documented in 10 of 101

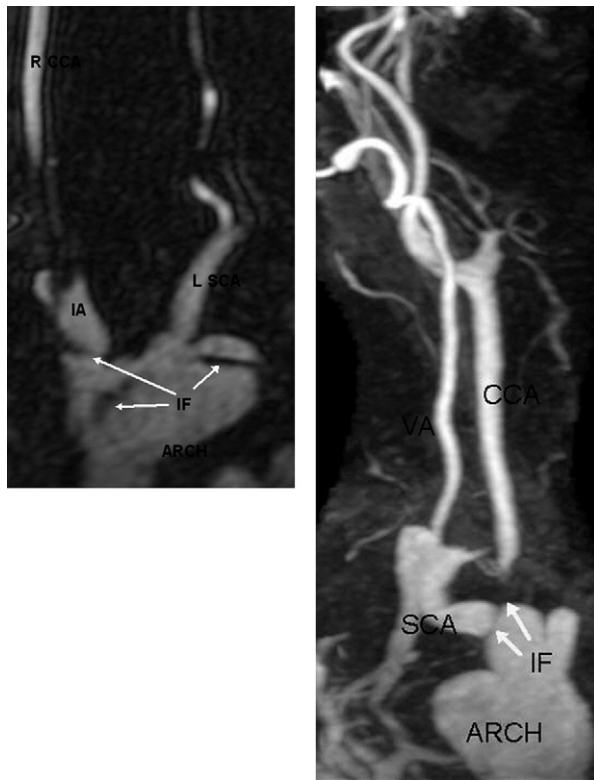


Fig 3. A, Magnetic resonance angiograph (MRA) of the aortic arch showing an intimal flap (IF) extending into the innominate artery and throughout the aortic arch. B, MRA showing an IF extending across the origins of the right subclavian and right carotid arteries. CCA, Common carotid artery; IA, innominate artery; IF, intimal flap; SCA, subclavian artery; VA, vertebral artery; R, right; L, left.

patients with proximal dissections, resulting in 6 completed strokes and 4 deaths, 3 of which could be directly attributed to the stroke. Overall, 8 of the 10 patients either died or had a permanent stroke. Despite these dismal results, no patient in the latter series had carotid revascularization. Fann et al²¹ found that only 3 of 7 patients with carotid malperfusion and a preoperative stroke who then underwent aortic repair recovered from their neurologic deficit.

Early attempts to reverse acute stroke with emergent carotid thromboendarterectomy in the 1960s and 1970s produced poor results, with stroke and death rates in excess of 40%.^{22,23} However, these results were all obtained before the advent of CT scanning, which has been shown to identify those patients who are likely to benefit from revascularization.²⁴⁻²⁶ More contemporary series have documented much improved results with acute carotid revascularization for stroke in the absence of a major infarct on CT scan.²⁷⁻³² Our decision to proceed with revascularization was based on the fact that the patient had a normal head CT scan and only small watershed infarcts on the MRI obtained after the development of hemiplegia. Recent trials using intravenous and/or intra-arterial infusions of tissue plas-

minogen activator to recanalize acute carotid occlusions causing acute stroke have produced similar results.³³⁻³⁸ These studies demonstrate that if recanalization of the internal carotid or middle cerebral artery can be achieved, neurologic outcomes are improved. In these studies, intracranial hemorrhage is a significant complication, and the benefit of revascularization is dependent on early revascularization (<3 hours).

Thrombotic occlusions primarily affect the internal carotid artery. Our patient had an acute dynamic occlusion of the common carotid artery, because there was some flow in the common carotid artery on duplex ultrasonography. This situation is probably more accurately represented by the experience with carotid artery trauma, which mostly consists of common carotid artery injuries. Reporting from the North Carolina Trauma Registry, Ramadan et al³⁹ found that the mortality of internal carotid injuries was twice that of common carotid injuries (21% vs 11%) and that the stroke rate was almost four times as high (41% vs 11%). In patients presenting with coma or neurologic deficit, mortality was 50% with no operation or carotid ligation vs 22% for carotid repair. Liekweg and Greenfield⁴⁰ found that 85% of patients with carotid injury and preoperative neurologic deficits had a successful outcome with revascularization, vs 50% with carotid ligation. Brown et al⁴¹ noted good outcomes in 14 of 19 patients who presented with neurologic deficits and underwent repair and noted especially good results in patients who presented with coma: 75% of patients who were revascularized had partial or complete clearing of coma, whereas 71% of patients treated with ligation died. The literature from carotid artery trauma thus seems to support revascularization.

Our patient was ischemic for 4 days before he was revascularized, but during this time he had at least some flow through his affected carotid system (10-20 cm/s on duplex scan), so presumably this flow protected his cerebral hemisphere. Even in cases of complete (static) common carotid artery obstruction, antegrade flow in the internal carotid artery is often maintained through reversal of flow in the external carotid artery. Another factor in his favor is that reperfusion was accomplished with purely mechanical means, so the patient was not exposed to the risks of bleeding associated with thrombolysis.⁴² Furthermore, one would expect the true lumen of his carotid system to be devoid of thrombus, thus minimizing the risk of embolization with recanalization of the true lumen, in contrast to recanalizing an atherosclerotic vessel that has experienced a thromboembolism.

Finally, there are long-term benefits to correcting malperfusion in a patient such as this, because the presence of persistent dissection in the arch vessels after aortic reconstruction is associated with neurologic events in the long term. Neri et al⁴³ reported on 42 patients with such chronic dissections. With a median follow-up of 3.2 years, they found that focal neurologic complications occurred in 31% of these patients, including major strokes in six patients (14%). Similarly, Zurbrugg et al⁴⁴ reported that 9 of 16 patients with chronic carotid dissection after aortic repair

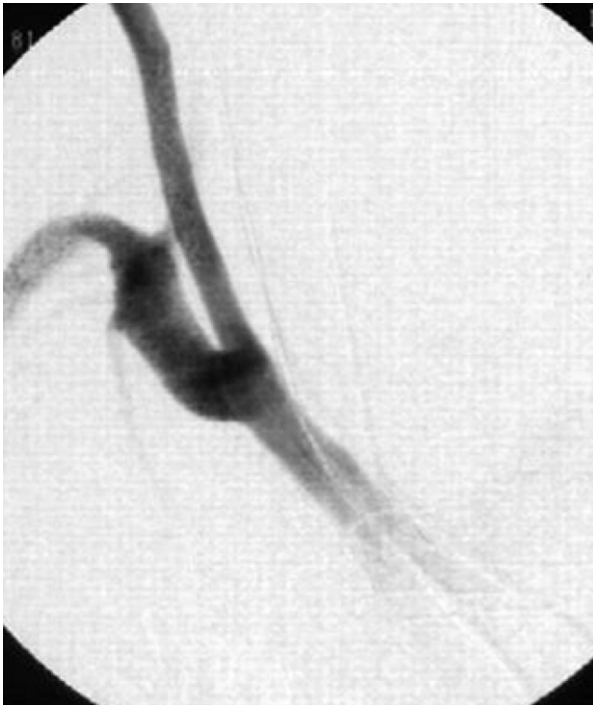

Fig 4. Intraoperative retrograde angiogram performed after placement of the second stent into the proximal innominate artery. Contrast now refluxes throughout the innominate artery.

experienced neurologic events but that only 1 patient had a major stroke.

Surgical revascularization of the carotid artery has been performed successfully with an extra-anatomic bypass to reverse an ischemic neurologic deficit 2 days before aortic reconstruction of a proximal dissection, as reported by Walterbusch

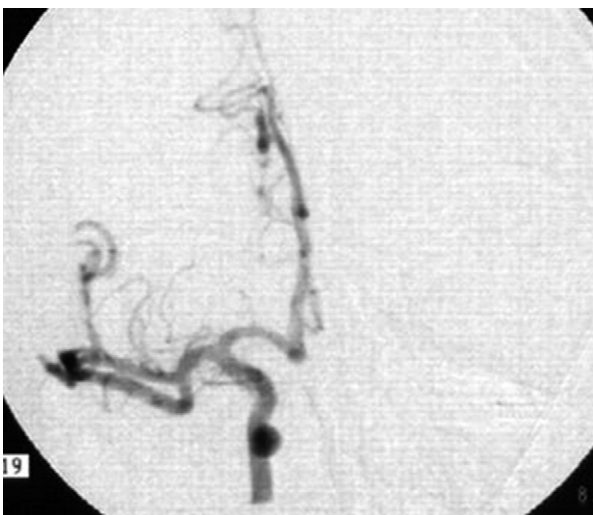

Fig 5. Intraoperative completion angiogram after transcrotid stenting, with good filling of both middle and anterior cerebral arteries.

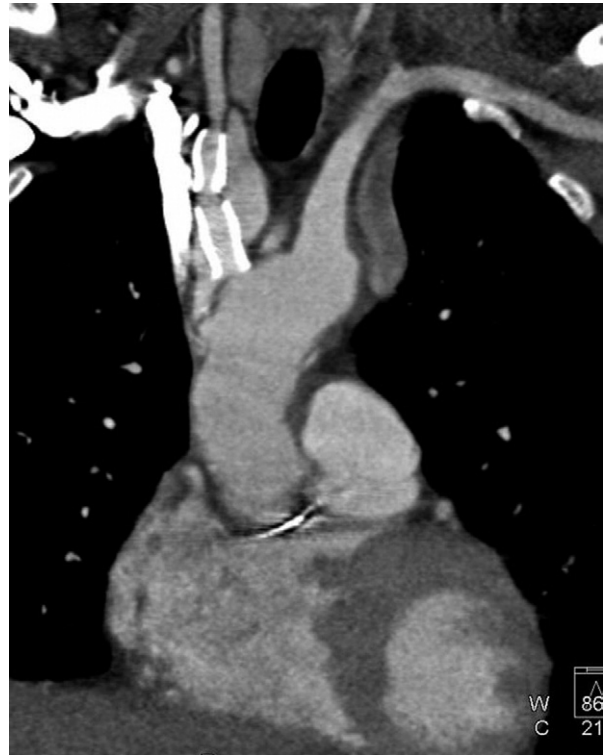

Fig 6. Computed tomographic angiogram 2.5 years after treatment showing patent stents in the innominate and right common carotid arteries.

et al.⁴⁵ Despite this report, the convention in the cardiac surgery community is to defer carotid revascularization before aortic reconstruction, because repair of the dissected membrane may correct the problem. Furthermore, there is concern that a hemorrhagic infarct may result from the anticoagulation used during aortic reconstruction.

On the basis of our experience with this patient, we would advocate that arch vessel stenting should be considered as a therapeutic option for revascularization of patients with symptomatic malperfusion of arch vessels in aortic dissection.

The authors thank Dr Elliot Fishman for his assistance in producing some of the radiographic images.

REFERENCES

1. Hagan PG, Nienaber CA, Isselbacher EM, Bruckman D, Karavite DJ, Russman PL, et al. The International Registry of Acute Aortic Dissection (IRAD): new insights into an old disease. *JAMA* 2000;283:897-903.
2. Cambria RP, Brewster DC, Gertler J, Moncure AC, Gusberg R, Tilson MD, et al. Vascular complications associated with spontaneous aortic dissection. *J Vasc Surg* 1988;7:199-209.
3. DeBakey ME, McCollum CH, Crawford ES, Morris GC, Howell J, Noon GP, et al. Dissection and dissecting aneurysms of the aorta—20-year follow-up of 527 patients treated surgically. *Surgery* 1982;92:1118-34.
4. Bachet J, Goudot B, Dreyfus GD, Brodaty D, Dubois C, Delentdecker P, et al. Surgery for acute type A aortic dissection: the Hopital Foch experience (1977-1998). *Ann Thorac Surg* 1999;67:2006-9.

5. Chirillo F, Marchiori MC, Andriolo L, Razzolini R, Mazzucco A, Gallucci V, et al. Outcome of 290 patients with aortic dissection. A 12-year multicentre experience. *Eur Heart J* 1990;11:311-9.
6. Fann JI, Smith JA, Miller DC, Mitchell RS, Moore KA, Grunkemeier G, et al. Surgical management of aortic dissection during a 30-year period. *Circulation* 1995;92:113-21.
7. Safi HJ, Miller CC III, Reardon MJ, Iliopoulos DC, Letsou GV, Espada R, et al. Operation for acute and chronic aortic dissection: recent outcome with regard to neurologic deficit and early death. *Ann Thorac Surg* 1998;66:402-11.
8. Sinatra R, Melina G, Pulitani I, Fiorani B, Ruvolo G, Marino B. Emergency operation for acute type A aortic dissection: neurologic complications and early mortality. *Ann Thorac Surg* 2001;71:33-8.
9. Svensson LG, Crawford ES, Hess KR, Coselli JS, Raskin S, Shenaq SA, et al. Deep hypothermia with circulatory arrest. Determinants of stroke and early mortality in 656 patients. *J Thorac Cardiovasc Surg* 1993;106:19-28.
10. Toda R, Moriyama Y, Masuda H, Iguro Y, Yamaoka A, Taira A. Organ malperfusion in acute aortic dissection. *Jpn J Thorac Cardiovasc Surg* 2000;48:545-50.
11. Trimarchi S, Nienaber CA, Rampoldi V, Myrmet L, Suzuki T, Mehta RH, et al. Contemporary results of surgery in acute type A aortic dissection: the International Registry of Acute Aortic Dissection experience. *J Thorac Cardiovasc Surg* 2005;129:112-22.
12. Williams DM, Brothers TE, Messina LM. Relief of mesenteric ischemia in type III aortic dissection with percutaneous fenestration of the aortic septum. *Radiology* 1990;174:450-2.
13. Walker PJ, Dake MD, Mitchell RS, Miller DC. The use of endovascular techniques for the treatment of complications of aortic dissection. *J Vasc Surg* 1993;18:1042-51.
14. Vedantham S, Picus D, Sanchez LA, Braverman A, Moon MR, Sundt T III, et al. Percutaneous management of ischemic complications in patients with type-B aortic dissection. *J Vasc Interv Radiol* 2003;14(2 Pt 1):181-94.
15. Slonim SM, Nyman U, Semba CP, Miller DC, Mitchell RS, Dake MD. Aortic dissection: percutaneous management of ischemic complications with endovascular stents and balloon fenestration. *J Vasc Surg* 1996;23:241-51.
16. Slonim SM, Miller DC, Mitchell RS, Semba CP, Razavi MK, Dake MD. Percutaneous balloon fenestration and stenting for life-threatening ischemic complications in patients with acute aortic dissection. *J Thorac Cardiovasc Surg* 1999;117:1118-26.
17. Deeb GM, Williams DM, Bolling SF, Quint LE, Monaghan H, Sievers J, et al. Surgical delay for acute type A dissection with malperfusion. *Ann Thorac Surg* 1997;64:1669-77.
18. Chavan A, Hausmann D, Dresler C, Rosenthal H, Jaeger K, Haverich A, et al. Intravascular ultrasound-guided percutaneous fenestration of the intimal flap in the dissected aorta. *Circulation* 1997;96:2124-7.
19. Beregi JP, Prat A, Gaxotte V, Delomez M, McFadden EP. Endovascular treatment for dissection of the descending aorta. *Lancet* 2000;356:482-3.
20. Lauterbach SR, Cambria RP, Brewster DC, Gertler JP, LaMuraglia GM, Isselbacher EM, et al. Contemporary management of aortic branch compromise resulting from acute aortic dissection. *J Vasc Surg* 2001;33:1185-92.
21. Fann JI, Sarris GE, Miller DC, Mitchell RS, Oyer PE, Stinson EB, et al. Surgical management of acute aortic dissection complicated by stroke. *Circulation* 1989;80:257-63.
22. Blaisdell WF, Clauss RH, Galbraith JG, Imparato AM, Wylie EJ. Joint study of extracranial arterial occlusion. IV. A review of surgical considerations. *JAMA* 1969;209:1889-95.
23. Mead GE, O'Neill PA, McCollum CN. Is there a role for carotid surgery in acute stroke? *Eur J Vasc Endovasc Surg* 1997;13:112-21.
24. Ricotta JJ, Ouriel K, Green RM, Deweese JA. Use of computerized cerebral-tomography in selection of patients for elective and urgent carotid endarterectomy. *Ann Surg* 1985;202:783-7.
25. Dosick SM, Whalen RC, Gale SS, Brown OW. Carotid endarterectomy in the stroke patient—computerized axial-tomography to determine timing. *J Vasc Surg* 1985;2:214-9.
26. Barber PA, Demchuk AM, Zhang JJ, Buchan AM. Validity and reliability of a quantitative computed tomography score in predicting outcome of hyperacute stroke before thrombolytic therapy. *Lancet* 2000;355:1670-4.
27. Gertler JP, Blankensteijn JD, Brewster DC, Moncure AC, Cambria RP, LaMuraglia GM, et al. Carotid endarterectomy for unstable and compelling neurologic conditions—do results justify an aggressive approach? *J Vasc Surg* 1994;19:32-42.
28. Rosenthal D, Borrero E, Clark MD, Lamis PA, Daniel WW. Carotid endarterectomy after reversible ischemic neurologic deficit or stroke—is it of value? *J Vasc Surg* 1988;8:527-34.
29. Berthet JP, Marty-Ane CH, Picard E, Branchereau P, Mary H, Veerapen R, et al. Acute carotid artery thrombosis: description of 12 surgically treated cases. *Ann Vasc Surg* 2005;19:11-8.
30. Kasper GC, Wladis AR, Lohr JM, Roedersheimer LR, Reed RL, Miller TJ, et al. Carotid thromboendarterectomy for recent total occlusion of the internal carotid artery. *J Vasc Surg* 2001;33:242-50.
31. Eckstein HH, Ringleb P, Dorfler A, Klemm K, Muller BT, Ziegelman M, et al. The Carotid Surgery for Ischemic Stroke trial: a prospective observational study on carotid endarterectomy in the early period after ischemic stroke. *J Vasc Surg* 2002;36:997-1004.
32. Gay JL, Curtin A, Buffiere S, Favre JP, Barral X. Urgent carotid artery repair: retrospective study of 21 cases. *Ann Vasc Surg* 2002;16:401-6.
33. The National Institute of Neurological Disorders and Stroke rt-PA Stroke Study Group. Tissue plasminogen activator for acute ischemic stroke. *N Engl J Med* 1995;333:1581-8.
34. Furlan A, Higashida R, Wechsler L, Gent M, Rowley H, Kase C, et al. Intra-arterial prourokinase for acute ischemic stroke: the PROACT II study—a randomized controlled trial. *JAMA* 1999;282:2003-11.
35. Lewandowski CA, Frankel M, Tomsick TA, Broderick J, Frey J, Clark W, et al. Combined intravenous and intra-arterial r-TPA versus intra-arterial therapy of acute ischemic stroke: Emergency Management of Stroke (EMS) bridging trial. *Stroke* 1999;30:2598-605.
36. Ernst R, Pancioli A, Tomsick T, Kissela B, Woo D, Kanter D, et al. Combined intravenous and intra-arterial recombinant tissue plasminogen activator in acute ischemic stroke. *Stroke* 2000;31:2552-7.
37. Hill MD, Barber PA, Demchuk AM, Newcommon NJ, Cole-Haskayne A, Ryckborst K, et al. Acute intravenous-intra-arterial revascularization therapy for severe ischemic stroke. *Stroke* 2002;33:279-82.
38. IMS Study Investigators. Combined intravenous and intra-arterial recanalization for acute ischemic stroke: the Interventional Management of Stroke study. *Stroke* 2004;35:904-11.
39. Ramadan F, Rutledge R, Oller D, Howell P, Baker C, Keagy B, et al. Carotid-artery trauma—a review of contemporary trauma center experiences. *J Vasc Surg* 1995;21:46-56.
40. Liekweg WG, Greenfield LJ. Management of penetrating carotid arterial injury. *Ann Surg* 1978;188:587-92.
41. Brown MF, Graham JM, Feliciano DV, et al. Carotid artery injuries. *Am J Surg* 1982;144:748.
42. Brott T, Broderick J, Kothari R, et al. Intracerebral hemorrhage after intravenous t-PA therapy for ischemic stroke. *Stroke* 1997;28:2109-18.
43. Neri E, Sani G, Massetti M, Frati G, Buklas D, Tassi R, et al. Residual dissection of the brachiocephalic arteries: significance, management, and long-term outcome. *J Thorac Cardiovasc Surg* 2004;128:303-12.
44. Zurbrugg HR, Leupi F, Schupbach P, Althaus U. Duplex scanner study of carotid artery dissection following surgical treatment of aortic dissection type A. *Stroke* 1988;19:970-6.
45. Walterbusch G, Oelert H, Borst HG. Restoration of cerebral blood-flow by extraanatomic bypass in acute aortic dissection. *Thorac Cardiovasc Surg* 1984;32:381-2.

Submitted Mar 9, 2006; accepted May 21, 2006.