

## Severe Bradycardia in a Stroke Patient Caused by a Single Low Dose of Escitalopram

Stefan Beyenburg Katharina Schönegger

Department of Neurology, Centre Hospitalier de Luxembourg, Luxembourg

Dear Sir,

Selective serotonin reuptake inhibitors as treatment for post-stroke depression are considered the state of the art, even though there are no recommendations on the right time to start the therapy or which substance to choose [1]. Escitalopram, the S-enantiomer of citalopram, is considered to be more effective in the treatment of depression than its racemic parent. Improvement of symptoms seems to start earlier than with citalopram [2]. Its tolerability profile is described as predictable, mild and transient. Main side effects are nausea, diarrhea, ejaculatory problems and insomnia [3]. Citalopram-associated bradycardia has been reported in overdose or long-term administration of therapeutic doses, especially in older patients [4–7]. To the best of our knowledge, severe bradycardia caused by a single small dose (5 mg) of escitalopram has not been described before.

### Case Report

A 60-year-old female patient was admitted to the stroke unit because of sudden-onset weakness of her left arm. Neurological examination showed a left brachiofacial hemiparesis. Her medical history included gastritis (treated with rabeprazole), currently untreated depression, and cardiovascular risk factors such as hyperlipidemia and cigarette smoking. She denied alcohol use and reported no allergies. Family history was unremarkable for stroke and heart disease. She was not tak-

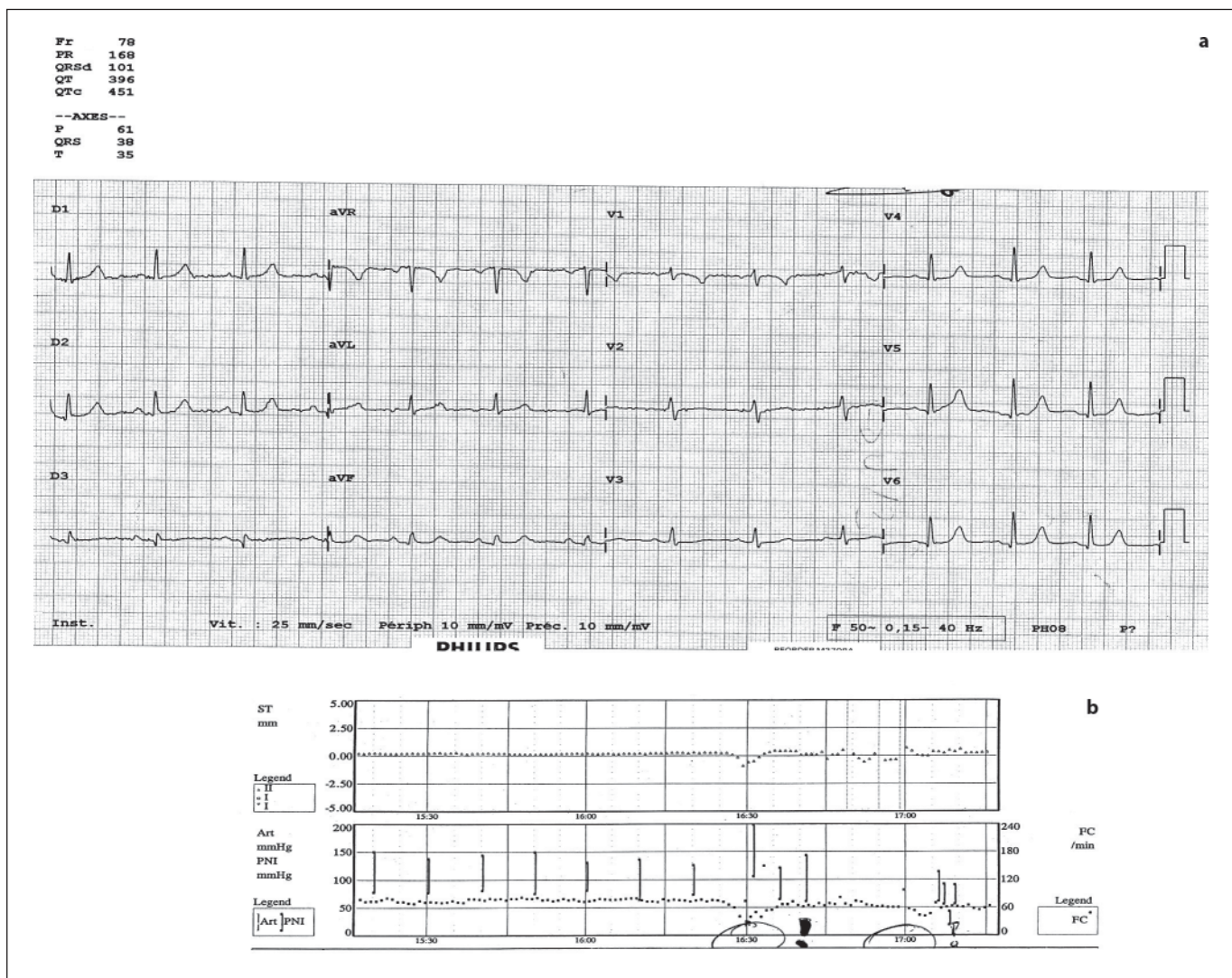
ing any medication. ECG at admission was normal, i.e. it did not demonstrate QT prolongation (fig. 1a). MRI confirmed an acute ischemic infarction of the right temporo-insular cortex. Doppler ultrasonography and cerebral angiography revealed a 90% stenosis of the left internal carotid artery and complete occlusion of the right internal carotid artery. The patient was known for depression that had significantly worsened after her stroke. Therefore anti-depressive treatment with escitalopram 5 mg was started on the third day post-stroke. Forty-five minutes after the first administration of escitalopram, a severe bradycardia (20–30 beats/min) with loss of consciousness and respiratory failure occurred (fig. 1b). Because of continuous monitoring in the stroke unit, the patient could be successfully reanimated in time. As a consequence of severe bradycardia the pre-existing cerebral hypoperfusion was enhanced, thereby increasing the deficit of cerebral perfusion in the area of brain infarction (controlled by follow-up MRI scans). Retrospectively, the patient remembered an episode of ‘dizziness and fainting’ in association with a single citalopram dose of 20 mg some years ago.

The exact cause of the life-threatening bradycardia in our patient remains obscure. It has been reported that involvement of the insular cortex in stroke may induce ECG abnormalities, increasing the risk for cardiac arrhythmia and death [8]. Not only lesions within the left insular re-

gion have been involved in mediating bradycardia but also right insular brain infarction may lead to a wide variety of arrhythmias [8]. Thus, location and size of infarct in our stroke patient may be considered as a contributing factor for the development of bradycardia. The mechanisms of ECG abnormalities caused by brain injuries are still unclear. Lesions within the insular cortex could play a major role in neurogenic origin of cardiac arrhythmias because of the widespread interconnections of that particular area with the limbic system and other areas of autonomic control [8].

It is also tempting to speculate about a certain predisposition to citalopram/escitalopram hypersensitivity. In addition to the serotonin transporter blockage, citalopram/escitalopram inhibit  $Ca^{2+}$ ,  $Na^{+}$  and  $K^{+}$  channels [9] and may therefore exhibit cardio-depressant effects in therapeutically useful concentrations. Whether the higher selectivity to the serotonin receptor of escitalopram is also linked to a higher inhibition of cardiac  $Ca^{2+}$ ,  $Na^{+}$  and  $K^{+}$  channels remains to be elucidated.

Whether comorbid cerebrovascular or cardiovascular disorders are a criterion for the choice of antidepressants still needs to be clarified [10]. Nevertheless, this case provides anecdotal evidence that caution is needed when treating stroke patients prone to cardiovascular side effects of SSRI with citalopram/escitalopram.



**Fig. 1. a** ECG on admission showing no major abnormalities. **b** Printout from the stroke unit demonstrating a severe drop in heart rate (20–30 beats/min) at 4.30 p.m.

*References*

- Carod-Artal FJ: Post-stroke depression. Part 2: Its differential diagnosis, complications and treatment (in Spanish). *Rev Neurol* 2006;42:238–244.
- Kennedy SH, Andersen HF, Lam RW: Efficacy of escitalopram in the treatment of major depressive disorder compared with conventional selective serotonin reuptake inhibitors and venlafaxine XR: a meta-analysis. *J Psychiatry Neurosci* 2006;31:122–131.
- Waugh J, Goa KL: Escitalopram: a review of its use in the management of major depressive and anxiety disorders. *CNS Drugs* 2003; 17:343–362.
- Barak Y, Swartz M, Levy D, Weizman R: Age-related differences in the side effect profile of citalopram. *Prog Neuropsychopharmacol Biol Psychiatry* 2003;27:545–548.
- Catalano G, Catalano MC, Epstein MA, Tsambiras PE: QTc interval prolongation associated with citalopram overdose: a case report and literature review. *Clin Neuropharmacol* 2001;24:158–162.
- Isbister GK, Bowe SJ, Dawson A, Whyte IM: Relative toxicity of selective serotonin reuptake inhibitors (SSRIs) in overdose. *J Toxicol Clin Toxicol* 2004;42:277–285.
- Isbister GK, Prior FH, Foy A: Citalopram-induced bradycardia and presyncope. *Ann Pharmacother* 2001;35:1552–1555.
- Abboud H, Berroir S, Labreuche J, Orjuela K, Amarenco P, GENIC Investigators: Insular involvement in brain infarction increases risk for cardiac arrhythmia and death. *Ann Neurol* 2006;59:691–699.
- Hamplova-Peichlova J, Krusek J, Paclt I, Slavicek J, Lisa V, Vyskocil F: Citalopram inhibits L-type calcium channel current in rat cardiomyocytes in culture. *Physiol Res* 2002; 51:317–321.
- Krishnan KR: Treatment of depression in the medically ill. *J Clin Psychopharmacol* 2005; 25(suppl 1):S14–S18.