

# Clinicopathological Conference: Case Report— A Case of Anorexia and Weak Arm

Jennifer L. Wiler, MD, MBA, Heatherlee Bailey, MD

## Abstract

The authors present the case of a 49-year-old female who presented to the emergency department with a chief complaint of “not eating well.” She was found to have a heart murmur, a focal neurological deficit, and large mitral valve vegetation. The patient was later diagnosed with acute *Pseudomonas* endocarditis with septic emboli to the brain, liver, spleen, and kidneys. A discussion of the patient presentation, diagnostic evaluation, and outcome are reviewed.

ACADEMIC EMERGENCY MEDICINE 2007; 14:95–99 © 2007 by the Society for Academic Emergency Medicine

**Keywords:** endocarditis, infective endocarditis, pseudomonas endocarditis

## CASE PRESENTATION

A 49-year-old African-American female presented to the emergency department (ED) with a chief complaint of “not eating well.” Neighbors had called 911 because the patient was “acting funny.” Paramedics found the patient lying in the hallway, incontinent of bowel and bladder, but with no obvious signs of trauma. Her main complaint was that she has had no appetite over the previous five days. She had subjective fevers, but denied chills or sweats. She denied any recent nausea, vomiting, or abdominal pain. She reported feeling subjectively weaker on the right side of her body, “especially my arm.” She stated at baseline that she was able to ambulate without assistance.

The remaining review of systems was negative. She denied any significant medical or surgical history and denied taking any daily medication. She denied any current drug use, but later conceded that she had “quit” using intravenous cocaine five days prior.

The patient was febrile and hypotensive; the vital signs were as follows: temperature, 102.4°F; pulse, 68 beats/min; respiratory rate, 20 breaths/min; blood pressure, 88/58; pulse oximetry on room air, 99%; and Accu-Chek (Roche Diagnostics, Indianapolis, IN) glucose of 186 mg/dL. On physical exam examination, she was noted

to be a disheveled, mildly obese woman, lying on the gurney in no apparent distress. She was sleepy but easily arousable and was slow to follow commands. Her head was atraumatic, with pale conjunctiva. Her pupils were reactive, with no obvious nystagmus. Her mucous membranes were dry, and no meningeal signs were elicited. Her lungs were clear. Her heart rate was regular. She was found to have a 4/6 systolic ejection murmur at the apex, with radiation to the axilla. Her pulses were palpable but slightly decreased in the lower extremities. She had a moderate pannus with decreased bowel sounds, but her abdomen was soft, nontender, with no appreciable masses. She was heme negative, with normal rectal tone. Her skin was warm, with multiple small healing lacerations on her legs.

Pertinent findings on her neurological examination were that she was alert and was oriented to person and place but not to time. Her cranial nerves were intact, but her reflexes were +1/4 in the lower extremities, with down-going toes. She was noted to have decreased spontaneous movement on the right side of her body. Her strength was +2/5 in the right shoulder, elbow, and wrist. She had no gross sensory deficits. The patient was unable to follow detailed commands; therefore, her cerebellar functioning and gait were not able to be accessed.

Laboratory testing revealed a white blood cell count of 30.3 cells/mm<sup>3</sup>; hemoglobin of 13.5 g/dL; platelets of 97 × 10<sup>3</sup> cells/mm<sup>3</sup>; and differential of 83% neutrophils, 9% bands, and 5% lymphocytes. Chemistry profile, coagulation studies, and urine microscopy were within normal limits. Blood and urine cultures were collected. An electrocardiogram from the ED was significant only for sinus tachycardia, with no evidence of coronary disease or acute ischemia. A head computed-tomography (CT) scan was read by emergency and radiology physicians as “no acute infarctions or hemorrhages.”

From the Department of Emergency Medicine, Drexel University College of Medicine (JLW, HB), Philadelphia, PA.

Received June 20, 2006; accepted June 27, 2006.

Series editor: James G. Adams, MD, Senior Associate Editor, *Academic Emergency Medicine*, Northwestern University Medical School, Chicago, IL.

Contact for correspondence and reprints: Jennifer L. Wiler, MD, MBA; e-mail: [jennifer\\_wiler@yahoo.com](mailto:jennifer_wiler@yahoo.com).

On the basis of a presumptive diagnosis, the appropriate treatment was initiated, a diagnostic test was ordered, and the appropriate consultants were notified.

## FACULTY DISCUSSION

This is a complex case with multiple positive findings. The key point is that the patient is “acting funny”; in other words, that she has a change in mental status. Altered mental status is a very broad category and not surprisingly has many mnemonics, such as “SMASHED2” and “TIPS AEIOU,” to aid physicians in not overlooking any differential diagnosis. The differential is quite varied, and to solve this case we must systematically narrow down the focus. To accomplish this potentially overwhelming task, one needs more data. The best place to obtain these facts is from the patient’s history and physical exam. Approximately 90% of all diagnoses can be made by being thorough, yet focused. This is one of the hallmarks of the emergency physician.

There are several important historical clues that potentially may help make the diagnosis. This illness appears to be subacute in nature, in that at least some of the symptoms have been present for five days. These include the subjective fever, poor appetite, and potentially the lack of substance abuse during that time frame. It is unclear, however, how long the arm weakness has been present, and how long the patient spent on the floor. For that matter, why is she on the floor? Her legs are not weak on exam. We are told that there is no obvious evidence of trauma. This would be helpful information, as well as why was the patient incontinent? Did she have a seizure, or was she just too weak and ill to get up? It also is important to remember that the patient is an active intravenous drug user (IVDU). This case points out that it is imperative not only to ask patients whether they ever have used illicit substances but if so, when they quit. The history alone does not immediately suggest a diagnosis. Broad categories to consider are an infectious etiology, a possible toxicologic process, or a neurological problem.

The patient’s physical exam also yields some potentially pertinent findings. The patient is febrile, dehydrated, and hypotensive. She is unkempt, not completely oriented, and slow to follow commands but has no evidence of trauma. There is a significant systolic ejection murmur. Her neurologic exam has focal findings with a right-sided motor defect, but sensation and, important to note, rectal tone are intact. The skin exam other than healing abrasions is normal, with no evidence of breakdown or stigmata of infection. This implies that she was not on the ground, at least in one position, for any significant length of time. The physical examination tells us that the patient is in shock. What type of shock might that be, and why? The possibility exists that it is from more than one source. Clearly the patient is hypovolemic and given the fever, possibly septic. Cardiogenic shock should not be excluded given the presence of a murmur. It is important to also consider neurogenic shock because of the focal neurologic findings.

Surprisingly, the laboratory data are relatively normal. We are not given a creatinine kinase (CK) value, but the patient is not in renal failure, which again implies that she did not spend a significant amount of time on the floor,

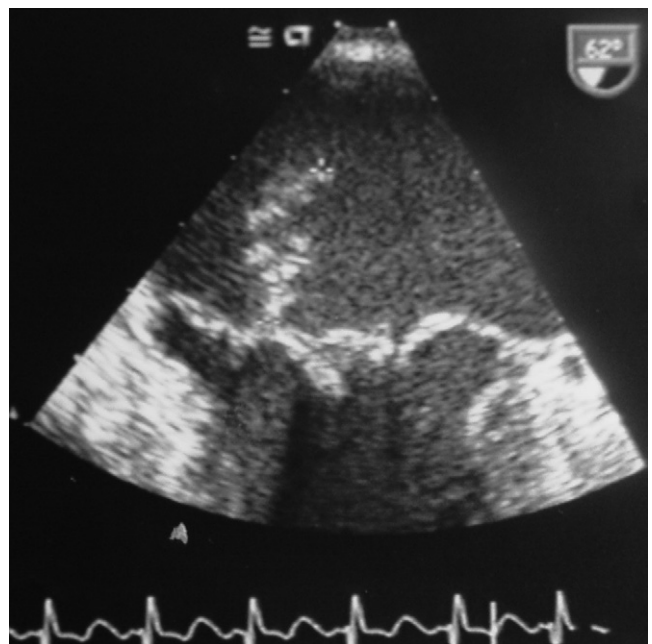
nor has she been hypotensive for a prolonged period of time. The one significant positive laboratory finding is that of a leukocytosis with a bandemia. This implies a probable infection or at least a significant stress to her system.

There are a few pertinent details that would be helpful to this case but that are not available. What is the patient’s immune status? The patient is an active IVDU, which places her at risk. Why and for how long was the patient on the floor? When did the neurologic deficit appear? How long has the cardiac murmur been present, and has it changed in character?

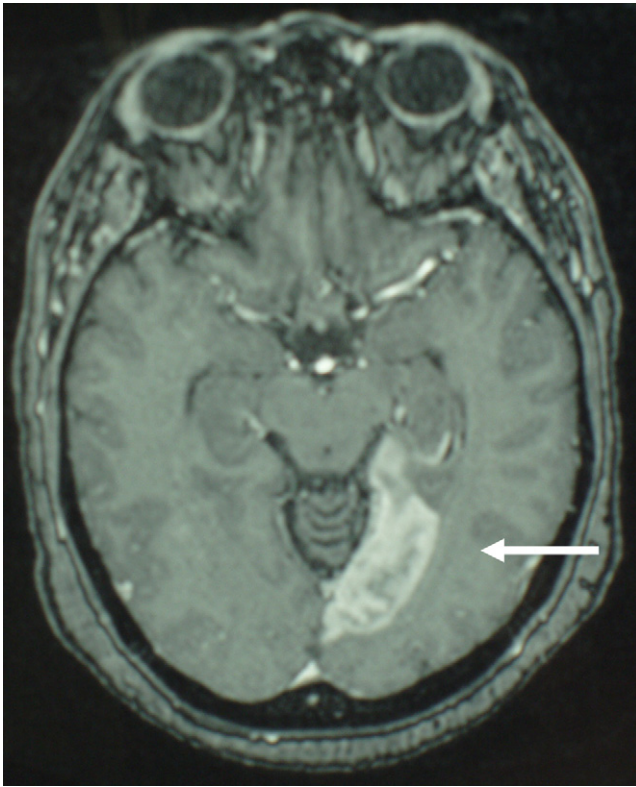
To help solve this, or any complicated case, many physicians apply the 14th-century concept of Ockham’s Razor, which states that entities should not be multiplied unnecessarily. Specifically in the field of medicine, a single diagnosis should initially be sought that can tie all of the pertinent findings together. In this case the combination of fever, altered mental status, and a neurologic deficit appear to point toward an infectious process.

Common infectious etiologies that should be considered are the following: meningitis; encephalitis; brain or spinal cord abscess with meningeal spread; opportunistic infections such as toxoplasmosis, progressive multifocal leukoencephalopathy, and cytomegalovirus; or septic emboli from brain, cardiac, or other sites. As mentioned previously, it is unclear what the patient’s immune status is. A rapid human immunodeficiency virus test, if available, potentially would be helpful in tailoring our treatment and diagnosis.

A good emergency physician always should know what to do for the patient even if the correct diagnosis is not readily apparent. In this case, this patient needs acute resuscitation with normotonic fluid and the implementation of the ED safety net of IV line, oxygen, and cardiac monitoring. An appropriate dose of acetaminophen should be given for fever. At least three sets of blood cultures from separate sites should be drawn. A CK level and lactate level should be added. A CT scan



**Figure 1.** Transesophageal echocardiogram from patient with large mitral-valve vegetation.



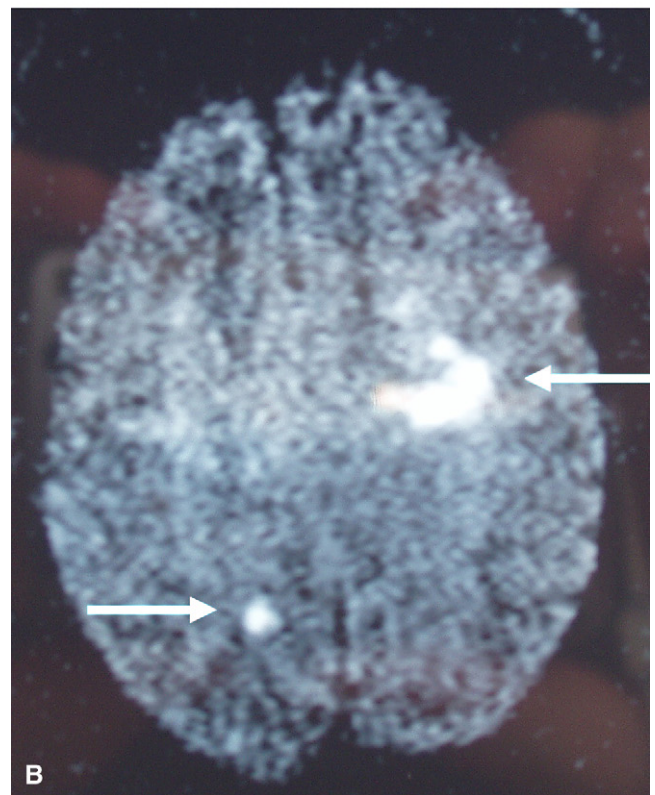
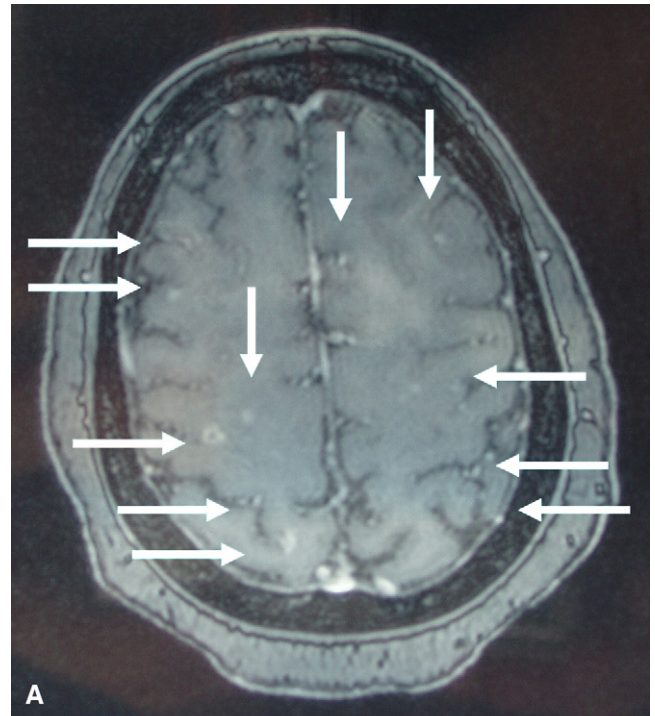
**Figure 2.** Magnetic resonance image of patient's brain. This view reveals a subacute left PCA infarction.

of the head should be ordered. If normal, a lumbar puncture should be considered. If available, a bedside transesophageal echocardiogram (TEE) also should be ordered. Once blood cultures are obtained, antibiotics should be administered to cover for endocarditis and meningitis. The appropriate critical-care service should be consulted for admission of this patient. Using the theory of Ockham's Razor, and the history and physical available, the most likely test to make the diagnosis in the ED would be a TEE to diagnose endocarditis.

### CASE OUTCOME

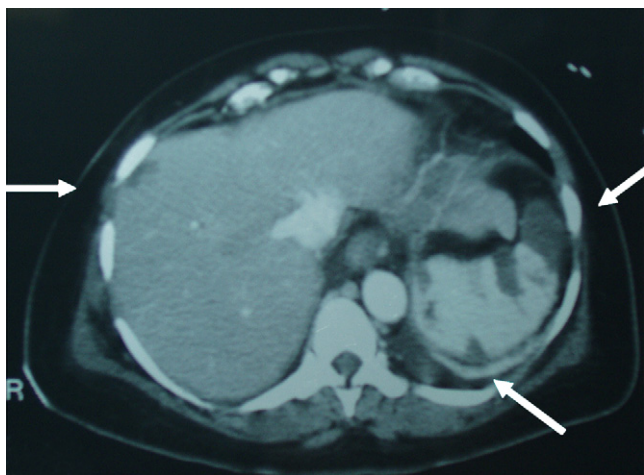
The presumptive diagnosis from the ED was acute infective endocarditis with septic emboli. Appropriate resuscitation, stabilization, and empiric antibiotics were initiated. A TEE was obtained, and the patient was admitted to the intensive care unit. The TEE revealed a large, 3-cm, multilobulated, mitral-valve vegetation with severe mitral regurgitation (Figure 1). Given this finding, and the patient's right upper-extremity weakness with an unremarkable head CT, a magnetic resonance image (MRI) was obtained (Figure 2). The MRI showed multiple acute and subacute infarctions in the hemispheres and cerebellum bilaterally.

Urine and blood cultures collected in the ED grew *Pseudomonas aeruginosa*, at which time antibiotics were appropriately tailored. Despite several days of the appropriate antibiotic therapy, the patient's blood cultures remained positive. She also developed a right facial droop, Janeway lesions on her feet, and splinter hemorrhages in her conjunctiva and right hand. For these reasons, a repeat brain MRI and magnetic resonance



**Figure 3.** Magnetic resonance image of patient's brain. (A) Post-contrast image of multiple small ring-enhancing lesions in areas of previous infarction, consistent with new microabscesses. (B) Diffusion-weighted image of new brain infarctions.

angiography (MRA) were performed on hospital day #5 (Figure 3A and B). The images revealed areas of new infarction and multiple small ring-enhancing lesions in areas of previous infarction, consistent with new



**Figure 4.** Abdominal CT demonstrating kidney infarctions and microabscesses.

microabscesses. The MRA showed two new small mycotic aneurysms.

The patient also developed splenomegaly, which prompted an abdominal CT. This study revealed multiple splenic abscesses, thought to be the source of her persistent bacteremia. Numerous liver and kidney infarctions also were seen, which were suspected to result from septic emboli (Figure 4). Thus, a splenectomy was performed on hospital day 10.

Blood cultures then became negative, and the mitral valve was radically repaired via annuloplasty on hospital day 21. Shortly thereafter, the patient was discharged home, where she completed six weeks of antibiotic therapy. She continued to have a residual right-arm weakness but regained most of her previous activities of daily living.

## RESIDENT DISCUSSION

Although this patient presented with a subjective complaint of anorexia, many elements of her history and physical examination led to the accurate diagnosis. This patient presented the ED with a change in mental status, fever, heart murmur, and a focal neurological deficit. She was also a known IV drug user. This led to a presumptive diagnosis in the ED of acute infective endocarditis with septic emboli, which was verified by the identification of a large mitral-valve vegetation by TEE and multiple brain infarctions on MRI.

Infective endocarditis is a microbial infection of the endocardial surface tissue. It can be classified as acute or subacute on the basis of the chronicity and severity of the clinical presentation and of the progression of the untreated disease.<sup>1</sup> A patient with acute endocarditis usually is toxic appearing. Valve damage occurs rapidly and extracardiac organs are seeded by hematogenous spread. Left untreated, endocarditis can progress to death within weeks. Subacute endocarditis follows a more indolent course, causing less structural cardiac damage, and infrequently involves other systemic organs.

**Table 1**  
Modified Duke Criteria for the Diagnosis of Infective Endocarditis (IE)

Criteria	Symptoms
<b>Major</b>	
Positive blood culture for IE	Typical microorganisms consistent with IE from two separate blood cultures: viridans streptococci, <i>Streptococcus bovis</i> , or HACEK group or Community-acquired <i>Staphylococcus aureus</i> or enterococci without a primary focus or Microorganisms consistent with IE from persistently positive blood cultures or Single positive blood culture of <i>Coxiella burnetii</i>
Evidence of endocardial involvement	Positive echocardiogram or New valvular regurgitation (worsening or changing of preexisting murmur not sufficient)
<b>Minor</b>	
Predisposition to IE	Predisposing heart condition or Intravenous drug use
Fever	Temperature > 38.0°C (100.4°F)
Vascular phenomena	Major arterial emboli, septic pulmonary infarcts, mycotic aneurysm, intracranial hemorrhage, conjunctival hemorrhages, and Janeway lesions
Immunologic phenomena	Glomerulonephritis, Osler's nodes, Roth spots, and rheumatoid factor
Microbiological evidence	Positive blood culture that does not meet a major criterion as noted above, or serological evidence of active infection with organism consistent with IE

Adapted from Li et al.<sup>4</sup>

Table 2  
Key Teaching Points

- Patients with endocarditis do not always have a heart murmur.
- Fever and heart murmur in an intravenous drug user is endocarditis until proven otherwise.
- There are many possible presentations of septic emboli from a valvular vegetation.

It is thought that damaged endocardial tissue is predisposed to deposition of fibrin and platelets. The resulting thrombus then is susceptible to seeding during normal transient episodes of bacteremia.<sup>2</sup> Many microorganisms, including bacteria and fungi, can infect the endocardial tissue. The most common pathogenic organism isolated in infective endocarditis is *Staphylococcus aureus*.<sup>1</sup> Interestingly, in this case, *P. Aeruginosa* was identified in blood and urine cultures. Today, gram-negative bacilli are responsible for 5.3% to 12% of endocarditis cases, and *P. aeruginosa* is present in 30% to 50% of these cases.<sup>3</sup> Although most patients who develop endocarditis have a history of either underlying cardiac valvular disease or IVDU, as many as 30% of patients have no known underlying risk factors.<sup>2</sup>

The modified Duke's Criteria currently are used to diagnose endocarditis (Table 1).<sup>4</sup> This is divided into major and minor criteria. Major criteria include identification of common microorganisms by blood culture (i.e., *Streptococcus viridans*, HACEK group [*Haemophilus* species including *H. parainfluenzae*, *H. aphrophilus*, and *H. paraphrophilus*; *Actinobacillus actinomycetemcomitans*, *Cardiobacterium hominis*, *Eikenella corrodens*, and *Kingella* species], *Streptococcus bovis*, *S. aureus*, etc.) and evidence of endocardial involvement. Minor criteria take into consideration a patient's risk factors and identification of stigmata consistent with endocarditis.<sup>1,2</sup> They also include the identification of a heart murmur, which is present in approximately 83% of patients with endocarditis.<sup>5</sup> The diagnosis is considered definite if two major criteria, one major and three minor criteria, or five minor criteria are fulfilled.<sup>6</sup>

The classic peripheral stigmata of endocarditis are found in as many as 50% of patients<sup>7</sup>; these include splinter hemorrhages (linear red or brown lesions seen under the fingernails or toenails), Osler's nodes (tender subcutaneous nodules often found in the pulp of the digits or the thenar eminences), and Janeway's lesions (painless, flat, erythematous, hemorrhagic, or pustular lesions often found on the palms or soles). Roth spots are a rare finding observed in less than 5% of patients.<sup>8</sup> These are retinal hemorrhages with small pale centers.

There are many potential complications of endocarditis. However, congestive heart failure, peripheral emboli, and neurologic events have the greatest influence on patient's prognosis. Systemic emboli occur in up to 50% of cases.<sup>6</sup> This can result in embolic stroke, mycotic aneurysms, or emboli to the visceral organs or vasculature. Most commonly, the spleen, liver, kidney, iliac, and mesenteric arteries are involved.<sup>1</sup>

The treatment of endocarditis typically requires organism-directed antibiotic therapy for four to six weeks. Antibiotics alone are insufficient for some organisms, such as *Pseudomonas*, as is illustrated by this case, which

typically requires surgical intervention.<sup>6</sup> Studies have shown that prompt cardiac-valve replacement and aggressive antibiotic therapy provide the best opportunity for successful treatment of this virulent organism.<sup>9</sup>

The overall mortality rates for endocarditis remain as high as 20%–25%, with death resulting primarily from central nervous system embolic events and hemodynamic deterioration.<sup>1</sup> Several factors affect a patient's chance of survival, including the presence of complications, pre-morbid conditions, and the causative microorganism. The mortality rate for *Pseudomonas* endocarditis is greater than 50%.<sup>1</sup>

The incidence of endocarditis continues to rise, with 15,000–20,000 new cases identified each year. Infective endocarditis now is the fourth leading cause of life-threatening infectious-disease syndromes in the United States after urosepsis, pneumonia, and intra-abdominal sepsis.<sup>6</sup> The ability to skillfully diagnosis and treat infective endocarditis is critical for all emergency physicians (Table 2).

## FINAL DIAGNOSIS

Acute *Pseudomonas* endocarditis with septic emboli to the brain, liver, spleen, and kidneys.

The authors thank The Council of Emergency Medicine Residency Directors, the Society for Academic Medicine, and The Emergency Medicine Residents Association for the opportunity to present this case, and thank Yasuharo Okuda, MD, Mount Sinai Hospital, for his significant contribution and presentation as the original case discussant.

## References

1. Mylonakis E, Calderwood SB. Infective endocarditis in adults. *N Engl J Med*. 2001; 345:1318–30.
2. Murtagh B, Frazier OH, Letsou GV. Diagnosis and management of bacterial endocarditis in 2003. *Curr Opin Cardiol*. 2003; 18:106–10.
3. Saraiva RM, Camillis LF, Francisco RM, Gomes MV. Isolated pulmonary valve *Pseudomonas aeruginosa* endocarditis related to catheter embolism. *Int J Cardiol*. 2002; 83(1):83–4.
4. Li JS, Sexton DJ, Mick N, et al. Proposed modifications to the Duke criteria for the diagnosis of infective endocarditis. *Clin Infect Dis*. 2000; 30:633–8.
5. Todd AJ, Leslie SJ, Macdougall M, Denvir MA. Clinical features remain important for the diagnosis of infective endocarditis in the modern era. *QJM*. 2006; 99:23–31.
6. Bayer AS, Bolger AF, Taubert KA, et al. Diagnosis and management of infective endocarditis and its complications. *Circulation*. 1998; 98:2936–48.
7. Henneman PL. Infective Endocarditis. Principles and Practice of Emergency Medicine. 4th ed. Philadelphia, PA: Lippincott Williams and Wilkins, 1999.
8. Cunha VG, Lazar J. Acute infective endocarditis. Diagnostic and therapeutic approach. *Infect Dis Clin North Am*. 1996; 10:811–31.
9. Weiland M, Lederman M, Kline-King C, et al. Left-sided endocarditis due to *Pseudomonas aeruginosa*: a report of 10 cases and review of the literature. *Medicine*. 1986; 65:180–9.