

Zvi Ram, M.D.

Department of Neurosurgery,
Tel Aviv Sourasky Medical Center,
Tel Aviv, Israel

Zvi R. Cohen, M.D.

Department of Neurosurgery,
Sheba Medical Center,
Tel Hashomer, Israel

Sagi Harnof, M.D.

Department of Neurosurgery,
Sheba Medical Center,
Tel Hashomer, Israel

Sigal Tal, M.D.

Department of Radiology,
Sheba Medical Center,
Tel Hashomer, Israel

Meir Faibel, M.D.

Department of Radiology,
Sheba Medical Center,
Tel Hashomer, Israel

Dvora Nass, M.D.

Department of Pathology,
Sheba Medical Center,
Tel Hashomer, Israel

Stephan E. Maier, M.D.

Department of Radiology,
Brigham and Women's Hospital,
Harvard Medical School,
Boston, Massachusetts

Moshe Hadani, M.D.

Department of Neurosurgery,
Sheba Medical Center,
Tel Hashomer, Israel

Yael Mardor, Ph.D.

Advanced Technology Center,
Sheba Medical Center,
Tel Hashomer, Israel;

Reprint requests:

Zvi Ram, M.D.,
Department of Neurosurgery,
Tel Aviv Sourasky Medical Center,
6 Weizman Street,
Tel Aviv 64239, Israel.
Email: zviram@inter.net.il

Received, December 19, 2005.

Accepted, March 7, 2006.

MAGNETIC RESONANCE IMAGING-GUIDED, HIGH-INTENSITY FOCUSED ULTRASOUND FOR BRAIN TUMOR THERAPY

OBJECTIVE: Magnetic resonance imaging-guided high-intensity focused ultrasound (MRigFUS) is a novel technique that may have the potential for precise image-guided thermocoagulation of intracranial lesions. The system delivers small volumetric sonications from an ultrasound phased array transmitter that focuses energy selectively to destroy the target with verification by magnetic resonance imaging-generated thermal maps. A Phase I clinical study was initiated to treat patients with recurrent glioma with MRigFUS.

METHODS: To date, three patients with histologically verified recurrent glioblastoma multiforme have been treated with MRigFUS. All patients underwent craniectomy 7 to 10 days before therapy to create a bony window for the ultrasound treatment. Sonications were applied to induce thermocoagulation of the enhancing tumor mass. Long-term radiological follow-up and post-treatment tissue specimens were available for all patients.

RESULTS: MRigFUS treatment resulted in immediate changes in contrast-enhanced T1-, T2-, and diffusion-weighted magnetic resonance imaging scans in the treated regions with subsequent histological evidence of thermocoagulation. In one patient, heating of brain tissue in the sonication path resulted in a secondary focus outside the target causing neurological deficit. New software modifications were developed to address this problem.

CONCLUSION: In this first clinical report, MRigFUS was demonstrated to be a potentially effective means of destroying tumor tissue by thermocoagulation, although with an associated morbidity and the inherent invasive nature of the procedure requiring creation of a bone window. A modified technology to allow MRigFUS treatment through a closed cranium is being developed.

KEY WORDS: Brain tumors, Focused ultrasound, Magnetic resonance imaging

Neurosurgery 59:949-956, 2006

DOI: 10.1227/00006123-200605000-00000

www.neurosurgery-online.com

Thermal ablation of tumors has been attempted over the years using a variety of technologies, including radiofrequency, laser, microwave, and ultrasound. Recent advances in magnetic resonance imaging (MRI) allow for coupling the thermal ablative platforms with precise guiding capabilities to selectively and precisely target the desired tumor volume. Furthermore, the ability to generate MRI-derived temperature mapping of the target tissue enables noninvasive monitoring of the ablative procedure with accurate detection of threshold temperature rises required for irreversible tumor tissue destruction (9).

MRI-guided high-intensity focused ultrasound (MRigFUS) is a novel technique that allows for precise, MRI-guided targeting of an intracranial lesion and delivering of an ultrasonic beam to destroy the lesion selectively by ultrasound-induced thermocoagulation.

Various MRigFUS methods have been developed in recent years. The ExAblate 2000 system is the result of a 10-year development program by InSightec (Haifa, Israel) and GE Healthcare (Milwaukee, WI) using the unique interactive scan control features of the GE SIGNA MR iDrive. The ExAblate 2000 system drives the MRI scanner to provide real-time

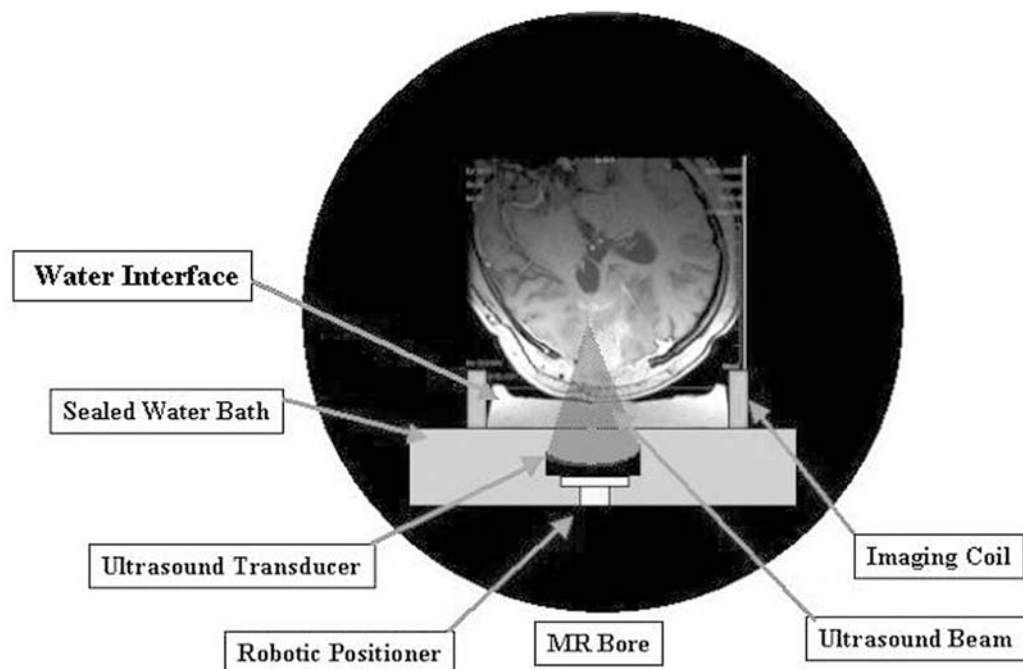


FIGURE 1. Diagram demonstrating the ExAblate 2000 system schematic setup for brain treatments. MR, magnetic resonance.

therapy planning, thermal dosimetry, and closed-loop therapy control.

The focused ultrasound device is embedded within the MRI table on which the patient is placed in the MRI magnet (Fig. 1). Inside the MRI table, there is a sealed water bath with an ultrasonic transducer. The patient is positioned with the craniotomy on top of the water bath. Treatment starts with the physician using the conventional MRI scans, displayed on the ExAblate computer, to determine the regions of interest of the target volume. The ExAblate computer uses the physician's input to plan the optimal coverage of the target region, consisting of a cluster of sonication volumes. Each sonication volume is treated after the physician confirms the system parameters. Essentially, the beam path is reviewed to assure that it is directed through the craniotomy. The set of sonication volumes are applied sequentially to cover the entire planned target volume. During the treatment, temperature maps (a set of MRI scans in which the contrast reflects the change in temperature in relation to the first acquired image) are acquired continuously. The thermal maps are used to calculate thermal dose maps, in which the energy deposition in the tissue is calculated from the temperature changes and their duration. Pixels reaching predefined thresholds are displayed in different colors in the final dose maps, providing the treatment volume to confirm the therapeutic effect. The thermal maps are used to monitor the treatment in progress and to confirm that the ablation is going according to plan, thus closing the therapy loop.

The ExAblate 2000 recently gained approval by the Food and Drug Administration to treat uterine fibroids and is currently under investigation for additional indications, such as breast

and hepatic cancers (4, 5). Such lesions are currently being treated using alternative technologies, such as radiofrequency ablation. However, MRIGFUS may prove to be superior because the studies in uterine fibroids have demonstrated the selectivity and safety of the procedures with histopathological correlates for the observed radiological findings during MRIGFUS treatments.

The ability of ablating brain tumor tissue has been shown in numerous studies using heat generated by laser, radiofrequency energy, and focused ultrasound technologies (3, 8, 9, 13). These and other studies have shown the technology to be accurate and controlled reliably by MRI in animals and humans, using hyperthermia for various

body regions (4, 5, 14).

Extensive preclinical evaluation of the application of MRIGFUS in the brain was conducted in pigs. These studies have validated the precision of the system and the reproducible capability to produce brain lesions at the desired regions (10). In this report, we describe our preliminary experience in using the ExAblate 2000 MRIGFUS system for the treatment of recurrent malignant glioma in three patients. At this stage, a bony window must be formed in the patient's cranium to enable efficient and precise transfer of the ultrasound energy and to avoid complex problems, such as deflection of the ultrasound waves and energy absorption by the cranium. This is an initial phase of an elaborate development program to target brain tumors through an intact cranium. Such a device was recently approved by the Food and Drug Administration for clinical trials, and a clinical study is currently active.

PATIENTS AND METHODS

Study Design

The study was designed as a Phase I/II open-label, prospective study aimed at evaluating the safety and efficacy of MRIGFUS-induced thermocoagulation of recurrent malignant gliomas.

Patients

The study was approved by the institutional ethical committee and the Ministry of Health of the State of Israel. All patients signed an informed consent before enrollment. Patients with

histologically confirmed recurrent glioblastoma multiforme (GBM) with a measurable and quantifiable enhancing tumor on MRI scans and who have not received radiation therapy during the 6 weeks before enrollment or chemotherapy 4 weeks before enrollment were considered eligible. Tumors in the frontal and anterior temporal regions were excluded because of the physical constraints of the ExAblate system (i.e., the need for the patients to lie on their backs on the MRI table). Tumor volumes were calculated with a standard MRI software application using contouring of the enhancing tumor mass on contiguous MRI slices. To date, a total of three patients have been enrolled. The individual descriptions for each patient are described below.

Surgical Procedures

Seven to 10 days before MRIGFUS treatment, patients underwent a standard craniectomy over the tumor area to create the bony window necessary for penetration of the ultrasound waves. This was carried out by removal of the bone flap used in previous operations for tumor resection. Biopsy of the tumor was obtained as part of the procedure. Before skin closure, the wound was irrigated with a copious amount of water to prevent residual bony fragments or entrapment of air that may interfere with effective transfer of the ultrasonic energy. One dose of perioperative antibiotics (cefuroxime, 1.5 g) was used in all patients.

MRIGFUS Treatment

After general anesthesia was induced, MRIGFUS treatment took place in the MRI suite (1.5-T GE Signa Excite) with the patient's head placed on top of the MRIGFUS-compatible coil. No contrast agent was administered. Targeting was performed using coregistration of T2-weighted, diffusion-weighted (line scan), and contrast-enhanced T1-weighted MRI scan (acquired 24 h before treatment), with a pretreatment MRI scan acquired at the beginning of the therapeutic MRIGFUS session. MRIGFUS treatment was composed of the following steps.

Patient Positioning

MRI scans were acquired to verify that the MRIGFUS transducer was located below the craniectomy site. Pretreatment contrast-enhanced T1-weighted images were registered to the intraprocedural images to allow easy identification of the tumor using an intensity mapping technique. The operator verified that the tumor region was reachable by the MRIGFUS transducer through the craniectomy window. Accurate patient positioning was maintained using a standard radiation mask fitted at the time the planning MRI scans were obtained (typically 1 d before MRIGFUS treatment).

Planning Stage

The system automatically computed a tentative treatment plan composed of multiple sonications. The set of sonication volumes is a result of thermoacoustic simulation that predicts the expected volume to be coagulated in each sonication. These

sonication volumes are then packed tightly to fill the target volume delineated by the physician. The automatic plan is reviewed and edited by the physician. Sonication volumes may be added, removed, or repositioned to provide adequate coverage of the target region. For each sonication, various parameters, such as the optimal power, duration, and direction of the beam path suggested by the software and modified by the operator as deemed appropriate, were determined.

Verification Stage

The first several sonications were performed using noncoagulating low-power (up to 45°C for up to 3 s) values at a central location in the target region to verify the correct targeting and accurate operation parameters.

Treatment Stage

The system produced one sonication after another until all planned sonications were executed. Pulse duration ranged from 12 to 20 seconds, resulting in maximal temperature elevations between 60 and 90°C at the target volume. The desired threshold temperature elevations and duration needed to irreversibly coagulate the target tissue were derived from previous animal experiments in the pig brain (10). During sonications, thermal MRI maps were generated continuously. These were used to create a thermocoagulation image showing which regions were coagulated successfully. As a safety measure, a pause between sonications (average duration, 120 s) was allowed for tissue cooling to baseline body temperature. The sonication process is fully controlled by the physician and is not automatic. Each sonication is reviewed and can be activated only by a specific command. During the sonication, the physician may abort the procedure if any undesired effects are detected.

Post-treatment Imaging

On completion of the treatment phase, a new set of T2-weighted, diffusion-weighted, and contrast-enhanced T1-weighted MRI scans were acquired to assess the effect of MRIGFUS treatment on the tumor and adjacent brain regions.

Patient Assessment

Patients were observed in the neurosurgical intensive care unit for 5 days after MRIGFUS treatment, where routine physical and neurological examinations were performed on a daily basis. MRI scans were performed before treatment and on a daily basis for the first 5 days after treatment, and then on a monthly basis.

Additional Evaluations

Tumor specimens were obtained in all three patients at variable time points after treatment (2–12 mo after MRIGFUS), when a surgical intervention was indicated on clinical grounds. Pathological sections of tumor specimens were analyzed using standard hematoxylin and eosin staining.

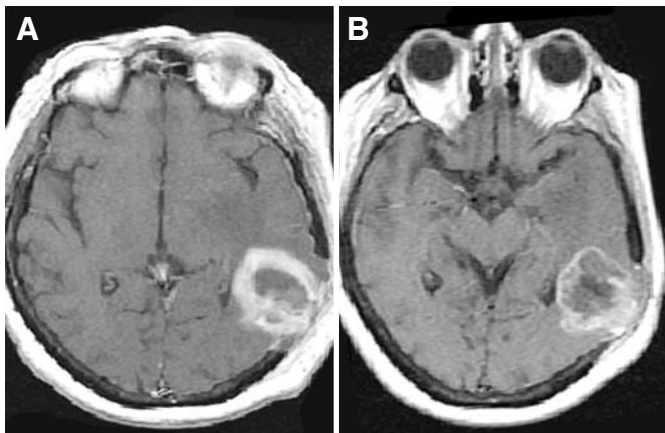


FIGURE 2. Enhanced T1-weighted MRI scans obtained from Patient 2 before (A) and after (B) MRIgFUS treatment. Note the loss of enhancement at the treated site.

RESULTS

Illustrative Cases

Patient 1

A 65-year-old man was diagnosed in February 2002 with a right mesiotemporal GBM. The patient underwent gross total removal of the tumor followed by standard focal radiation therapy (60 Gy). Four months later, he experienced seizures and left hemiparesis; MRI examination showed local tumor recurrence. Another craniotomy was performed for tumor resection, and Gliadel wafers (Rhône-Poulenc Rorer Pharmaceuticals, Collegeville, PA) were implanted in the resection cavity. The patient was treated for a postoperative brain abscess 3 weeks later, at which time the bone flap was removed. In February 2003, tumor recurrence was noted again, and the patient was enrolled in the MRIgFUS study. The tumor volume was 9 cm³ (5). Stereotaxic biopsy was carried out to confirm the presence of active tumor, and treatment through the existing bone defect was performed consisting of 32 sonications. Although phase temperature elevations were observed in the tumor during the treatment, no effective thermocoagulation was achieved because of energy absorption by a synthetic dural substitute (Neuropatch; Aesculap, Tuttlingen, Germany) used during previous operations. This phenomenon was subsequently verified in a phantom model (data not shown) that showed the dura substitute to contain tiny air bubbles that prohibited the ultrasound energy from passing through the material. No radiological changes were detected in the post-treatment MRI examinations. The patient later received additional tumor resection and chemotherapy and has shown improvement of his symptoms until reaching a stable performance status (Karnofsky Performance Scale score, 60–70) with no evidence of clinical tumor progression as of January 2006 (38 mo after MRIgFUS treatment).

Patient 2

A 64-year-old woman was diagnosed with a left temporoparietal GBM in October 2002, manifesting with mixed sensorimotor dysphasia. The patient underwent gross total tumor resection followed by a standard radiation course (60 Gy). Tumor recurrence was diagnosed in February 2003, and the patient was enrolled in the MRIgFUS study. Tumor volume was 25 cm³, and the initial treatment plan was limited to only a part of the tumor.

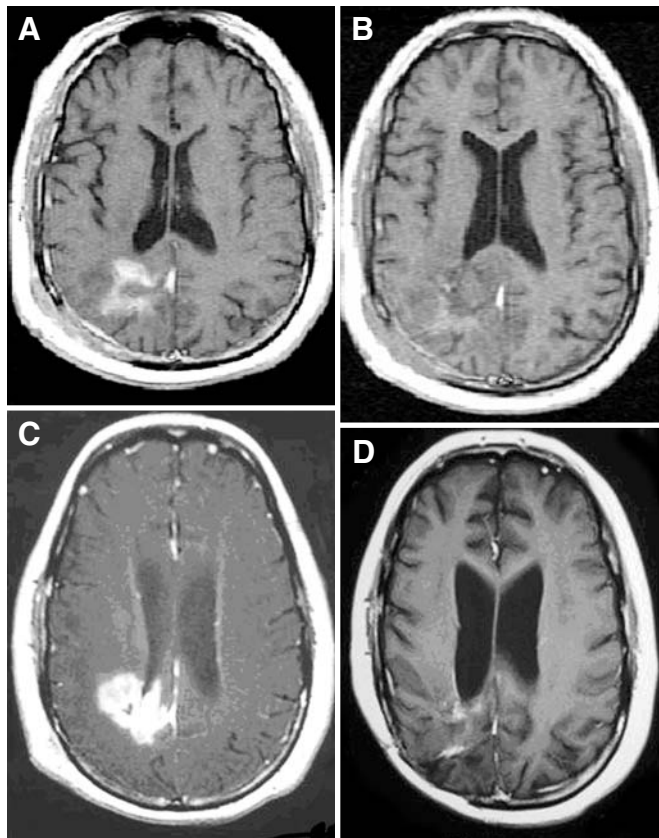


FIGURE 3. Enhanced T1-weighted MRI scans obtained from Patient 3 before (A) and after (B) MRIgFUS treatment. Note the loss of enhancement at the treated site. T1-weighted MRI scans obtained from Patient 3 showing the new enhancing lesion at the treated site 4 months after treatment (C) and several months later (D) showing spontaneous resolution of the enhancing mass.

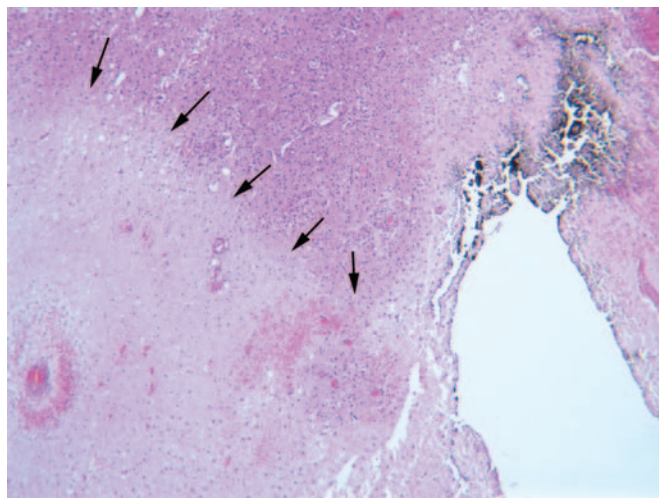


FIGURE 4. Low-power photomicrograph of the resected tumor of Patient 2 showing the coagulative necrosis in a sonication spot (arrows; hematoxylin and eosin; original magnification, $\times 100$).

On February 10, 2003, the patient underwent removal of the bone flap to create the bony window for MRIGFUS and 10 days later underwent the MRIGFUS treatment of approximately 50% of her tumor volume (Figs. 2 and 3). A total of 35 sonications were used. Post-treatment imaging revealed significant tumor response manifested as resolution of enhancement of the treated volume in the contrast-enhanced T1-weighted images and significant new enhancement on diffusion-weighted MRI (DWMRI) scans.

No significant radiologically or clinically adverse events were noted, apart from a mild transient worsening of her preexisting dysphasia that improved with steroid therapy. Follow-up MRI scans (2 wk later) showed the persistence of loss of enhancement at the treated site and relaxation of the enhancement in the DWMRI scans.

The patient was scheduled for a second treatment cycle for the remaining untreated tumor. However, pretreatment simulation suggested that not all of the tumor volume could be targeted because of limited accessibility through the craniectomy window, and the patient underwent another surgical procedure for tumor resection. Histological analysis showed sharp delineation between viable tumor and thermo-coagulated tumor at the treated site (Fig. 4) that was cylindrical and differed from typical tumor necrosis seen in regions of viable tumor. The patient made an uneventful recovery, but 9 months later showed evidence of tumor progression and died of her disease 10 months after the MRIGFUS treatment.

Patient 3

A 26-year-old diabetic man was diagnosed with a right parietal GBM in October 2002. He underwent a right parietal craniotomy and resection of the tumor with subsequent radiation therapy (60 Gy). Four months later, he was reoperated for a large tumor recurrence and was started on temozolomide. Follow-up MRI performed in May 2003 showed local tumor progression. The patient was enrolled in the MRIGFUS protocol. The patient underwent surgery for removal of the bone flap overlying the craniotomy site, and an open biopsy showed evidence of active tumor. Seven days later, the patient received MRIGFUS treatment under general anesthesia. The small tumor target (5 cm³) received a total of 47 sonications.

Post-treatment imaging revealed significant tumor response manifested as resolution of enhancement of the treated volume in the contrast-enhanced T1-weighted images and significant new enhancement in the DWMRI scans. Treatment-related changes were also apparent in the T2-weighted images (Fig. 3).

An MRI scan acquired 24 hours after treatment showed a new small lesion in the right cerebral peduncle (Fig. 5) that resolved spontaneously within days. This new lesion was associated with a new mild left hemiparesis that developed on the third post-treatment day. The midbrain lesion could not be detected immediately after treatment because this region in the brain was not included in the limited field of view of the treatment MRI coil. The patient was discharged, but was rehospitalized several weeks later for complications of diabetic foot ulcer that subsequently required a below-knee amputation of his left leg. His follow-up MRI scans showed no evidence of tumor until 4 months after MRIGFUS treatment, when a new enhancing lesion was detected at the previously treated site. A stereotaxic biopsy revealed only necrosis with reactive astrocytes with no evidence of tumor. The lesion gradually regressed over time until, 3 months later, almost no radiological abnormality was evident. In June 2004, tumor recurrence was detected on MRI scans and a biopsy confirmed the presence of viable tumor. The patient declined further therapy, but his MRI scans showed only a slow and minimal progression over the ensuing months.

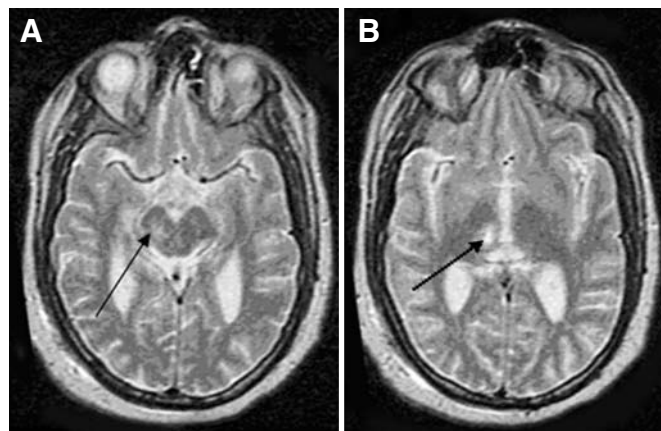


FIGURE 5. T2-weighted MRI scans obtained from Patient 3 24 hours after MRIGFUS treatment showing the new hyperintense signal in the upper midbrain (A) and diencephalic regions (B) (arrows).

The patient is currently alive 33 months after MRIGFUS and is undergoing various alternative therapies.

DISCUSSION

The concept of thermal ablation of tumors has been pursued for many years (6, 7, 11, 12). Success has been hindered by problems of insufficient precision, inability to control the deposition of the heat-producing energy, lack of reliable real-time temperature measurements within the target, and the invasive nature of many of the technologies applied to produce thermo-coagulation.

Focused ultrasound is another such technology capable of delivering energy converted to heat into body tissues. However, the coupling of focused ultrasound with the precision and guidance provided by MRI turns the technology into a unique method that may enable safe and precise thermal destruction of tissue. This is critical in the setting of treating tumors within highly functional organs, such as the brain.

Our preliminary results confirm the potential use of MRI-guided focused ultrasound in the brain. In Patient 2, from whom tissue was available for evaluation after MRIGFUS treatment, targeted tissues exhibited sharply demarcated lesion showing coagulation necrosis identical to that seen in our studies in the pig brain (10). Adjacent nontumoral brain tissue did not seem to have been affected based on post-treatment DWMRI and conventional MRI sequences. Intraprocedural MRI scans were able to accurately predict the volume of tissue destroyed based on the temperature maps generated during the procedure, as well as by follow-up contrast-enhanced MRI scans that showed the persisting loss of enhancement, and DWMRI scans, which showed clear enhancement at the treated sites. The procedure itself was well tolerated. In the post-treatment period, one patient exhibited a mild worsening of dysphasia that was reversible within days after increasing her steroid dose. A significant adverse event occurred in Patient 3,

in whom a secondary focus developed in the midbrain that caused new hemiparesis. One possible explanation for this event was a reflection of the ultrasound beam from the target point. Because temperature measurements were performed in a real-time fashion in only three axial planes, temperature elevations outside of these planes were not detected. Additional safety measures (software modifications to enable temperature measurements along the ultrasound beam; in-line view) were implemented to enhance the safety of the procedure.

The technology is far from optimal. It requires an operation for forming a bone window to allow the ultrasound energy to reach the deeper tumor, making it an invasive procedure. Future and ongoing modifications of the system may enable true noninvasive use of focused ultrasound through the intact cranium. This approach was recently approved by the Food and Drug Administration for clinical studies in patients with deeply located tumors. As yet, it is unclear whether or not the physical constraints posed by such a closed cranium device will allow for treatment of more superficial tumors. In addition, the treatment is not risk free, as was demonstrated in two of our patients (worsening dysphasia in one and a new motor deficit in another). It is probable that, because the technology will be used more frequently in the treatment of other diseases, such as uterine fibroids, and breast, liver, and bone tumors, many of the technical problems facing the application of focused ultrasound may be resolved.

The biology of thermal ablation of tumors has not been sufficiently investigated. The effect of coagulation of tumor cells may induce other cellular processes, such as activation of the immune system and enhanced tumor control. Hyperthermia is able to regulate several aspects of the immune response. Its implication in various molecular events, such as those involving the *Fas* gene and its ligand *FasL*, was recently described, with the suggestion that hyperthermia may enhance tumor cell cytotoxicity by enhancing transcriptional activity of various transcription factors. Thus, it has been suggested that heat may act as an immunomodulator in cancer therapy (2). Moreover, hyperthermia may lead to direct maturation of dendritic cells in vitro and in vivo, and this effect correlates well with an improved immunostimulatory activity mediated by these cells (15). Thus, even the noncoagulative temperature elevations that took place in Patient 1 may have had some biological effect on his tumor, although we have no evidence to support such speculation.

Although only three patients were treated using our focused ultrasound approach and no efficacy data are available, it is intriguing that all three who harbored recurrent GBM were found to enjoy long-term survival (two are still alive 33 and 38 mo after their treatment, one with no evidence of active tumor, and one survived for 10 mo before dying of her disease).

The potential therapeutic applications of focused ultrasound in the brain should not be limited only to tumor destruction. Controlled local heating may be used for precise local destruction of brain regions for functional and movement disorders, such as Parkinson's disease, or used to disrupt the blood-brain barrier of selected sites to enhance local drug delivery (1).

As the technology matures and true noninvasive focused ultrasound will become available for treating brain tumors, the application may be especially suitable for the treatment of benign tumors, such as meningiomas and pituitary adenomas, that can be cured by thermocoagulation. In fact, the concept of focused energy sources may replace currently available ionizing radiation-based treatment methods and may enable tumor destruction and repeated treatments without the risks associated with radiation and its late deleterious effects.

In summary, our data demonstrate the feasibility of using MRigFUS for the targeting and destruction of malignant brain tumors. However, the technology was associated with some toxicity resulting from localized brain response to coagulative process in one patient and to a presumed formation of a secondary, reflected lesion in another. Software modifications were implemented to improve the safety profile of the technology. The known characteristics of focused ultrasound observed in treating brain targets in pigs and in organs other than the brain were validated in our patients. Histological analysis of a treated tumor in one of our patients confirmed the sharp demarcation of the sonicated regions from adjacent tissues and the ability to predict the radiological therapeutic effect, similar to the effects seen in our animal studies.

REFERENCES

1. Cho CW, Liu Y, Cobb WN, Henthorn TK, Lillehei K, Christians U, Ng KY: Ultrasound-induced mild hyperthermia as a novel approach to increase drug uptake in brain microvessel endothelial cells. *Pharm Res* 19:1123–1129, 2002.
2. Cippitelli M, Fionda C, Di Bona D, Piccoli M, Frati L, Santoni A: Hyperthermia enhances CD95-ligand gene expression in T lymphocytes. *J Immunol* 174:223–232, 2005.
3. Hynynen K, Clement GT, McDannold N, Vykhodtseva N, King R, White PJ, Vitek S, Jolesz FA: 500-element ultrasound phased array system for noninvasive focal surgery of the brain: A preliminary rabbit study with ex vivo human skulls. *Magn Reson Med* 52:100–107, 2004.
4. Jolesz FA, Hynynen K, McDannold N, Freundlich D, Kopelman D: Noninvasive thermal ablation of hepatocellular carcinoma by using magnetic resonance imaging-guided focused ultrasound. *Gastroenterology* 127 [Suppl 5]:S242–247, 2004.
5. Kacher DF, Jolesz FA: MR imaging-guided breast ablative therapy. *Radiol Clin N Am* 42:947–962, 2004.
6. Kettenbach J, Silverman SG, Hata N, Kuroda K, Saiviroonporn P, Zientara GP, Morrison PR, Hushek SG, Black PMcL, Kikinis R, Jolesz FA: Monitoring and visualization techniques for MR-guided laser ablations in an open MR system. *J Magn Reson Imaging* 8:933–943, 1998.
7. Law P, Gedroyc WM, Regan L: Magnetic resonance-guided percutaneous laser ablation of uterine fibroids. *J Magn Reson Imaging* 12:565–570, 2000.
8. McDannold N, King RL, Hynynen K: MRI monitoring of heating produced by ultrasound absorption in the skull: In vivo study in pigs. *Magn Reson Med* 51:1061–1065, 2004.
9. McDannold N, Vykhodtseva N, Jolesz FA, Hynynen K: MRI investigation of the threshold for thermally induced blood-brain barrier disruption and brain tissue damage in the rabbit brain. *Magn Reson Med* 51:913–923, 2004.
10. Ram Z, Zauberman Y, Harnof S, Faibel M, Tal S, Mardor Y, Nass D, Castel D, Freundlich D, Zadicario E, Yagel R: High-intensity focused ultrasound for the treatment of brain tumors. Presented at the 72nd Annual Meeting of the American Association of Neurological Surgeons, San Diego, CA, April 26–May 1, 2003.
11. Ramsey EW, Miller PD, Parsons K: A novel transurethral microwave thermal ablation system to treat benign prostatic hyperplasia: Results of a prospective multicenter clinical trial. *J Urol* 158:112–119, 1997.

12. Tracz RA, Wyman DR, Little PB, Towner RA, Stewart WA, Schatz SW, Wilson BC, Pennock PW, Janzen EG: Comparison of magnetic resonance images and the histopathological findings of lesions induced by interstitial laser photocoagulation in the brain. *Lasers Surg Med* 13:45–54, 1993.
13. Vykhodtseva N, Sorrentino V, Jolesz FA, Bronson RT, Hynynen K: MRI detection of the thermal effects of focused ultrasound on the brain. *Ultrasound Med Biol* 26:871–880, 2000.
14. Yagel S: High-intensity focused ultrasound: A revolution in non-invasive ultrasound treatment? *Ultrasound Obstet Gynecol* 23:216–217, 2004.
15. Zheng H, Benjamin IJ, Basu S, Li Z: Heat shock factor 1-independent activation of dendritic cells by heat shock: Implication for the uncoupling of heat-mediated immunoregulation from the heat shock response. *Eur J Immunol* 33:1754–1762, 2003.

COMMENTS

Conceptually, there are few things so innately cool as focused ultrasound (FUS) ablation of intracranial lesions. Such treatment seems to offer surgeons a truly noninvasive ablative tool and is almost “Star-Trekian” in scope. Furthermore, when coupled with magnetic resonance imaging (MRI), FUS experiences none of the limitations imposed by using ionizing radiation. For these reasons alone, it is impossible to not be intrigued by FUS. Despite so much innate enthusiasm for the basic approach, this report by Ram et al. more readily demonstrates just how many problems need to be solved before FUS can offer our patients any practical benefits.

Yes, FUS with MRI does not use ionizing radiation. However, this “noninvasive” technology currently requires a craniotomy to obtain an adequate ultrasound window which, I might add, only works at present for posteriorly-situated lesions. Until I can be proven wrong, I will remain deeply skeptical that a technology under development is just around the corner to remedy this huge limitation. Meanwhile, something as commonplace as dural substitute can totally ineffectuate treatment benefits. Ironically, this phenomenon was encountered in the longest surviving patient in this series. The authors liberally use the words “precise” and target “verification” in their report, yet in one of the two patients in whom treatment actually made it through the dura, the uninvolved midbrain was inadvertently thermocoagulated. What’s more, does thermocoagulation of intracranial lesions, much less infiltrating glioma, necessarily result in a desirable clinical outcome? A big necrotic lump in a patient’s brain is often associated with mass effect, a situation in which surgical resection is generally preferred. For smaller intracranial lesions, radiosurgery has proven, over several decades, to be both incredibly effective and very safe across a spectrum of pathologies. Meanwhile, based on the current report alone, it would not be hard to conjure up still additional, and, in some cases, fundamental limitations to FUS, which epitomizes the notion of work in progress.

Despite the above hard-nosed criticism, I think the type of research being presented here has considerable promise. I congratulate Ram et al. for pioneering this exciting new field and hope very much that they will be able to work through many of the present day technical and clinical limitations. My intent in lodging such criticism is not to squash the author’s obvious enthusiasm for what could someday be an important field of neurosurgery. Rather, I want to temper the reader’s expectations that FUS is likely to be ready for primetime any time soon.

John R. Adler, Jr.
Stanford, California

This report describes the initial experience in three patients with malignant gliomas who were enrolled in an institutional review

board-approved Phase I study to explore the use of FUS based on MRI guidance. All patients had tumor progression after previous multimodality management. In my view, there are several takeaway messages associated with this initial report. First, preclinical data before patient experience would enhance our understanding of the potential role of this technology, if any, in the brain. Such research has not been published. Secondly, three patients had intervention; one had no effective ultrasound energy delivered (technical failure), and two others had complications (aphasia in one and brainstem injury in the other). This report does not and cannot define any benefit to these patients, all speculation aside. Thirdly, the technological requirements represent a tour de force: craniotomy first, then the procedure itself, followed by a long stay in the intensive care unit and multiple imaging studies. Fourthly, if this technique, after additional experience, shows any continuing merit for intracranial tumors, it must surely be based on a revision that greatly reduces the additional need for preadministration craniectomy. This being said, there is an ongoing need for creative thinking about gliomas. I personally doubt that more creative surgery will ever make a substantive breakthrough in gliomas, as these tumors just don’t seem to understand that we neurosurgeons want to solve it by better surgery, even though they are invasive, have poor borders, and extend far beyond the imaging defined abnormalities. Hopefully, neurosurgical application of molecular strategies coupled with less invasive delivery techniques will make a difference.

L. Dade Lunsford
Pittsburgh, Pennsylvania

Ram et al. present preliminary data on the use of MRI-monitored FUS treatment for malignant gliomas. This technology, which has found application in other body areas (e.g., uterine fibroids), uses ultrasound through a cranial window to heat tumor tissue. The heating can be monitored, in near real-time, with MRI scans. Three patients were treated in this study. In one, no heating was produced secondary to a dural graft substance. In the others, heating was produced and monitored; one of these patients developed a lesion in the cerebral peduncle several centimeters from the target, leading to a neurological deficit. This work is clearly very preliminary but, with further hardware and software refinements, could prove useful in the treatment of some brain tumors.

One wonders whether or not malignant gliomas will ultimately be the best patient population. Other focal therapies, including surgery, brachytherapy, and radiosurgery, have been minimally effective because of the invasive and multicentric nature of the disease. It is of some interest that the patient who had no heating (essentially a control) had prolonged survival. This is an excellent reminder of the other issue with glioma therapies: selection bias. Without controls, many new therapies have been regarded enthusiastically. Only later, when randomized controlled trials were performed, was the so-called beneficial effect found to be a result of selection bias. Perhaps this treatment will prove more useful, ultimately, in the treatment of recurrent or persistent tumors with well defined borders (i.e., meningiomas, metastases, and schwannomas). Another potential application might be to couple focused heating with other chemical or biological therapies with effects that could be selectively enhanced by heating.

William A. Friedman
Gainesville, Florida

This is an interesting study describing the early clinical experience of the use of the evolving technology of MRI-guided FUS for the abla-

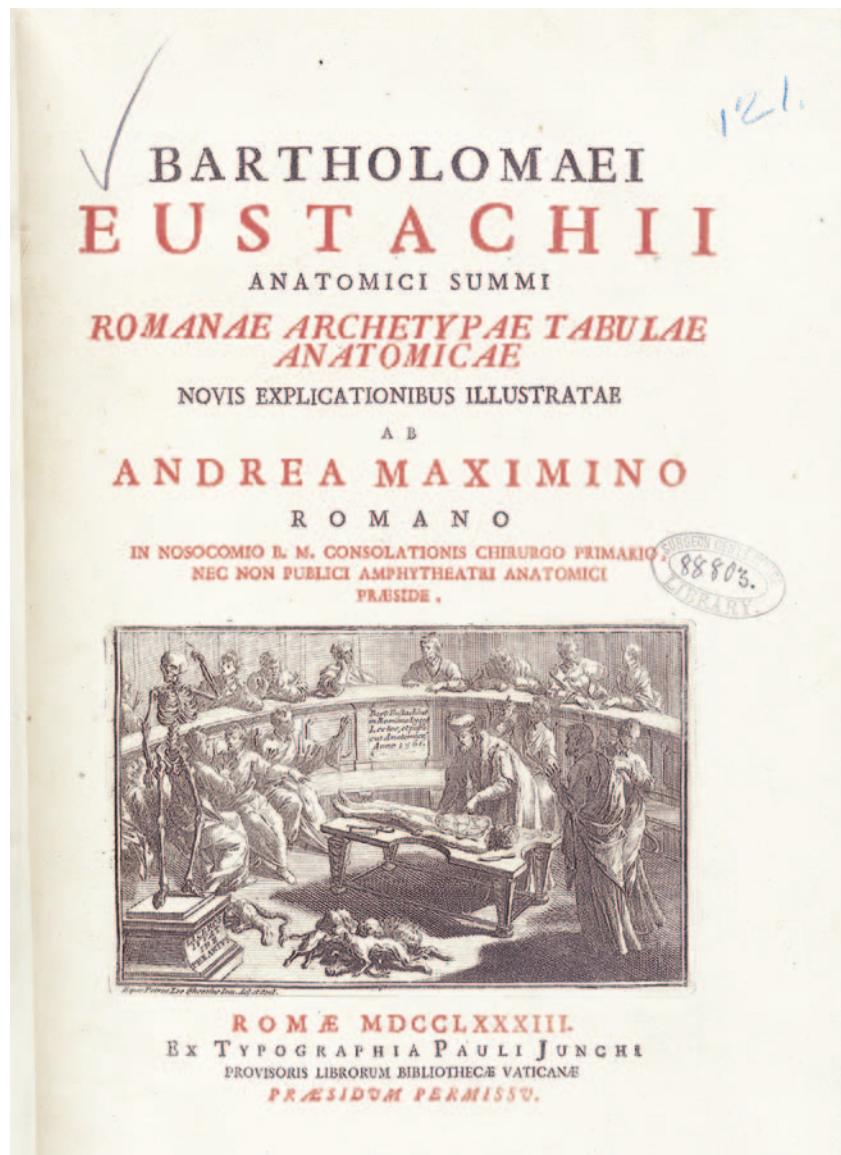tion of brain tumors. The experience described here is with recurrent malignant gliomas, but the principal value of this technology, if it proves to have value, will likely be in benign tumors such as meningiomas, in which ablative therapies may well be sufficient. Obviously, another potential use would be the ablation of normal brain targets for functional neurosurgical applications.

FUS has seen some use for the treatment of malignant brain tumors by localized hyperthermia (1). Then, as now, the drawback to this approach was the inability to sonicate through the intact cranium, necessitating a pretreatment craniectomy. This drawback is now being addressed in the laboratory, but the result of treating through bone has thus far been a small sonication spot, making large volume ablations time consuming (2). Until ablation through an intact cranium is

clinically practical, FUS for tumor removal or other neurosurgical applications will not be widely applied.

Philip H. Gutin
New York, New York

1. Guthkelch AN, Carter LP, Cassady JR, Hynynen KH, Iacono RP, Johnson PC, Obbens EA, Roemer RB, Seeger JF, Shimm DS, Stea B: Treatment of malignant brain tumors with focused ultrasound hyperthermia and radiation: Results of a phase I trial. *J Neurooncol* 10:271-284, 1991.
2. Clement GT, White PJ, King RL, McDannold N, Hynynen K: A magnetic resonance imaging-compatible, large-scale array for trans-skull ultrasound surgery and therapy. *J Ultrasound Med* 24:1117-1125, 2005.



Bartholomeo Eustachi, ca. 1500-1574, *Tabulae anatomicae*. Romae: Ex Typographia Pauli Junchi, 1783 (courtesy of the U.S. National Library of Medicine, National Institutes of Health, Bethesda, Maryland).