

Resolution of Arterial Stenosis in a Patient With Periarterial Neurocysticercosis Treated With Oral Prednisone

ABSTRACT

Neurocysticercosis is the most common parasitic infection of the central nervous system. Neurovascular complications have been recognized as a frequent complication, with up to 10% of strokes in endemic areas being secondary to neurocysticercosis. We report a case of acute transient left hemichorea in an 11-year-old boy with cerebral cysticercosis involving the right middle cerebral artery. Brain magnetic resonance imaging (MRI) revealed T₂-weighted hyperintensity and gadolinium enhancement in the area surrounding the M1 segment of the right middle cerebral artery. Magnetic resonance angiography showed severe narrowing of the vessel at this site acutely. After treatment with a 1-month course of oral prednisone and initiation of aspirin, our patient had no recurrence of abnormal movements and follow-up magnetic resonance angiography and transcranial Doppler ultrasonography showed resolution of stenosis of the M1 segment. (*J Child Neurol* 2006;21:1064–1067; DOI 10.2310/7010.2006.00132).

Neurocysticercosis is the most common parasitic infection of the central nervous system. Endemic in many parts of the developing world, neurocysticercosis is being seen more frequently in parts of the United States as a result of immigration.¹ Common central nervous system complications include hydrocephalus, seizures, meningitis, and psychiatric symptoms. Neurovascular complications have been recognized as a frequent complication, occurring in 2% to 12% of patients during their initial presentation of neurocysticercosis.^{2–6} In endemic areas, up to 10% of strokes can be secondary to neurocysticercosis.⁷

The vascular complications appear to be a secondary effect on the cerebral vessels of the host inflammatory response to deteriorating cysts in the subarachnoid space. Several reports have found stroke to be most commonly associated with a focal cystic lesion leading to an occlusive arteritis in small perforating vessels, resulting in lacunar infarction.^{2,3,7,8} One series found that more diffuse disease with an intense inflammatory reaction is associated with a higher incidence of ischemic events.⁹ Arterial thrombosis has been demonstrated by angiographic studies of patients with cerebral cysticercosis.^{10–12} Other pathophysiologic mechanisms implicated in cerebral infarction include the development of a fusiform aneurysm produced by weakening of vessel walls,¹² thrombosis of superficial cortical vessels secondary to chronic meningitis,¹³ and angiitis involving large intracranial vessels.¹⁴ Interestingly, cerebral cysticercosis has only rarely been reported as an etiology for transient ischemic attacks.^{3,14,15} Corticosteroids have been commonly used to treat the inflammation associated with cases with cerebrovascular involvement, but we are not aware of previous demonstration of benefit by serial neuroimaging studies.^{3,16}

Case Report

The patient is an 11-year-old right-handed Mexican-American boy who was previously well until he presented to an outside hospital with uncontrollable movements in his left foot at the ankle joint. The movements began on awakening from a nap and progressed over 20 to

30 minutes to involve the rest of the leg, the left arm, and the face. The limb movements were described as slow and writhing with nonrhythmic flexion and extension at the involved joints. The movements continued for 4 hours and then abated without treatment. He was alert and appropriate during this time and denied subjective alteration of consciousness. There were no associated visual changes, nausea, vomiting, fever, neck pain, or stiffness. He had been having right retro-orbital pain for the previous 4 days. The history revealed several family trips to Mexico, most recently 2 months previously.

Laboratory tests, including serum electrolytes, glucose, blood urea nitrogen, creatinine, complete blood count, thyroid-stimulating hormone, antinuclear antibody, and antistreptolysin O titers, were all within normal limits. Lumbar puncture was remarkable for cerebrospinal fluid white blood cell count of 122/μL (87% lymphocytes, 10% segmented neutrophils, and 3% monocytes), with a red blood cell count of 0/μL, glucose of 64 mg/dL, and protein of 35 mg/dL. Gram and acid-fast stains and routine bacterial cultures were negative. Cytologic examination via cytopsin was negative for malignant cells. Brain computed tomography showed only a punctate focus of apparent calcification, 2 mm in diameter, appearing to be in the region of the right inferomedial basal ganglia just superior to the anterior temporal lobe. Brain magnetic resonance imaging (MRI) was performed the following day, revealing a large area (2 cm diameter) of increased T₂-weighted signal intensity centered around the proximal right middle cerebral artery extending into the adjacent anterior inferior frontal lobe, anteromedial temporal lobe, and inferior portions of the globus pallidus and putamen. A smaller focus of gadolinium enhancement in the region of the M1 segment of the right middle cerebral artery was noted. These same findings were demonstrated a week later on repeat MRI at our institution, as shown in Figure 1.

Two days after this first episode, the patient had a second similar episode of left-sided choreiform movements lasting 7 hours. Presumed to have had partial seizure activity or anxiety at the outside emergency room, he was treated with lorazepam 1 mg three times daily pending referral for evaluation. We subsequently evaluated him at the Children's Hospital and Regional Medical Center (Seattle, WA) 8 days after the initial presentation. At that time, he had a completely normal neurologic examination. Repeat brain MRI revealed the same areas of T₂-weighted hyperintensity and gadolinium enhancement described above (see Figure 1). Magnetic resonance angiography revealed focal stenosis at the M1 segment of the right middle cerebral artery (see Figure 1D). Electroencephalography, done to assess a possible epileptic etiology of the events, was within normal limits. A purified protein derivative skin test had been placed a week before and was reported as negative, although this result could not later be confirmed. Acid-fast culture from the cerebrospinal fluid was eventually negative after 45 days. Enzyme-linked immunoserologic assay for cysticercosis performed on the cerebrospinal fluid previously obtained was negative. Serum IgM, however, was mildly positive for cysticercosis at 1:32. A serum immunoblot assay was also positive.

Owing to concern over worsening stenosis of the right middle cerebral artery and the possibility of a major stroke, we treated the patient with a 1-month course of oral prednisone (60 mg/day for 2 weeks followed by a 2-week taper) and initiated oral aspirin (81 mg/day) as chronic antiplatelet therapy. Transcranial Doppler ultrasonography was performed 4 weeks after the initial presentation, at which time it demonstrated mildly elevated blood flow velocity (108 cm/second in the right middle cerebral artery versus 87 cm/second in the left middle cerebral artery), which was felt to represent mild vessel narrowing. Repeat magnetic resonance angiography 6 weeks after presentation showed resolution of right middle cerebral artery stenosis (Figure 2). Brain MRI revealed no increased T₂-weighted signal surrounding the right middle cerebral artery, as seen on the previous study, likely reflecting resolution of edema related to the parenchymal inflammatory reaction.

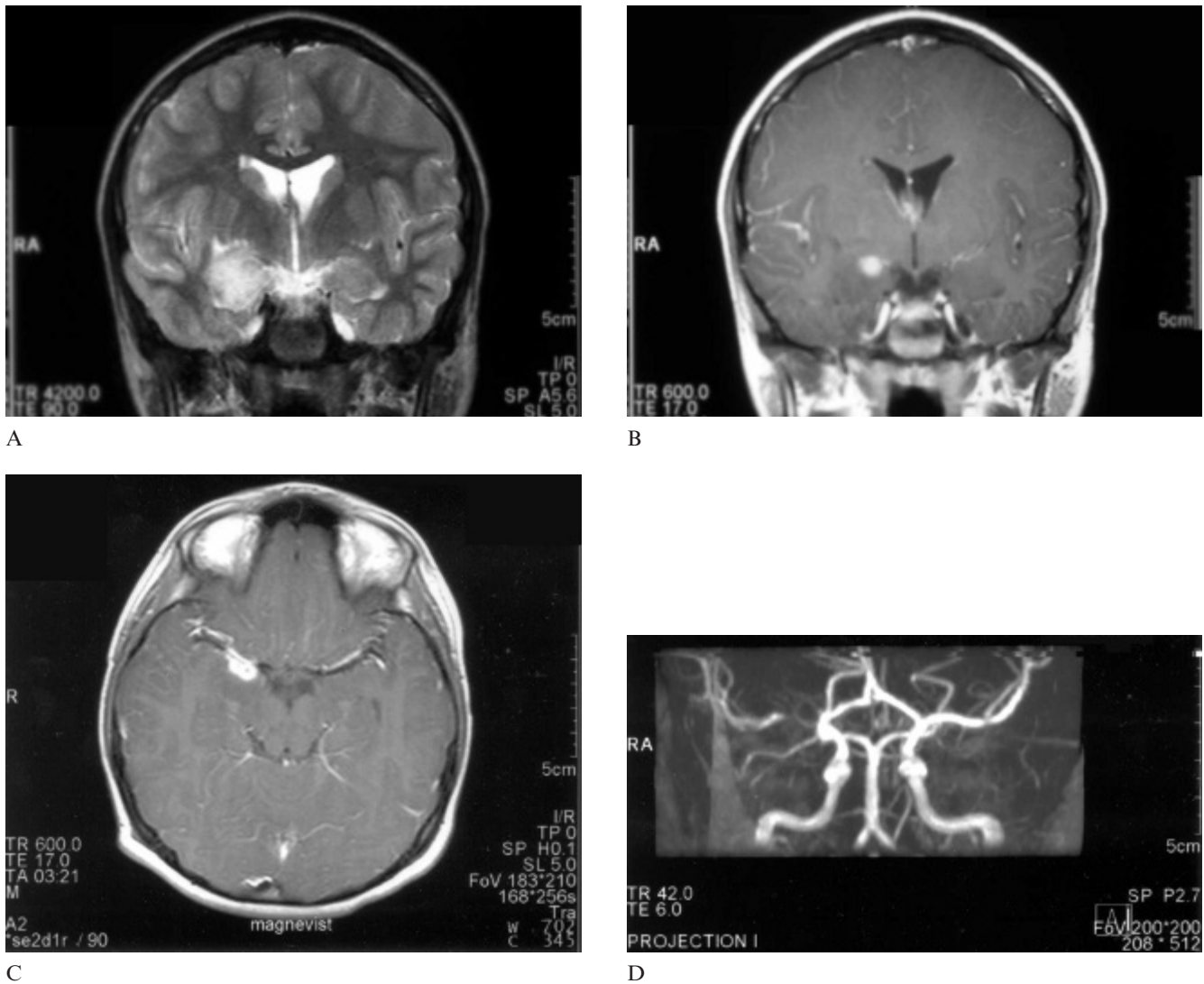


Figure 1. Brain magnetic resonance imaging 8 days after the initial presentation reveals T₂-weighted hyperintensity in the anteromedial temporal lobe and inferior aspects of the putamen and globus pallidus on a coronal T₂-weighted image (A). A smaller focus of gadolinium enhancement in the region of the M1 segment of the right middle cerebral artery was noted on both coronal (B) and axial (C) T₁-weighted images following intravenous gadolinium administration. Magnetic resonance angiography reveals focal stenosis at the M1 segment of the right middle cerebral artery (D).

Transcranial Doppler ultrasonography was repeated at 2, 4.5, and 9.5 months after presentation. Each study revealed normal blood flow velocity in all cerebral arteries, including the right middle cerebral artery. The patient has had no further episodes of abnormal movements up to 28 months after admission.

Discussion

The severe narrowing of the right middle cerebral artery on our patient's initial magnetic resonance angiography was worrisome because of the possibility of a large impending infarction owing to occlusion of the M1 segment. We initiated a course of prednisone to decrease the acute inflammatory response to the dying cyst, hoping to prevent or reverse the vessel wall fibrosis, which we feared could lead to complete stenosis of the artery. The subsequent normal MRI, magnetic resonance angiography, and transcranial Doppler ultrasound studies demonstrated resolution of arterial stenosis owing to neurocysticercosis after treatment with corticosteroids. Owing to the severity of our patient's arterial narrowing, he was also treated with aspirin as long-term prophylaxis for symptomatic intracranial stenosis. We chose not to treat the patient with antiparasitic medication because the location of the periarterial lesion

increased the risk of stroke and permanent neurologic deficits. Also, neurologic symptoms often worsen acutely with antiparasitic agents, presumably owing to the accelerated death of the cyst and the corresponding host inflammatory response. Cerebral infarction during treatment with these agents has been reported.^{4,17,18} Further, the long-term benefit of antiparasitic agents over symptomatic therapy alone has not been convincingly demonstrated in well-controlled studies.¹⁶ Without antiparasitic therapy, cysticerci are thought to complete degeneration over 1 to 2 years.¹⁶ Thus, we elected to continue aspirin at least through this period.

In our patient, the enzyme-linked immunoserologic assay for cysticercosis performed on cerebrospinal fluid was negative. The serum enzyme immunoblot assay, however, was positive. Because the sensitivity of this assay is higher for serum than cerebrospinal fluid samples even in the presence of brain lesions, it is the study of choice for laboratory diagnosis.^{19,20} However, it is less sensitive in cases with solitary lesions, as well as in children, in whom an overall sensitivity of 72% and a specificity of 96% were reported in one study. Sensitivity among children in that study was higher (100%) in cases with multiple cysts and lower (59%) in cases such as ours with single cysts.²¹ Because our patient's

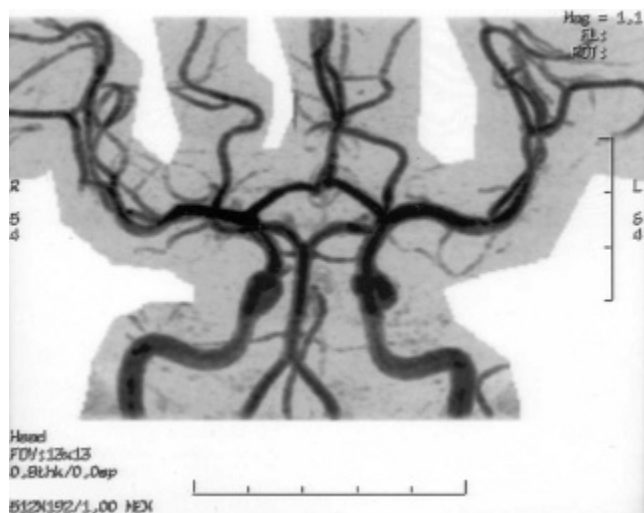


Figure 2. Repeat brain magnetic resonance angiography 6 weeks after presentation and following treatment with prednisone reveals resolution of stenosis of the right middle cerebral artery.

initial studies were negative for cysticercosis, other possible etiologies for the lesion noted on MRI were considered, including other infectious agents and neoplasm. Although imaging and cerebrospinal fluid findings were concerning for a tubercular etiology, the negative acid-fast stain and the general well-being of the patient did not support this diagnosis. Certainly, a lymphoma or other brain neoplasm could respond to corticosteroid therapy with transient clinical improvement. If the patient's response to the corticosteroids simply represented decreased perilesional edema of an underlying slow-growing neoplasm, it seems likely that he would have become symptomatic again during the 3 years since treatment under our care.

It is possible that our patient's arterial stenosis could have resolved independent of corticosteroid treatment. In one report, however, only two of six patients with major intracranial vessel cerebral cysticercotic arteritis showed resolution by transcranial Doppler ultrasonography after several months.²² It was not noted whether they received corticosteroids. Although that report included only a small number of patients, given the range of outcomes reported, we would still not have expected to see such a dramatic spontaneous improvement by 1 month after presentation. In fact, we believe that our patient's degree of stenosis was likely already decreased by the time his initial transcranial Doppler ultrasonography was performed (4 weeks after onset of symptoms), so the mild stenosis reflected by increased right middle cerebral artery flow velocity almost certainly had already improved from a much more severe stenosis at presentation. Supporting this, the repeat magnetic resonance angiography done 6 weeks after presentation showed complete resolution of the previously severe stenosis of the M1 segment (see Figure 2).

We believe that our patient's transient movement disorder was caused by ischemia of the basal ganglia owing to either the observed middle cerebral artery stenosis or angitis of adjacent penetrating lenticulostriate vessels and was initially caused by the inflammatory reaction against the neurocysticercosis lesion. The transient, recurrent nature of the symptoms might have resulted from intermittent vasospasm in an already compromised vascular territory. This case also documents radiographically resolution of arterial stenosis in neurocysticercosis following treatment with prednisone. Our patient's course supports the common practice of treatment with corticosteroids to prevent stroke in cases of cysticercotic meningitis.³ We suggest that oral prednisone or intravenous corticosteroids should be considered acute therapy for patients presenting with periarterial neurocysticercosis. Finally, in cases of suspected neurocysticercosis, we recommend that diffusion-weighted MRI and either magnetic resonance angiography or transcranial Doppler ultrasonography be performed at presentation to determine the degree of arterial stenosis, particularly in cases presenting with neurologic deficits

indicating the risk of occlusion and infarct, as well as serially to assess treatment efficacy. In the developing world, where neurocysticercosis is much more prevalent, such neuroimaging modalities can be less readily available. In such cases, we suggest empiric treatment with corticosteroids after excluding tuberculosis as a reasonable alternative approach.

Anthony Bouldin, MD
 Division of Pediatric Neurology
 University of Washington School of Medicine
 Seattle, WA
 Joseph D. Pinter, MD
 the Department of Neurology
 University of California, Davis Medical Center
 Sacramento, CA

Received May 5, 2004. Received revised Dec 10, 2004; May 18, 2005; and June 28, 2005. Accepted for publication July 11, 2005.

This work was completed at the University of Washington and the Children's Hospital and Regional Medical Center, Seattle, WA. Dr Pinter contributed equally to this work as a clinical mentor.

Address correspondence to Dr Anthony Bouldin, Division of Pediatric Neurology, Children's Hospital and Regional Medical Center, Division of Neurology 5D-4, 4800 Sand Point Way, NE, Seattle, WA 98105-2078. Tel: 206-987-2078; fax: 206-987-2649; e-mail: tbouldin100@yahoo.com.

References

- Sotelo J, Guerrero V, Rubio F: Neurocysticercosis: A new classification based on active and inactive forms. *Arch Intern Med* 1985;145:442-445.
- Barinagarrementeria F, Del Brutto O: Lacunar syndrome due to neurocysticercosis. *Arch Neurol* 1989;46:415-417.
- Del Brutto OH: Cysticercosis and cerebrovascular disease: A review. *J Neurol Neurosurg Psychiatry* 1992;55:252-254.
- Earnest MP, Reller LB, Filley CM, Grek AJ: Neurocysticercosis in the United States: 35 cases and a review. *Rev Infect Dis* 1987;9:961-979.
- Del Brutto OH, Sotelo J: Neurocysticercosis: An update. *Rev Infect Dis* 1988;10:1075-1087.
- Torrealla G, Del Villar S, Tagle P, et al: Cysticercosis of the central nervous system: Clinical and therapeutic considerations. *J Neurol Neurosurg Psychiatry* 1984;47:784-790.
- Alarcon F, Hidalgo F, Moncayo J, et al: Cerebral cysticercosis and stroke. *Stroke* 1992;23:224-228.
- Barinagarrementeria F, Del Brutto O: Neurocysticercosis and pure motor hemiparesis. *Stroke* 1988;19:1156-1158.
- Cantu C, Barinagarrementeria F: Cerebrovascular complications of neurocysticercosis: Clinical and neuroimaging spectrum. *Arch Neurol* 1996;53:233-239.
- McCormick GF, Zee CS, Heiden J: Cysticercosis cerebri: Review of 127 cases. *Arch Neurol* 1982;39:534-539.
- Carbajal JR, Palacios E, Azar-Kia B, Churchill R: Radiology of cysticercosis of the central nervous system including computed tomography. *Radiology* 1977;125:127-131.
- Rodriguez-Carbajal J, Del Brutto OH, Penagos P, et al: Occlusion of the middle cerebral artery due to cysticercotic angitis. *Stroke* 1989;20:1095-1099.
- Grisolia JS, Wiederholt WC: CNS cysticercosis. *Arch Neurol* 1982;39:540-544.
- McCormick GF, Giannotta S, Zee C, Fisher M: Carotid occlusion in cysticercosis. *Neurology* 1983;33:1078-1080.
- Bickerstaff ER: Cerebral cysticercosis: Common but unfamiliar manifestations. *BMJ* 1955;1:1055-1058.
- White AC Jr: Neurocysticercosis: Updates on epidemiology, pathogenesis, diagnosis, and management. *Annu Rev Med* 2000;51:187-206.
- Bang OY, Heo JH, Choi SA, Kim DI: Large cerebral infarction during praziquantel therapy in neurocysticercosis. *Stroke* 1997;28:211-213.

18. Woo E, Yu YL, Huang CY: Cerebral infarct precipitated by praziquantel in neurocysticercosis—A cautionary note. *Trop Geogr Med* 1988;40:143–146.
19. Wilson M, Bryan RT, Fried JA, et al: Clinical evaluation of the cysticercosis enzyme-linked immunoelectrotransfer blot in patients with neurocysticercosis. *J Infect Dis* 1991;164:1007–1009.
20. Rosenfeld E: Neurocysticercosis update. *Pediatr Infect Dis J* 2003;22:181–182.
21. Aguilar-Rebolledo F, Meza-Lucas A, Torres J, et al: Evaluation of the enzyme-linked immunoelectrotransfer blot assay for diagnosis of neurocysticercosis in children. *J Child Neurol* 2002;17:416–420.
22. Cantu C, Villarreal J, Soto JL, Barinagarrementeria F: Cerebral cysticercotic arteritis: Detection and follow-up by transcranial Doppler. *Cerebrovasc Dis* 1998;8:2–7.