

Seizures during stroke thrombolysis heralding dramatic neurologic recovery

Abstract—Seizures during thrombolytic therapy for ischemic stroke have not previously been described as a favorable prognostic sign. We report three patients with severe stroke (NIH Stroke Scale [NIHSS] score 15 to 20) who experienced a seizure during tissue plasminogen activator (tPA) infusion. While initially raising alarm about possible hemorrhage, the seizures heralded dramatic recovery (an immediate 15-point NIHSS score improvement after tPA; NIHSS score 0 or 1 at 24 hours). We propose that the seizures during thrombolysis may indicate cortical reperfusion and/or hyperperfusion due to early recanalization of an acutely occluded intracranial artery.

NEUROLOGY 2006;67:2048–2049

L.H. Rodan, BSc; R.I. Aviv, MRCP, FRCR; D.J. Sahlas, MSc, MD, FRCPC; B.J. Murray, MD, FRCPC; J.P. Gladstone, MD, FRCPC; and D.J. Gladstone, MD, FRCPC, PhD

We describe three patients with severe stroke who experienced a seizure during tissue plasminogen activator (tPA) infusion. While initially raising alarm about possible intracranial hemorrhage, the seizures heralded immediate dramatic neurologic recovery.

Case reports. *Patient 1.* A 51-year-old woman with atrial fibrillation presented with acute hemiplegia, neglect, and gaze deviation (NIH Stroke Scale [NIHSS] score 17). CT revealed a hyperdense right middle cerebral artery (MCA) with loss of gray-white differentiation of the striatum; CT angiography confirmed M1 occlusion. CT perfusion (CTP) revealed right frontotemporal “tissue at risk” with a focal area of basal ganglia infarction. The patient received IV alteplase (Activase) 57 mg at 89 minutes after onset (0.6 mg/kg; 15% bolus, followed by 30-minute infusion) followed by 14 mg intra-arterial alteplase. During intra-arterial lysis, she experienced a focal motor seizure that coincided temporally with partial MCA recanalization (appearance of distal MCA, cortical and lenticulostriate vessels) and forced temporary interruption of the procedure. Complete recanalization was eventually achieved, with immediate recovery (NIHSS score 2). Post-treatment CT revealed contrast enhancement within the striatum. The next day, CTP confirmed restoration of perfusion with subtle hyperperfusion within the basal ganglia. MRI showed petechial hemorrhage in the basal ganglia; patchy fluid-attenuated inversion recovery hyperintensity consistent with infarct was present within the striatum, temporal and frontal operculum, and insular cortex. Discharge and 3-month NIHSS scores were 0.

Patient 2. A 35-year-old man presented with acute right hemiplegia and aphasia (NIHSS score 19). CT revealed early infarction of the left insula and operculum. IV alteplase 73 mg was administered 122 minutes after onset as per National Institute of Neurologic Disorders and Stroke protocol (0.9 mg/kg; 10% bolus, followed by 1-hour infusion). Five minutes into the infusion, the patient experienced a focal-onset seizure with secondary generalization (fencing posture with extension of right arm) and was intubated. tPA was not discontinued. Repeat imaging revealed no hemorrhage (figure), and the 24-hour NIHSS score was 1. EEG

showed slowing over the left temporoparietal region with no epileptiform features; EEG at 6 months was normal.

Patient 3. An 80-year-old woman developed acute hemiparesis, aphasia, and gaze deviation (NIHSS score 15) during diagnostic arteriography. Routine head CT at 81 minutes was unremarkable. IV alteplase 43 mg was administered at 90 minutes after onset as per National Institute of Neurologic Disorders and Stroke protocol. Fifteen minutes into the infusion, the patient experienced a generalized tonic-clonic seizure. The infusion was temporarily stopped. Repeat CT showed no changes. The NIHSS score improved to 2 immediately after tPA and to 0 at discharge. In retrospect, pretreatment CTP suggested left parietal hyperperfusion (possibly indicating spontaneous recanalization). MRI at 10 months confirmed a cortical and subcortical infarct within the left motor region.

Discussion. Seizures occur in approximately 2% of stroke patients during the first 48 hours.¹ We found no reports of seizures coinciding with tPA administration in the published literature (Medline search). We contacted Hoffmann-La Roche Ltd. and Genentech Inc., who had no data on file reporting seizures associated with tPA in their North American database (August 17, 2005).

Postulated mechanisms include 1) poststroke seizures (occurring coincidentally during tPA infusion); 2) secondary cortical infarction from distal embolization during thrombolysis; 3) potential epileptogenic properties of tPA (endogenous tPA can sensitize the brain via up-regulation of *N*-methyl-D-aspartate receptors, leading to a lower threshold for a hyperexcitable state)^{2,3}; and 4) reperfusion seizures. None of our patients had a history of seizures or recurrent seizures during follow-up, a toxic-metabolic cause for seizures, or hypertension requiring treatment before or during tPA. All had MRI confirmation of the stroke diagnosis with evidence of cortical infarction.

We speculate that the seizures in our patients arose from cortical reperfusion or hyperperfusion after recanalization of an acutely occluded intracranial artery. With vessel occlusion, autoregulation causes vasodilation of the regional vasculature to maintain cerebral blood flow. When thrombolysis is successful in restoring perfusion, cerebral autoregulation may not be able to elicit vasoconstriction quickly enough to prevent hyperperfusion. Animal models have demonstrated hyperperfusion after recanalization of an acutely occluded MCA, which can last several days.⁴

From the North and East GTA Regional Stroke Centre, Division of Neurology (Department of Medicine), Division of Neuroradiology, and Neurosciences Program, Sunnybrook Health Sciences Centre, Department of Medicine, University of Toronto, Toronto, Ontario, Canada, and the Heart and Stroke Foundation Centre for Stroke Recovery.

Disclosure: The authors report no conflicts of interest.

Received October 27, 2005. Accepted in final form August 13, 2006.

Address correspondence and reprint requests to Dr. David J. Gladstone, Division of Neurology and Regional Stroke Centre, A442, Sunnybrook and Women's College Health Sciences Centre, 2075 Bayview Avenue, Toronto, Ontario, Canada M4N 3M5; e-mail: david.gladstone@sw.ca

2048 Copyright © 2006 by AAN Enterprises, Inc.

Copyright © by AAN Enterprises, Inc. Unauthorized reproduction of this article is prohibited.

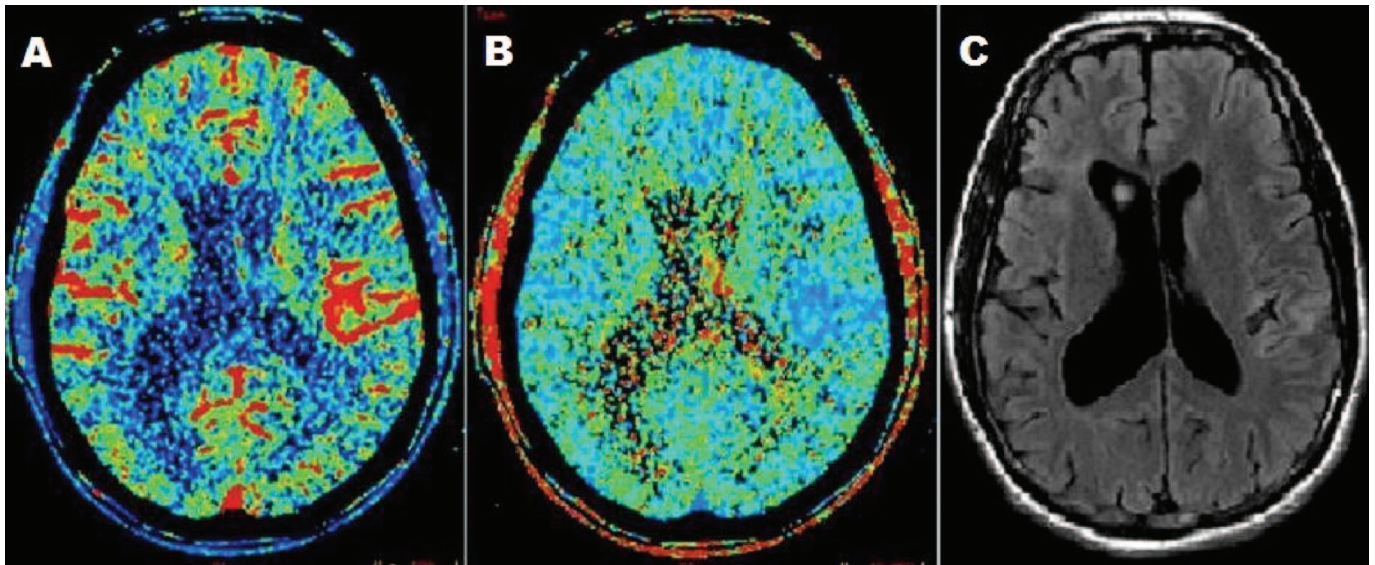


Figure. Twenty-four-hour CT perfusion (CTP) shows hyperperfusion within the left parietotemporal region manifest by increased blood flow (A) with a reduction in mean transit time (B). MRI 8 days after stroke shows a small predominantly cortical infarct corresponding with the area of abnormality on CTP within the insular cortex (C). On the diffusion-weighted MRI sequence (not shown), restricted diffusion was present within the left parietal and perisylvian region, compatible with acute cerebral ischemia.

Hyperperfusion results from release of vasodilatory compounds during ischemia followed by an autoregulatory dysregulation upon thrombolysis; release of vasoactive compounds (potassium, adenosine, arachidonate, bradykinin, free radicals) can lead to inflammation and cellular damage that may trigger a focal seizure.⁴ Indeed, seizures are a recognized consequence of hyperperfusion from other etiologies: hypertensive encephalopathy, fulminant hepatic failure, high-altitude cerebral edema, and the cerebral hyperperfusion syndrome after carotid endarterectomy.^{5,6} We did observe some evidence of hyperperfusion on CTP in our patients, although seizure per se may also cause this finding. The rarity of seizures accompanying dramatic stroke recovery suggests that successful recanalization alone is not usually sufficient for seizure production. Seizures

may rarely occur during thrombolysis and may (in the absence of intracerebral hemorrhage) be a favorable prognostic sign correlating with reperfusion.

References

1. Camilo O, Goldstein LB. Seizures and epilepsy after ischemic stroke. *Stroke* 2004;35:1769–1775.
2. Pawlak R, Strickland S. Tissue plasminogen activator and seizures: a clot-buster's secret life. *J Clin Invest* 2002;109:1529–1531.
3. Pawlak R, Melchor JP, Matys T, Skrzyriec AE, Strickland S. Ethanol withdrawal seizures are controlled by tissue plasminogen activator via modulation of NR2B-containing NMDA receptors. *Proc Natl Acad Sci USA* 2005;102:443–448.
4. Lee SK, Kim DI, Kim SY, Kim DJ, Lee JE, Kim JH. Reperfusion cellular injury in an animal model of transient ischemia. *Am J Neuroradiol* 2004;25:1342–1347.
5. Schwartz RB. Hyperperfusion encephalopathies: hypertensive encephalopathy and related conditions. *Neurologist* 2002;8:22–34.
6. Karapaniotides T, Meuli R, Devuyt G, et al. Postcarotid endarterectomy hyperperfusion or reperfusion syndrome. *Stroke* 2005;36:21–26.

Neurology[®]

Seizures during stroke thrombolysis heralding dramatic neurologic recovery

L. H. Rodan, R. I. Aviv, D. J. Sahlas, et al.

Neurology 2006;67;2048-2049

DOI 10.1212/01.wnl.0000247231.25231.2e

This information is current as of December 11, 2006

Updated Information & Services	including high resolution figures, can be found at: http://www.neurology.org/content/67/11/2048.full.html
References	This article cites 6 articles, 4 of which you can access for free at: http://www.neurology.org/content/67/11/2048.full.html##ref-list-1
Citations	This article has been cited by 2 HighWire-hosted articles: http://www.neurology.org/content/67/11/2048.full.html##otherarticles
Subspecialty Collections	This article, along with others on similar topics, appears in the following collection(s): All Cerebrovascular disease/Stroke http://www.neurology.org/cgi/collection/all_cerebrovascular_disease_stroke All Epilepsy/Seizures http://www.neurology.org/cgi/collection/all_epilepsy_seizures Infarction http://www.neurology.org/cgi/collection/infarction Prognosis http://www.neurology.org/cgi/collection/prognosis
Permissions & Licensing	Information about reproducing this article in parts (figures, tables) or in its entirety can be found online at: http://www.neurology.org/misc/about.xhtml#permissions
Reprints	Information about ordering reprints can be found online: http://www.neurology.org/misc/addir.xhtml#reprintsus

Neurology® is the official journal of the American Academy of Neurology. Published continuously since 1951, it is now a weekly with 48 issues per year. Copyright . All rights reserved. Print ISSN: 0028-3878. Online ISSN: 1526-632X.

