

SHORT REPORT

Paradoxical recovery in a bilingual patient with aphasia after right capsuloputamina infarction

A García-Caballero, I García-Lado, J González-Hermida, R Area, M J Recimil, O Juncos Rabadán, S Lamas, G Ozaita, F J Jorge

J Neurol Neurosurg Psychiatry 2007;78:89–91. doi: 10.1136/jnnp.2006.095406

We report the case of a bilingual dextral patient, who presented with an uncommon pattern of aphasic deficit following a right capsulo-putamina infarction. In this patient, the linguistic deficit concerned the use of her mother tongue (Galician, L1) much more than the lesser practised second language (Spanish, L2). Our patient presented spontaneous fluent speech in L2 but not in L1, automatic translation into L2, and impaired repetition in L1, whereas comprehension was spared in both L1 and L2. Reading and writing were less valuable due to educational interference (reduced schooling). Spontaneous speech 16 months after the stroke showed the stability of the impairment. This is the first reporting of a crossed subcortical aphasia in a bilingual patient.

Although subcortical aphasia cases in monolinguals have been extensively studied during the past decades,^{1–5} only two cases of bilingual aphasia in adults have been described after subcortical stroke. In the first case the lesion was located in the left capsuloputamina region, and the patient showed a paradoxical recovery of her less-practised second language (Italian, L2), being no longer able to speak her mother tongue (Venetan, L1).⁶ In the second case, impairment of the mother tongue (Croatian, L1) appeared after infarction of the left caudate nucleus.⁸ During follow-up, improvement of the mother tongue was accompanied by worsening of the second language (Italian, L2) after extension of the ischaemic lesion to the cortex.

Crossed aphasia is a term coined by Bramwell^{9a} in 1899 to refer to language dysfunction appearing after right hemispheric brain lesions in dextrals.⁹ The precise incidence of this type of anomalous language lateralisation is unknown, ranging from 1% to 13% of all patients with aphasia and being present in up to 38.5% of neurologically intact dextrals.^{10–11} Two types of crossed dysphasia have been described, with either dissociated or simultaneous language and visuospatial deficit due to reversed representation of hemisphere-specific functions or transfer of most cognitive functions to the right hemisphere.¹²

Subcortical crossed aphasia, although rare, have been described previously in monolinguals after infarction of the posterior limb of the internal capsule and head of the caudate nucleus, and anterior part of the internal capsule, lentiform nucleus and head of the caudate.^{13–14} Given these facts, it was thus intriguing to think how subcortical right hemisphere lesions could affect language performance in bilingual patients.

CASE REPORT

The patient is a 91-year-old, right-handed housewife who, in August 2004, suddenly stopped speaking in her most fluent and practised Galician (L1), and started to speak in her less fluent Spanish (L2). She showed no further neurological features. She had no history of hypertension, ischaemic heart disease or diabetes mellitus.

Galician is the patient's mother tongue and the language she had used all her life. She grew up and lived in a rural hamlet where only Galician was spoken. She attended 4 years of school in Spanish, although she managed to be a passionate reader, especially of religious literature in L2. She watched television 2–3 h/day (1/3 of the time in Galician and the rest in Spanish). Before the stroke she hardly ever spoke in L2; its use was restricted to speaking with some of her grandsons born in Castile when they came to visit her once or twice a year.

Initially, her family did not pay much attention to the fact that she stopped speaking in Galician. They thought this fact was related to other mild behavioural disturbances they had been noticing during the previous years. These symptoms consisted of mild disinhibition (ie she asked their guests for a cup of coffee, a cigarette or even a glass of liquor!) and fluctuating memory deficits, which were considered by her family to be a normal consequence of aging. There was no impairment of her daily living abilities, but they were just restricted to bathing, dressing and reading religious literature (in L2). Four months after the episode of language switch, an in-law of the patient who was a young trainee, reported the case to us and asked for a cognitive evaluation to discount dementia.

Neurological examination

The general physical examination was unremarkable. She showed no hemiparesis or hypoesthesia. Tendon reflexes were symmetrical and Babinski sign was absent. Strikingly, she continued speaking Spanish during the evaluation, although her daughter and the doctor spoke to her in L1.

Neuroimaging

A magnetic resonance imaging study performed in January 2005 showed a right capsuloputamina infarction (figs 1 and 2). Severe corticosubcortical atrophy (figs 1 and 2) and small lesions of the subcortical white matter were also present bilaterally.

Neuropsychology

Neuropsychological examination was performed in L2. She was right handed when assessed by the Edinburgh Handedness Inventory (laterality quotient +100).¹⁵ She was evaluated using the Spanish version of the Addenbrooke's Cognitive Examination (ACE).¹⁶ ACE score was 65/100. She scored 26/30 in the Spanish version¹⁷ of the Mini-Mental Status Examination.¹⁸ She was oriented in time and space. Memory was apparently unaffected, because she remembered three out of three words after 5 min and correctly named the current and former President and the Pope's name. Learning curve of a list of 10 unrelated words was considered normal for her age and educational level.¹⁹ Five trials were allowed (3–3–4–6–7) and a delayed recall 5 min later (six correct words).¹⁹ Afterwards she was shown a recognition list where she correctly identified the words of the first list and

Abbreviations: ACE, Addenbrooke's Cognitive Examination; L1, mother tongue; L2, second language

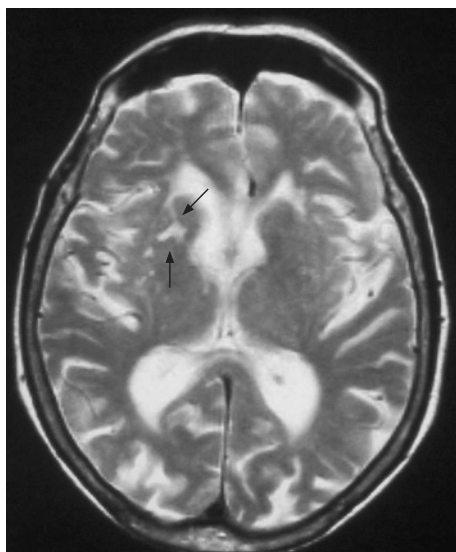


Figure 1 Magnetic resonance image executed 6 months after the onset, showing a right capsuloputamenal infarct.

correctly refused the confusion items. Verbal fluency was impaired (animals: 6; letter p: 4) and mixed items in L1 and L2. She showed a constructional apraxia on both copy (pentagons) and free-hand drawing. The clock drawing test following ACE's instructions was severely impaired.²⁰ Her writing to command (L2) was impaired, showing agrammatisms and spelling errors (letter omission). These features were less valuable because of educational interference. She was not able to perform serial seven subtractions or its easier Spanish counterpart, serial three subtractions. Clinical Dementia Rating Scale score was 0.5 (questionable impairment).²¹

Remarkably, 1 year later her cognitive status remained stable, her Mini-Mental Status Examination scored 27, and she kept performing the same daily activities.

One and a half years after the first neuropsychological evaluation, the learning curve of a list of 10 unrelated words was repeated.¹⁹ Five trials were allowed (3–5–5–6–7) and a delayed recall 5 min later (seven correct words).¹⁹ Later, she

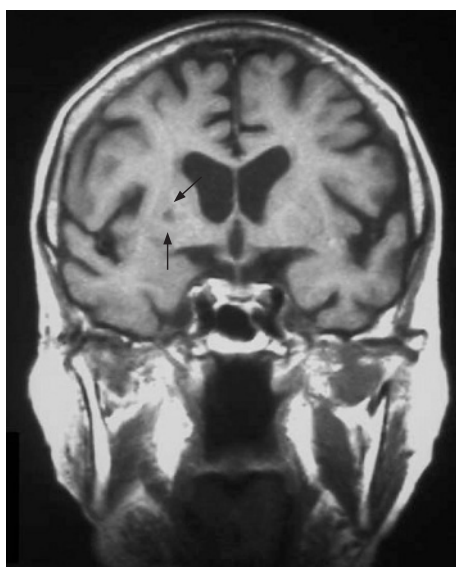


Figure 2 Coronal section magnetic resonance image showing a right putamenal lacunar infarct (arrows) and corticosubcortical atrophy. Head of the caudate nucleus is not affected.

was shown a recognition list where she correctly refused the confusion items, missing two items of the first list.

Finally, to differentiate genuine memory deficits from apparent memory deficits due to inefficient strategies and impaired attention, an enhanced cued recall test was used.²² In this case, we used the Spanish version of the free and cued learning test,²³ included in the 7-min neurocognitive screening battery.²⁴ Free recall was 6/16, cued recall was 8/16 and total score was 14/16, a performance considered normal for her age and educational level (between the 50th and 60th centiles).²³ It has to be noted that her cued recall 10 min later was 15/16.

Language tasks

In December 2004, our patient did not produce spontaneous speech in her mother tongue and only on request would she translate simple single words but not phrases. She showed spontaneous translation into L2 when repeating words and phrases in L1. This was also true for repetition of well-known refrains in L1. Reading was impaired in L1 but not in L2. On the other hand, comprehension was spared in both L1 and L2 (table 1).

One year later she was given the Galician²⁵ and the Spanish²⁶ version of the Bilingual Aphasia Test. Table 1 summarises the results. There was a high percentage of words (97%) in the non-requested language (L2) during sessions in L1; by contrast, words in L1 were absent during sessions in L2. There were no differences in reading, repetition, naming and comprehension tasks.

DISCUSSION

Studies on bilingual aphasia have suggested that dominant basal ganglia lesions impair access to the mother tongue while sparing L2.^{6,7} This was coherent with a hypothesis posed by Paradis,²⁷ who suggested that, given that L1 uses unconscious learning strategies typical of implicit memory, it should be anatomically organised in cortical and subcortical structures that differ from those implicated in L2, generally learnt by means of conscious strategies, typical of explicit memory. Given that basal ganglia are involved in implicit (unconscious-repetitive) memory but not in explicit (conscious-single exposition) memory and also in language organisation, a lesion of the basal ganglia should impair L1 but not L2.⁶ Moreover, it has been suggested that grammatical operations in L1 might be sensitive to basal-ganglia prefrontal cortex network dysfunction present, for instance, in patients with Parkinson's disease.²⁸

Galician is a romance language different from Spanish, which belongs to the Iberian romance family of languages. It has common aspects with Portuguese (morpho and some vocabulary). From the linguistic point of view, the boundaries of the Galician

Table 1 Patient's performance during the initial evaluation and 1 year later using the Bilingual Aphasia Test

	Number of correct items (total trials)	
	L1	L2
Initial evaluation		
Spontaneous speech (total number of words in 5 min)	5	209
Repetition	16 (21)	23 (23)
Word reading	1 (6)	6 (6)
One year later (BAT results)	L1	L2
Spontaneous speech (dialogue in L1; total number of words in 5 min)	11	356
Spontaneous speech (dialogue in L2; total number of words in 5 min)	0	387
Repetition	22 (25)	25 (25)
Word reading	7 (10)	10 (10)
Naming	9 (10)	10 (10)
Auditory comprehension	7 (9)	9 (9)

BAT, Bilingual Aphasia Test; L1, mother tongue; L2, second language.

language are: Portuguese in the South and Astur-Leonese in the East. Galicia has a population of 2.7 million inhabitants, 94% of the population understand Galician and 88% speak it.²⁹ Traditionally, Galician was spoken in everyday life, whereas Spanish was limited to formal contexts. During Franco's régime, the Galician language was banned and therefore formal education in Galician was prohibited until the 1980s. Owing to this sociolinguistic situation, the patient never learnt to read or write in the Galician language. In the patient's case, Galician was the only language she was mainly exposed to until she went to school at the age of 8 years. The reason is that she was born and lived in a very small hamlet made up of just a few farms. This relative isolation resulted in a restricted exposure to the Spanish language. These questions are relevant, because native language grammar is acquired implicitly with involvement of basal ganglia structures that are mature at birth, whereas syntactic skills in L2 are learnt by using declarative memory, which mainly relies on temporal systems that complete their maturation in later infancy.²⁸ It is also relevant because reading and writing in Galician is not valuable or useful for comparisons. The same is true for other tasks such as discrimination between words and pseudowords,³⁰ or phonetic oral fluency,³¹ tasks that require phonemic awareness.

From the clinical point of view, it can be argued that the behavioural disturbances the patient showed were prodromal features of a degenerative disorder. However, serial neuropsychological testing dealing with memory deficits showed no deterioration over a follow-up period of 1½ years. Moreover, enhanced cued recall, a well-known measure to avoid educational and attentional bias,²² was normal given her age and educational level.²³ Visuoconstructional tasks are less valuable in a patient with only 4 years of formal education.³² These facts, in our opinion, rule out an Alzheimer's-type dementia. Accordingly, a frontotemporal dementia seems improbable given her age and clinical features; it is more reasonable to attribute her mild disinhibition to vascular disruption of frontosubcortical circuits. Vascular changes have been demonstrated by magnetic resonance imaging, and a vascular aetiology of the language switch is not only probable, given a compatible lesion in the right capsuloputamen region, but likely, given the sudden onset of the language impairment and its evolution during the next year.

The case we report was clinically similar to those reported in the literature,^{6–8} but the patient's lesion was the mirror image of what should be expected.

Cases of subcortical crossed aphasia, although rare, have been described previously in monolinguals,^{13–14} but as far as we know this is the first report of the occurrence of a subcortical crossed aphasia in a bilingual. As we have seen, our findings support the hypothesis that basal ganglia are essential nodes in the neural network subserving the mother tongue.

ACKNOWLEDGEMENTS

We thank the patient and her daughter for their collaboration.

Authors' affiliations

A García-Caballero, I García-Lado, J González-Hermida, M J Recimil, S Lamas, Servicio de Psiquiatría, Complejo Hospitalario de Ourense, Ourense, Spain
R Area, Servicio de Psiquiatría, Complejo Hospitalario Xeral-Calde, Lugo, Spain
O Juncos Rabadán, Departamento de Psicología Evolutiva e da Educación, Universidade de Santiago de Compostela, Santiago de Compostela, Spain
G Ozaita, Servicio de Neurología, Complejo Hospitalario de Ourense, Ourense, Spain
F J Jorge, Departamento de Ciencias Morfológicas, Universidade de Santiago de Compostela, Santiago de Compostela, Spain

Competing interests: None declared.

Informed consent has been obtained for publication of the patients' details in this paper.

Correspondence to: Dr A García-Caballero, Servicio de Psiquiatría, Complejo Hospitalario de Ourense, R/ Ramon Puga 54, 32001, Ourense, Spain; Alejandro.Garcia.Caballero@sergas.es

Received 10 April 2006

Revised 9 July 2006

Accepted 17 July 2006

REFERENCES

- 1 **Damasio AR**, Damasio H, Rizzo M, *et al*. Aphasia with nonhemorrhagic lesions in the basal ganglia and internal capsule. *Arch Neurol* 1982;**39**:15–20.
- 2 **Naeser MA**, Alexander MP, Helm-Estabrooks N, *et al*. Aphasia with predominantly subcortical lesion sites: description of three capsular/putamen aphasia syndromes. *Arch Neurol* 1982;**39**:2–14.
- 3 **Weiller C**, Wilmes K, Reiche W, *et al*. The case of aphasia or neglect after striatocapsular infarction. *Brain* 1993;**116**:1509–25.
- 4 **Mega MS**, Alexander MP. Subcortical aphasia: the core profile of capsulostriatal infarction. *Neurology* 1994;**44**:1824–9.
- 5 **D'Esposito M**, Alexander MP. Subcortical aphasia: distinct profiles following left putamenal hemorrhage. *Neurology* 1995;**45**:38–41.
- 6 **Aglioti S**, Fabbro F. Paradoxical selective recovery in a bilingual aphasic following subcortical lesions. *Neuroreport* 1993;**4**:1359–62.
- 7 **Aglioti S**, Beltramello A, Girardi F, *et al*. Neurolinguistic and follow-up study of an unusual pattern of recovery from bilingual subcortical aphasia. *Brain* 1996;**119**:1551–64.
- 8 **Moretti R**, Bava A, Torre P, *et al*. Bilingual aphasia and subcortical-cortical lesions. *Percept Mot Skills* 2001;**92**:803–14.
- 8a **Bramwell B**. On crossed aphasia and the factors which go to determine whether the 'leading' or 'driving' speech-centres shall be located in the left or in the right hemisphere of the brain, with notes of a case of 'crossed aphasia' (aphasia with right-side hemiplegia) in a left-handed man. *Lancet* 1899;i:1473–9.
- 9 **Kirsher HS**. *Handbook of neurological speech and language disorders*. New York: Marcel Dekker, 1995.
- 10 **Alexander MP**, Annet M. Crossed aphasia and related anomalies of cerebral organization: case reports and a genetic hypothesis. *Brain Lang* 1996;**55**:213–39.
- 11 **Pujol J**, Deus J, Losilla JM, *et al*. Cerebral lateralization of language in normal left-handed people studied by functional MRI. *Neurology* 1999;**52**:1038–43.
- 12 **Kapur N**, Dunkley B. Neuropsychological analysis of a case of crossed dysphasia verified at postmortem. *Brain Lang* 1984;**23**:134–47.
- 13 **Sapir S**, Kokmen E, Rogers PJ. Subcortical crossed aphasia: a case report. *J Speech Hear Disord* 1986;**51**:172–6.
- 14 **Dobrzynska J**. Crossed aphasia in right handed patients. *Neurol Neurochir Pol* 1991;**25**:31–9.
- 15 **Oldfield RC**. The assessment and analysis of handedness: The Edinburgh inventory. *Neuropsychologia* 1971;**9**:97–113.
- 16 **García-Caballero A**, García-Lado I, González Hermida J, *et al*. Validation of the Spanish version of the Addenbrooke's cognitive examination in a rural community in Spain. *Int J Geriatr Psychiatry* 2006;**21**:1–7.
- 17 **Lobo A**, Saz P, Marcos G, *et al*. Revalidación y normalización del Mini-Examen Cognoscitivo (primera versión en castellano del mini-mental status examination) en la población general geriátrica. *Med Clin (Barc)* 1999;**112**:767–74.
- 18 **Folstein MF**, Folstein SE, McHugh PR. Mini-mental state. A practical method for grading the cognitive state of patients for the clinician. *J Psychiatr Res* 1975;**12**:189–98.
- 19 **Christensen AL**. *El diagnóstico neuropsicológico de Luria*, 2.ª ed. Madrid: Visor, 1987.
- 20 **García-Caballero A**, Recimil MJ, García-Lado I, *et al*. The ACE clock scoring. A comparison with eight standard correction methods in a population of low-educational level. *J Geriatr Psychiatry Neurol* 2006;**19**:216–19.
- 21 **Hughes CP**, Berg L, Danzinger WL, *et al*. A new clinical scale for staging of dementia. *Br J Psychiatry* 1982;**140**:566–72.
- 22 **Grober E**, Buschke H, Crystal H, *et al*. Screening for dementia by memory testing. *Neurology* 1988;**38**:900–03.
- 23 **Del Ser T**, Sánchez Sánchez F, García de Yébenes MJ, *et al*. Versión española del Test de los 7 Minutos. Datos normativos de una muestra poblacional de ancianos de más de 70 años. *Neurología* 2004;**19**:344–58.
- 24 **Solomon PR**, Hirschhoff A, Kelly B, *et al*. A 7 minute neurocognitive battery highly sensitive to Alzheimers disease. *Arch Neurol* 1998;**55**:349–55.
- 25 **Paradis M**, González M, Juncos O, *et al*. *Test da afasia nos bilingües*, Galician Version. Hillsdale, NJ: Lawrence Erlbaum Associates, 1989.
- 26 **Paradis M**, Elias J. *Test de afasia para bilingües*, European Spanish Version. Hillsdale, NJ: Lawrence Erlbaum Associates, 1989.
- 27 **Paradis M**. Neurolinguistic aspects of implicit and explicit memory: implications for bilingualism and second language acquisition. In: Ellis NC, eds. *Implicit and explicit learning of languages*. London: Academic Press, 1994:393–419.
- 28 **Zanini S**, Tavano A, Vorano L, *et al*. Greater syntactic impairments in native language in bilingual Parkinsonian patients. *J Neural Neurosurg Psychiatry* 2004;**75**:1678–81.
- 29 **Sousa X**. Galician. Introductory page. <http://www.usc.es/~ilgas/galicianhtml>, 1995.
- 30 **Castro-Caldas A**, Petersson KM, Reis A, *et al*. The illiterate brain. Learning to read and write during childhood influences the functional organization of the adult brain. *Brain* 1998;**121**:1053–63.
- 31 **Ratcliff G**, Ganguli M, Chandra V, *et al*. Effects of literacy and education on measures of word fluency. *Brain Lang* 1998;**61**:115–22.
- 32 **Ostrosky F**, Ardila A, Rosselli M, *et al*. Neuropsychological test performance in illiterates. *Arch Clin Neuropsychol* 1998;**13**:645–60.