

EMERGENCY CASEBOOK

Case of the month: Transient global amnesia caused by painless aortic dissection

K Mondon, C Blechet, A Gochard, D Elaroussi, F Fetissof, B De Toffol, A Autret, C Hommet

Neurological syndromes secondary to acute aortic dissection (AAD) are uncommon and usually consist of focal deficits after an embolic cerebral infarction. This article reports the observation of an AAD with the chief complaint of transient acute memory impairment—that is, a non-usual stroke-like symptom.

A 69-year-old retired woman presented to the hospital because of an acute memory disorder that abruptly appeared 2 h before. The patient's medical history included appendectomy, rhinoplasty, bilateral breast implants, hypothyroidism, cervical arthrosis and mild mood depression. The patient's usual drugs included fluoxetine (20 mg/day), bromazepam (1.5 mg/day) and levothyroxine (75 µg/day).

On physical examination, the patient's temperature was 36.5°C, blood pressure was 110/50 mm Hg and heart rate was 55 beats/min. The remainder of her physical examination was normal: she denied any pain in her chest, neck, back or abdomen. The heart sounds were normal, without murmur, gallop or rub. A pulmonary examination showed no jugular venous distension and breath sounds were equal bilaterally. Pulses were not searched.

Emerg Med J 2007;24:63–66. doi: 10.1136/emj.2006.040881

On neurological examination, the patient was severely disoriented in time and slightly in place. She presented a complete anterograde amnesia, whereas short-term and retrograde memories were intact. Consciousness was clear. The reasoning was perfect, without fluctuation over the course of the day. There was no confabulations, hallucinations or paranoid ideas. She had no loss of motor or sensory function. Deep-tendon reflexes were present.

The white cell count was 22 400 cells/mm³, with 92% neutrophils, 0.67% lymphocytes, 0.9% monocytes and 0 eosinophils; the haemoglobin concentration was 11.8 g/dl; and the platelet count was 196 000 cells/mm³. The creatine kinase concentration was 220 U/l. Levels of electrolytes were normal. The serum creatinine concentration was 151 µmol/l. Erythrocyte sedimentation rate or C reactive protein level was not raised. A chest radiograph showed no abnormality (fig 1A). An electrocardiogram showed sinus rhythm, with no evidence of ischaemia or infarction. Cranial computed tomography without the administration of intravenous contrast material showed no abnormality.

Abbreviations: AAD, acute aortic dissection; TGA, transient global amnesia

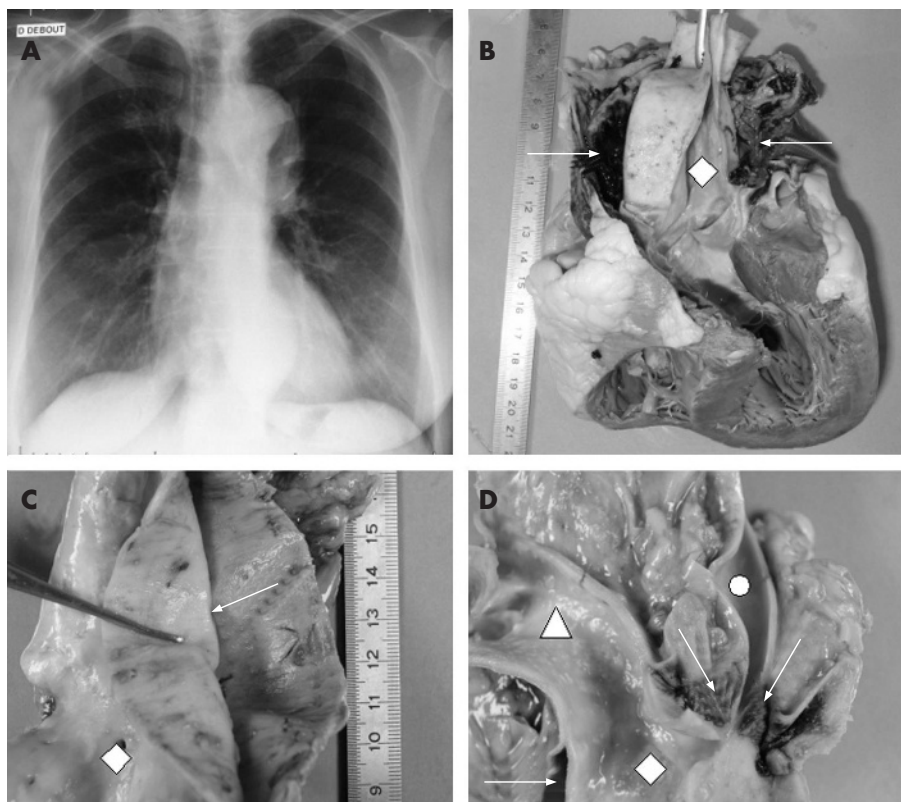


Figure 1 (A) Chest radiograph of the patient. (B) Heart: frontal section through aorta. (C) Aortic walls, delimiting false lumen (thoracic portion). (D) Aortic cross, showing preservation of cervical arteries. Diamond: aortic lumen; circle: right primitive carotid; arrows: false lumen; triangle: brachiocephalic trunk.

The patient's neurological symptoms resolved completely during the next 10 h. She was fully oriented and cooperative, but biological abnormalities were still present and her temperature was 38.0°C. Examination of the cerebrospinal fluid showed a normal concentration of protein (0.40 g/l) and glucose, with lymphocyte 1/mm³ and red cells 50/mm³. Cervical ultrasound examination with colour flow imaging was normal. Before complete installation of electrodes for electroencephalography, the patient suddenly died.

An autopsy was proposed and accepted by the patient's family.

The postmortem examination showed DeBakey type I aortic dissection (fig 1B,C), without involvement of cervical arteries (fig 1D), which caused cardiac tamponade. The brain was not examined because of tardive delay of autopsy (4 days).

DISCUSSION

To our knowledge, this report describes the third reported case of an AAD presenting with the chief complaint of transient global amnesia (TGA). In the other two cases, focal neurological symptoms were associated (motor deficits) and orientated investigations.¹ Thus, this is the first case report presenting a patient with a "pure TGA" syndrome.

Diagnostic criteria of TGA are witnessed attacks, clear-cut anterograde amnesia during the attack, absent clouding of consciousness and loss of personal identity, no accompanying focal neurological symptoms or epileptic features, resolution of attacks in 24 h, and no recent head injury or active epilepsy.² Patients usually have repetitive questioning and there may be some confusion.³ Generally, the maximum duration of amnesia in TGA is 12 h.⁴

Abrupt onset and regressive memory impairment with massive anterograde amnesia are rare, and the general consensus is that the amnesic disorder results from transient dysfunction in the limbic-hippocampal circuits, crucial to memory formation. The dysfunction is often related to idiopathic TGA, but epileptic (transient epileptic amnesia) or vascular (bilateral temporal infarction during vertebrobasilar stroke, transient venous ischaemia) origin is possible.³

Acute neurological syndromes secondary to AAD are uncommon and usually consist of stroke or global cerebral

hypoperfusion.⁵ In our observation, the two mechanisms can be evoked, but complete regression of symptoms after 12 h is not in favour of constituted lesions.

Retrospectively, fever, hyperleucocytosis and atypical neurological symptoms were evocative of AAD. Absence of examination of the pulse is crucially missing in our observation, even if pulse deficits are not frequent (22%).⁶

The absence of the important cardinal symptom "pain" may misdiagnose AAD. Painless AAD occurs rarely: in a series of 977 patients, Park *et al*⁶ observed only 63 (6.4%) patients with painless AAD.

AAD seems to mimic a large group of neurological symptoms, including TGA. This eventuality may be considered even without chest pain, and examination of the pulse should be recommended systematically.

Authors' affiliations

K Mondon, A Gochard, B De Toffol, A Autret, C Hommet, Department of Neurology, University Hospital, Tours, France

C Blechet, F Fetissov, Department of Pathology, University Hospital, Tours, France

D Elaroussi, Department of Neurosurgery, University Hospital, Tours, France

Competing interests: None declared.

Correspondence to: Dr K Mondon, Service de Neurologie, Hôpital Bretonneau, 37044 Tours Cedex, France; karl.mondon@med.univ-tours.fr

Accepted 14 August 2006

REFERENCES

- 1 **Gaul C**, Dietrich W, Tomandl B, *et al*. Aortic dissection presenting with transient global amnesia-like symptoms. *Neurology* 2004;**63**:2442-3.
- 2 **Hodges JR**, Warlow CP. Syndromes of transient amnesia: towards a classification. A study of 153 cases. *J Neural Neurosurg Psychiatry* 1990;**53**:834-43.
- 3 **Kopelman MD**. Disorders of memory. *Brain* 2002;**125**(Pt 10):2152-90.
- 4 **Miller JW**, Petersen RC, Metter EJ, *et al*. Transient global amnesia: clinical characteristics and prognosis. *Neurology* 1987;**37**:733-7.
- 5 **Fann JJ**, Sarris GE, Miller DC, *et al*. Surgical management of acute aortic dissection complicated by stroke. *Circulation* 1989;**80**(Pt 1):1257-63.
- 6 **Park SW**, Hutchison S, Mehta RH, *et al*. Association of painless acute aortic dissection with increased mortality. *Mayo Clin Proc* 2004;**79**:1252-7.

IMAGES IN EMERGENCY MEDICINE

Calcified cervical disc in a three year old

A 3-year-old boy presented with a flexed neck over a period of 24 h. No history of trauma was observed and neurological examination was normal. An x ray of the lateral cervical spine showed disc calcification at C5/C6 (fig 1 arrow) with no evidence of a herniated disc. Calcified cervical intervertebral discs are rare in children and are due to a disease of unknown aetiology. Signs of nerve-root pain or spinal cord compression are unusual. Acute symptoms last for 2-3 weeks leading to a spontaneous recovery as in this case.

**J Acheson
P J Sell
A Rickett**

Emergency Department, Leicester Royal Infirmary, Leicester, UK

Correspondence to: Jonathan Acheson, SpR Emergency Department, Leicester Royal Infirmary, Infirmary Square, Leicester, LE1 5WW, UK; achesonjonny@hotmail.com

doi: 10.1136/emj.2006.036319

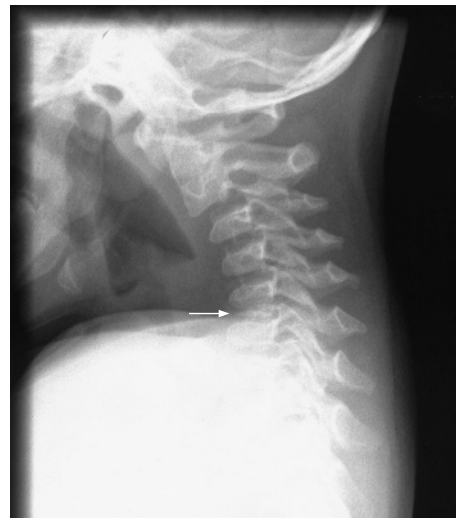

Figure 1 An x ray of the lateral cervical spine showed disc calcification at C5/C6 (arrow) with no evidence of a herniated disc.