

Primary Spinal Primitive Neuroectodermal Tumor: Case Series and Review of the Literature

Raj Kumar S.J. Reddy A.A. Wani L. Pal

Departments of Neurosurgery and Pathology, Sanjay Gandhi Postgraduate Institute of Medical Sciences, Lucknow, India

Key Words

Primitive neuroectodermal tumor, primary spinal · Embryonal tumors

Abstract

Primary spinal primitive neuroectodermal tumor (PSPNET) is extremely rare and only 25 cases have been reported in the world literature so far. Three patients of 8, 9 and 18 years of age, who presented with variable grades of neurological deficit were diagnosed as having a dorsal intramedullary lesion, a holocord lesion and cervical extradural tumor with extraspinal extension, respectively, and were operated at our institute. The histopathology of all 3 children revealed PNET. The clinical course, image characteristics and outcome of the 3 children are described, and the relevant literature is reviewed. The following conclusions were drawn from the present study and review of the literature. PNET may manifest itself as a primary lesion of the spine unlike the more common drop metastases from an intracranial lesion. PSPNET may be intramedullary, intradural and extradural with variable extraspinal extension. PSPNET may present as holocord intramedullary lesion, an entity which has not been described earlier. These lesions have a short history, significant neurological deficits and rapid course of illness. PSPNET, though an established entity, did not find a place in the WHO 2000 classification of CNS tumors. Hence its status has to be defined.

Copyright © 2007 S. Karger AG, Basel

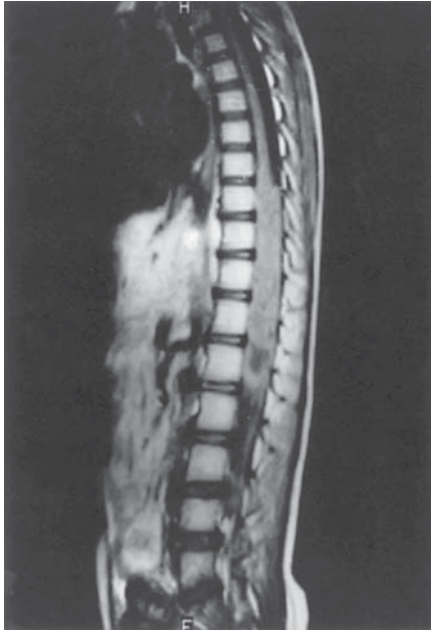
Introduction

With the increasing awareness and use of immunohistochemistry (IHC), primary spinal primitive neuroectodermal tumor (PSPNET) is increasingly reported. PSPNET is an extremely rare lesion, and only 25 cases have been reported in the world literature so far. Of the 25 cases, 20 have been reported during the last 8 years, though the concept of PNET was described as early as in 1973 [1]. PNET is a broad term that encompasses all embryonal tumors in the CNS that are composed of undifferentiated or poorly differentiated neuroepithelial cells which may have divergent differentiation including neuronal, astrocytic, ependymal, muscular or melanocytic cell lines [2]. Though the clinicoradiological profile and course of PNET are variously described for cranial tumors, little literature is available on PNET of the spine. We report 3 cases of PSPNET and describe the clinical, pathological and radiological characteristics and the outcome of these lesions. We also review the literature with a stress on the evolution and existing controversies of PNET.

Material and Methods

Three diagnosed cases of PSPNET were reviewed retrospectively in view of their rare pathology. These 3 children were managed in our department between January 2002 and December

1



2

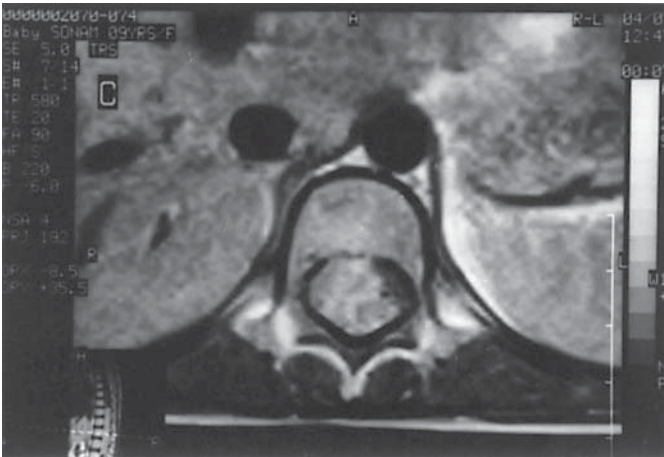


Fig. 1, 2. Preoperative sagittal (1) and axial (2) T₂-weighted MRI showing presence of intramedullary tumor (case 1).

2004. The records of the 3 cases were well maintained in view of their rarity. Clinical profiles of all 3 cases were retrieved from computer database and case files. Follow-up of all 3 cases was maintained by the operating surgeon. A brief summary of the 3 cases is presented below. Cranial imaging of all 3 children was carried out postoperatively to rule out the dissemination from intracranial lesions. Two children received craniospinal radiotherapy postoperatively. The safe doses of radiation were calculated by weight and age of both cases. These 2 children were treated by adjunctive chemotherapy also, which consisted of vincristine weekly during radiotherapy followed by vincristine, cisplatin and CCNU for 8 cycles with an interval of 4–6 weeks between each cycle. One child (case 2) did not receive postoperative radiotherapy/chemotherapy on account of financial reasons.

Case Reports

Case 1

A 9-year-old girl presented with progressive numbness and weakness of both lower limbs of 2 months duration preceded by a bout of low-grade fever for 10–15 days. There was also a history of progressive thinning of the right lower limb for 4 weeks and the left lower limb for 2 weeks. The patient had become bedridden due to the weakness. There was no history of bladder or bowel involvement. On examination, wasting and decreased tone were noted in both lower limbs. Power in the proximal muscle groups of the right lower limb was Medical Research Council (MRC) grade 2/5, distally 0/5 and on the left side proximally 3/5 and distally 2/5. There was 30% hypoesthesia below the D₈ level with no sensory dissociation or sacral sparing. MRI of the spine revealed a heterogeneously enhanced lesion isointense on T₁- and hyperintense on T₂-weighted images which was expanding the cord opposite D₉ to the L₁ vertebral level (fig. 1, 2). The differential diagnosis of ependymoma and astrocytoma was considered. At surgery, a subpial lesion was seen which had a poor plane of cleavage from the rest of the cord tissue. The tumor was soft grayish, vascular, suckable at places, compressing and shifting the cord to the left. Gross total decompression was done (fig. 3). Postoperatively there was partial improvement in the deficits. Histopathology of the lesion revealed PNET. A cranial screening CT scan was done which did not reveal any lesion. The child received craniospinal radiotherapy and chemotherapy. There was no progression of the disease at the end of 18 months.

Case 2

An 8-year-old boy presented with a painful neck swelling on the right side of the neck of 5 months duration followed by progressive spastic quadriparesis with distal to proximal progression with no bladder or bowel involvement of 1 month duration. The child had become bedridden for 15 days. On examination tone was increased in all the limbs except in the right upper limb. Power in the right upper limb was MRC grade 0/5 and in the remaining limbs it was MRC grade 2–3/5. MRI revealed an extramedullary lesion with extradural spread along the neural foramen, which was isointense on T₁- and hyperintense on T₂-weighted images, which was extending from the C₂ to C₄ vertebral level placed on the right side (fig. 4). A provisional diagnosis of neurofibroma was made. Through a C₁-to-C₄ laminectomy, a gross total excision was achieved. The tumor was soft, vascular, completely extradural and infiltrating the exiting C₂ and C₃ nerve roots and also the neck muscles. Histopathology revealed it as PNET. By the seventh postoperative day, the patient was ambulatory without support. Due to socioeconomic problems the patient did not receive any adjuvant therapy and had a recurrence of symptoms at 8 months with reappearance of myelopathy.

Case 3

An 18-year-old male presented with progressive dorsal pain and progressive weakness of both lower limbs for 4 months and of the upper limbs for 3 months. Because of weakness the patient had become bedridden for 3 months. He had also been urine and stool incontinent for 2 months. On examination, there was hypotonia in all the limbs. Power in the upper limbs was MRC grade 3/5 and in the lower limbs 0–1/5. Below C₂ the boy had a hypoesthesia of 50–60% and a decreased anal tone.

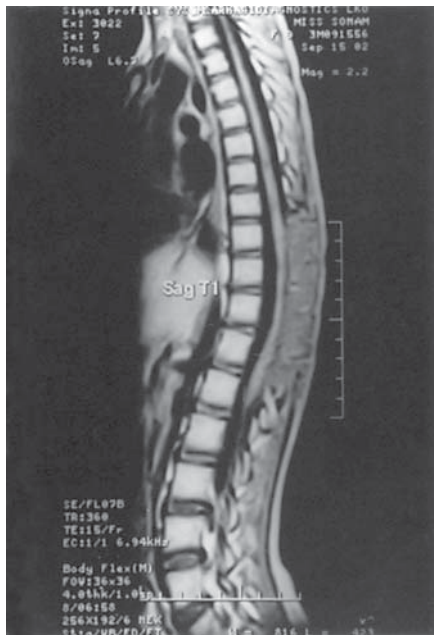


Fig. 3. Postoperative scan of case 1 showing near total excision of the tumor.

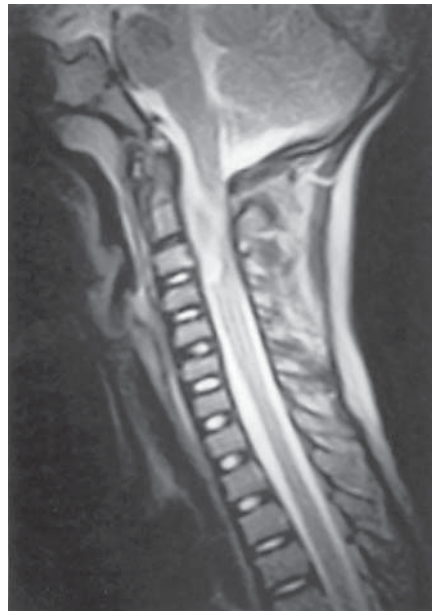

Fig. 4. Sagittal T₂-weighted MRI showing the extent of the tumor in case 2.

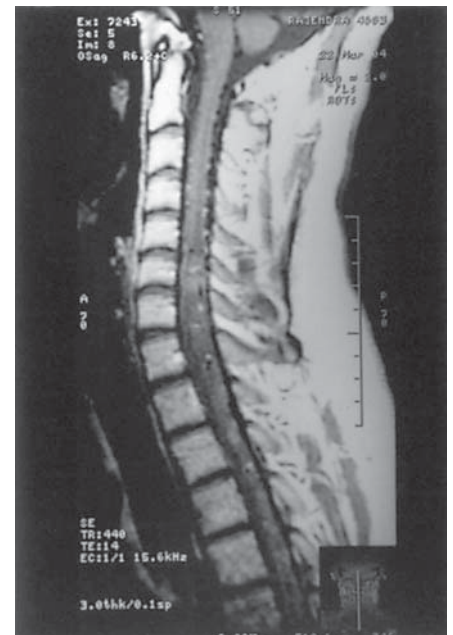


Fig. 5. Contrast-enhanced sagittal MRI study showing enlargement of the cord with patchy enhancement and flow voids (case 3).

On MRI, the cord was expanded from C₃ below. Multiple hypointense spots on T₁- and T₂-weighted images were seen throughout the cord suggestive of flow voids. Since the lesion appeared to be either arteriovenous malformation or hemangioblastoma, spinal angiography was done to rule out the vascular lesion/mass. There was patchy enhancement of the entire cord (fig. 5) with an area of relatively intense enhancement at the D₅ vertebral level. Through a D₄-to-D₇ laminectomy, an intramedullary lesion was noted which was vascular with exophytic areas into the intradural space. It was very vascular and only a biopsy could be taken, which revealed PNET (fig. 6, 7). The patient received radiotherapy and chemotherapy, and there was stabilization of symptoms at 6 months of follow-up.

Discussion

On searching Pubmed, 25 cases have been reported so far. An overview is given in table 1.

Evolution of the Concept of PNET and Its Present Status

Hart and Earle [1] introduced the term PNET in 1973 to describe pediatric cerebral neoplasms largely consisting of undifferentiated cells that did not fit into any of the classes described by Rubenstein [2]. The concept was

broadened by Rorke [22] who classified all CNS tumors with a predominant undifferentiated primitive cell component including medulloblastoma as PNET. This broad view has been further refined concerning the type of differentiation. However, the widely accepted recent WHO (2000) classification avoids controversy by including only those supratentorial embryonal tumors that cannot be grouped under ependyoblastoma or pineablastoma. This classification – though very extensive and comprehensive – makes no mention of PSPNET. The next revision of the WHO classification of CNS tumors may include the well-established entity of PSPNET.

Characteristic Pathology

Histopathology of PNET and IHC. (1) Poorly differentiated small round/spindle-shaped cells. (2) Architecture: either densely packed or placed in sheets or nests. (3) Cells are generally positive for neuronal markers like neuron-specific enolase; it could be for precursor intermediate filaments like nestin, vimentin or microfilaments; synaptophysin or GFAP may be positive depending on the differentiation of the cells; S-100 is also commonly positive. (4) In case of undifferentiated cells, they may not stain positive for any analyses.

Table 1. Summary of the reported cases

SI No.	Authors	Age/sex	Level	Location	Metastases	Survival months
1	Smith et al. [3]	24 years/M	lumbar	cauda equina	lung	10
2	Kosnik et al. [4]	<10 years/n.a.	cervical	unknown	none	n.a.
3	Kosnik et al. [4]	<10 years/n.a.	cervical	unknown	none	n.a.
4	Kosnik et al. [4]	<10 years/n.a.	thoracolumbar	unknown	lung, bone, lymph node	n.a.
5	Kepes et al. [5]	24 years/M	lumbar	cauda equina	none	18
6	Kepes et al. [5]	56 years/M	lumbar	cauda equina	none	alive at 36
7	Kepes et al. [5]	39 years/M	lumbar	cauda equina	none	42
8	Liu et al. [6]	26 years/F	lumbosacral	extradural	none	alive at 6
9	Sevick et al. [7]	26 years/M	cervical	intradural extramedullary	pleura, bone, lymph nodes	36
10	Jakse et al. [8]	15 years/F	thoracolumbar	intra- and extramedullary	none	18
11	Jakse et al. [8]	26 years/M	lumbar/thoracic	cauda equina/intra- and extramedullary	none	36
12	Freyer et al. [9]	7 years/M	thoracolumbar	intramedullary	none	20
13	Ogasawara et al. [10]	16 years/F	lumbar	intramedullary	intracranial	29
14	McDermott et al. [11]	47 years/M	lumbar	cauda equina	none	16
15	Kwon et al. [12]	3 months/F	midthoracic	intramedullary	intracranial	<1
16	Deme et al. [13]	22 years/F	thoracolumbar	intramedullary	none	alive at 15
17	Koot et al. [14]	2 years/F	cervical	–	–	<1
18	Rodriguez et al. [15]	16 years/M	–	–	–	–
19	Virani and Jain [16]	4 years/M	thoracic + mediastinal	extradural	none	alive at 8
20	Marwin et al. [17]	69 years/M	dorsal	intramedullary	none	–
21	Albrecht et al. [18]	19 years/F	lumbar	intradural, intra-spinal relapse	local recurrence and leptomeningeal	23
22	Albrecht et al. [18]	29 years/F	thoracic	intradural, intra-spinal relapse	local recurrence and leptomeningeal	17
23	Yuvaz et al. [19]	18 years/F	lumbar	extramedullary	none	alive at 25
24	Aydin et al. [20]	14 years/M	thoracic	extradural	none	–
25	Kim et al. [21]	17 years/M	thoracolumbar	intramedullary	none	–
<i>Present series</i>						
26	Case 1	9 years/F	thoracic	extramedullary	none	alive at 24
27	Case 2	8 years/M	cervical	extradural	local recurrence	recurrence at 6
28	Case 3	18 years/M	holocord	intramedullary	none	alive at 6 weeks

The cell of origin is still not defined whether it is an internal granule cell of the cerebellum or an undifferentiated cell common to all portions of the nervous system [23].

The revised WHO classification of CNS tumors which was expected in 2005 should help in resolving the present controversy, as with the routine use of IHC and electron microscopy, more data will be available in days to come.

Primary Spinal PNET

PSPNET can occur in any group. The age range is 3 months to 69 years. The mean age is 24 years. Because this

is much older than the average age of manifestation of intracranial PNET, spinal PNET appears to be more common in adults than in children. All our 3 patients were children (<20 years). There is a slight male predominance (18 out of 28). It can involve any part of the spine and can be intra- or extradural. Two of our patients had intramedullary and the other had extradural lesions. One of our patients had a holocord involvement which has not been reported before (case 3).

Like other malignant spinal lesions, history is short. All cases had had symptoms for less than 4 months. This

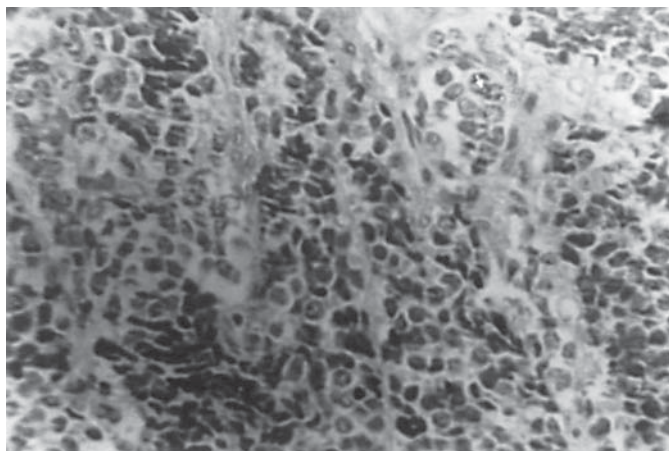


Fig. 6. Photomicrograph of HE-stained section showing presence of monomorphic round cells arranged in sheets and nests. Magnification $\times 100$.

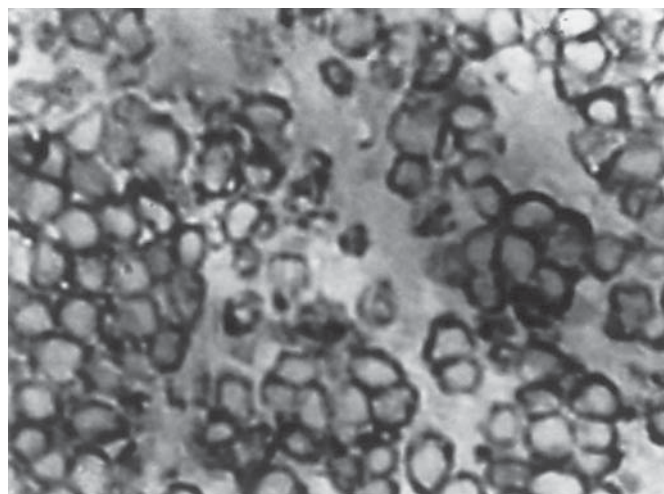


Fig. 7. Photomicrograph of immunostained slide (neuron-specific enolase) showing perinuclear cytoplasmic positivity of the tumor cells. Magnification $\times 200$.

Table 2. Histopathology and IHC characteristics of PNET

Cases	Cell morphology	Architecture	IHC
1	small round cells with scanty cytoplasm	sheets of cells	synaptophysin positive
2	small round cells with scanty cytoplasm (fig. 6)	sheets and nests with fibrovascular septa	focally positive for synaptophysin and neuron-specific enolase (fig. 7)
3	small round cells with scanty cytoplasm	sheets and nests with fibrovascular septa	positive for NS filaments and MIC-2 antibodies; LCA, EMA and vimentin negative

NS = Neurospecific enolase; MIC-2 = antigen identified by monoclonal antibodies 12E7, F21 and Om13; LCA = leukocyte common antigen; EMA = epithelial membrane antigen.

short history has been characteristic of PSPNET and is in accordance with the other reported cases. At no stage of the illness did the patients show any evidence of cranial lesion. This is important since most cases of PNET involving the spinal cord are 'drop' metastases from primary intracranial tumors. It has been postulated that the primary intracranial lesion may be small and clinically silent, with symptoms referable only to the metastatic deposits of the spine. One case of intramedullary drop metastases with no leptomeningeal involvement has been described. All our patients underwent cranial imaging postoperatively with no evidence of any pathology.

There are no specific features of these tumors on MRI. In case 1, the lesion was intramedullary and heterogeneously enhancing on contrast and appeared to have

pushed the cord eccentrically to the left. A preoperative diagnosis of ependymoma was made.

In case 2, imaging gave a picture akin to a neurofibroma since it had intra- and extradural involvement. Case 3 was truly a diagnostic dilemma. The cord was diffusely enlarged with some patchy contrast enhancement except at the D₅ level which had intense enhancement. This picture may resemble holocord astrocytoma to some extent. Holocord hemangioblastoma differed from it in many ways. There was no cyst, and multiple flow voids were seen. A spinal angiogram did not reveal any increased vascularity of the enhancing portion. A review of the literature showed no specific characteristics described for PSPNET. MRI findings are not specific and can mimic other spinal lesions. But this holocord involvement with multiple flow voids has not been described earlier in

the literature. Only 4 cases have been extradural and the rest were intradural. The commonest location is the cauda equina region. This might be due to the fact that the cauda equina forms part of the peripheral nervous system, where the axons have become dependent on Schwann cells for the maintenance of their myelin sheaths.

These cases are diagnosed on histopathology and IHC. IHC was done in all 3 cases to confirm the diagnosis (table 2). Though near total decompression forms the primary mode of treatment, results are poor. Radiotherapy and chemotherapy have been used. In view of the limited cases, the optimal management has not been defined yet. We offered craniospinal radiation in our cases as it is used in cases of posterior fossa medulloblastomas. The cranial radiation was carried out as PNET tumors are known for their widespread dissemination through the CSF [24]. Since we had witnessed supratentorial dissemination in

operated and irradiated cases of posterior fossa medulloblastomas, we irradiated the cranium also. The doses of radiation were calculated according to the weight and age of each case. No extra (booster) doses were given to the involved segment. The chemotherapy used by us was the Packer regimen. It consisted of vincristine weekly during radiotherapy and then vincristine, cisplatin and CCNU for 8 cycles [25]. In view of the propensity for metastasis beyond the craniospinal axis, the initial workup should screen the chest and abdomen. Bone marrow aspiration and cytology to look for dissemination is also advised. In view of the poor results with conventional modalities, novel approaches like adoptive immunotherapy are necessary. Peripheral blood stem cell transfusion is suggested during periods of remission [26]. An improvement of the treatment outcome can only be achieved by intensification through a multidisciplinary approach.

References

- Hart MN, Earle KM: Primitive neuroectodermal tumours of the brain in children. *Cancer* 1973;32:890–897.
- Rubenstein LJ: Embryonal tumours; in Kleihues P, Cavaneer WK (eds): *Tumors of the Nervous System*. Lyon, IARC Press, 2000, pp 123–144.
- Smith DR, Hardman JM, Earle KM: Metastasizing neuroectodermal tumors of the central nervous system. *J Neurosurg* 1969;31:50–58.
- Kosnik EJ, Boesel CP, Bay J, Sayers MP: Primitive neuroectodermal tumors of the central nervous system in children. *J Neurosurg* 1978;48:741–746.
- Kepes JJ, Belton K, Roessmann U, Ketcherside WJ: Primitive neuroectodermal tumors of the cauda equina in adults with no detectable primary intracranial neoplasm – three case studies. *Clin Neuropathol* 1985;4:1–11.
- Liu HM, Yang WC, Garcia RL, Noh JM, Malhotra V, Leeds NE: Intraspinal primitive neuroectodermal tumor arising from the sacral spinal nerve root. *J Comput Tomogr* 1987;11:350–354.
- Sevick RJ, Johns RD, Curry BJ: Primary spinal primitive neuroectodermal tumor with extraneural metastases. *AJNR Am J Neuroradiol* 1987;8:1151–1152.
- Jackse H, Wockel W, Wernest N: Primary spinal medulloblastoma. *Neurosurg Rev* 1988;11:259–265.
- Freyer DR, Hutchinson RJ, McKeever PE: Primary primitive neuroectodermal tumor of the spinal cord associated with neural tube defect. *Pediatr Neurosci* 1989;15:181–187.
- Ogasawara H, Kiya K, Kurisu K, Muttaqin Z, Uozumi T, Sugiyama K, Kawamoto Y, Iida K: Intracranial metastasis from a spinal cord primitive neuroectodermal tumor: case report. *Surg Neurol* 1992;37:307–312.
- McDermott VG, el-Jabbour JN, Sellar RJ, Bell J: Primitive neuroectodermal tumour of the cauda equina. *Neuroradiology* 1994;36:228–230.
- Kwon OK, Wang KC, Kim CJ, Kim IO, Chi JG, Cho BK: Primary intramedullary spinal cord primitive neuroectodermal tumor with intracranial seeding in an infant. *Childs Nerv Syst* 1996;12:633–636.
- Deme S, Ang LC, Skaf G, Rowed DW: Primary intramedullary primitive neuroectodermal tumor of the spinal cord: case report and review of the literature. *Neurosurgery* 1997;41:1417–1420.
- Koot RW, Henneveld HT, Albrecht KW: Two children with unusual causes of torticollis: primitive neuroectodermal tumor and Grisel's syndrome. *Ned Tijdschr Geneesk* 1998;142:1030–1033.
- Rodriguez M, Dinapoli RP: Spinal cord compression: with special reference to metastatic epidural tumors. *Mayo Clin Proc* 1980;55:442–448.
- Virani MJ, Jain S: Primary intraspinal primitive neuroectodermal tumor (PNET): a rare occurrence. *Neurol India* 2002;50:75–80.
- Marwin C, Synowitz HJ, Kirches E, Kutz E, Dietzmann K, Weis S: Primary primitive neuroectodermal tumor of the spinal cord: case report and review of the literature. *Clin Neurol Neurosurg* 2002;104:36–40.
- Albrecht CF, Weiss E, Schulz-Schaeffer WJ, Albrecht T, Fauser S, Wickboldt J, Hess CF: Primary intraspinal primitive neuroectodermal tumor: report of two cases and review of the literature. *J Neurooncol* 2003;61:113–120.
- Yavuz AA, Yaris N, Yavuz MN, Sari A, Reis AK, Aydin F: Primary intraspinal primitive neuroectodermal tumor: case report of a tumor arising from the sacral spinal nerve root and review of the literature. *Am J Clin Oncol* 2002;25:135–139.
- Aydin MV, Sen O, Ozel S, Kayaselcuk F, Caner H, Altinors N: Primary primitive neuroectodermal tumor within the spinal epidural space: report of a case and review of the literature. *Neurol Res* 2004;26:774–777.
- Kim YW, Jin BH, Kim TS, Cho YE: Primary intraspinal primitive neuroectodermal tumor at conus medullaris. *Yonsei Med J* 2004;45:533–538.
- Rorke LB: The cerebellar medulloblastoma and its relationship to primitive neuroectodermal tumours. *J Neuropathol Exp Neurol* 1983;42:1–15.
- Burnett ME, White EC, Sih S, von Haken MS, Cogen PH: Chromosome arm 17p deletion analysis reveals molecular genetic heterogeneity in supratentorial and infratentorial primitive neuroectodermal tumors of the central nervous system. *Cancer Genet Cytogenet* 1997;97:25–31.
- Kumar R: Outcome of medulloblastoma with neuraxial dissemination: an analysis of nine cases. *J Pediatr Neurol*, in press.
- Packer RJ, Sutton LN, Goldwein JW: Improved survival with the use of adjuvant chemotherapy in the treatment of medulloblastoma. *J Neurosurg* 1991;74:433–440.
- Soumya V: Hinduja successfully performs its first PBST. *Express Healthcare Manag* 2000;1:3.

Copyright: S. Karger AG, Basel 2007. Reproduced with the permission of S. Karger AG, Basel.
Further reproduction or distribution (electronic or otherwise) is prohibited without permission
from the copyright holder.