

NOTE

CROSSED ANOMIC APHASIA: MILD NAMING DEFICITS FOLLOWING RIGHT BRAIN DAMAGE IN A DEXTRAL PATIENT

Uri Hadar¹, Stephanie Ticehurst² and John P. Wade³

(¹Psychology Department, Tel Aviv University, Ramat Aviv; ²Speech Therapy Department, Charing Cross Hospital, London; ³Regional Neurosciences Centre, Charing Cross Hospital, London)

INTRODUCTION

The occurrence of language problems following right hemisphere brain damage in dextrals, known as 'crossed aphasia' (CA), offers a unique opportunity to investigate interesting issues in the relationship between brain organisation and cognitive processes. The crucial issue in this respect is whether or not the brain is capable of complete reversal of the normal pattern of cerebral organisation in dextrals, whereby the left hemisphere is dominant for language, whilst the right is dominant for visuo-spatial and auditory-nonverbal processing (Bradshaw and Nettleton, 1983). This represents two relatively autonomous questions, that is, whether in dextrals language may completely crossover to the right hemisphere, and whether such cases also show the crossover of visuo-spatial and auditory-nonverbal processing to the left cerebral hemisphere.

On one account, CA occurs in patients with diffuse cerebral localisation of language, representing a cerebral organisation that is essentially different from, rather than the reversal of, the usual left-hemisphere specialisation for language. This could originate in an early childhood brain damage preventing the complete lateralisation of brain function (Brown, 1976; Brown and Hécaen, 1976). Evidence to support this thesis comes from two aspects of the aphasic syndrome in CA, that is, (a) the uniform pattern of deficit and recovery, and its indifference to intra-hemispheric localisation, and (b) the apparent involvement of diverse components of language processing (syntactic, morphological and phonological). Thus, it is claimed, true CA patients are mute immediately after the onset of language problems, but then recover rapidly, giving a picture of non-fluent aphasia with agrammatism and phonemic paraphasia, followed by further recovery which tends to leave them with little or no chronic deficit (Brown and Hécaen, 1976). However, a number of CA cases with *fluent* aphasia have recently been reported (Carr, Jacobson and Boller, 1981; Henderson, 1983; Basso et al., 1985), suggesting that the pattern of deficit is not so uniform and that CA can produce diverse language disorders, both fluent and non fluent. This does not amount to a total refutation of the thesis of diffuse cerebral organisation, because most of the fluent CA patients display wide ranging deficits, rather than impairment of a specific language module such as lexical or sublexical semantic or phonological deficits (see Coltheart, 1987, for an account of the variety of modules involved in language processing). Therefore, a weak version of the thesis of diffuse localisation can be developed (Brown and Chobor, 1987), whereby the pattern of deficit in CA may not be uniform, but always implicate diverse processing modules. This should manifest in a non-specific (rather than uniform) pattern of language deficit, with both lexical and sublexical, syntactic and phonological impairments. Unfortunately, even this narrower claim is disputed by cases of CA with a fairly specific deficit such as transcortical sensory aphasia and conduction aphasia (Carr et al., 1981; Henderson, 1983; Reinvang, 1987; Perani et al., 1988).

As for nonverbal functions, it is known that the right hemisphere generally, and its temporo-parietal regions particularly, is specialised for visuo-spatial processes such as visual recognition, the construction of geometrical designs, memory for the localisation and orientation of objects and forms in space, etc. (Milner, 1969). Consequently, a right hemisphere

brain damage, especially when implicating temporo-parietal regions, tends to produce related deficits such as constructional apraxia, impaired visuo-spatial memory, visual neglect, impaired recognition of faces and objects, etc. (Kimura, 1963; Yin, 1970; Bradshaw and Nettleton, 1983). The question arises as to whether in CA these functions cross over to the left cerebral hemisphere, mirroring the 'normal' pattern and inter-hemispheric specialisation. Some CA patients display, in addition to language problems, many of the usual deficits following right-hemisphere brain damage (Basso et al., 1985; Castro-Caldas, Confraria and Poppe, 1987), whereas others show no deficit of visuo-spatial or visuo-constructional function (Larrabee, Kane and Rodgers, 1982; Kapur and Dunkley, 1984). Whilst no cross-over of nonverbal right hemisphere function is indicated in the former patients, the latter suggest the complete reversal of the normal pattern of specialisation. The question arises as to whether or not the specificity of language dysfunction in CA patients is related to the reversal of nonverbal function, that is, whether patients with specific, isolated language deficits are also those who show the reversal of nonverbal functions. Such patients would represent the mirror image of normal hemispheric specialisation, provided the intra-hemispheric localisation of their damage is analogous to that seen in similar deficits following left hemisphere damage.

An inherent methodological problem with the study of CA is its rareness, occurring in under 2% of the aphasic population (Lecours et al., 1983). As a result, the study of CA has so far been based upon detailed single case studies which appear particularly relevant to the disputed issues. We present a dextral CA patient whose pattern of deficit reflects upon the above issues. Following a right superior temporal brain damage, he has developed a mild naming problem which is similar to that of previously reported cases of 'disconnection' or 'blockage' of an intact phonological lexicon following left hemisphere brain damage (Hadar, Jones and Mate-Kole, 1987; Kay and Ellis, 1987). His deficit is module specific and the cerebral location of his damage is similar to that of patients with anomic aphasia following left hemisphere damage (Benson, 1979). His visuo-spatial and auditory-nonverbal function appears intact.

CASE REPORT

DA, a 37 year old man with technical college education (electrical engineering) was admitted to Charing Cross Hospital on 27th July 1987, being restless and mute. Twelve hours earlier a pulsating headache had started and intensified over a period of 10 minutes. He then vomited, became disoriented, and developed dysphasia and transient amnesia. On admission, he had no neck stiffness or hemiplegia and responded to pain with localising movements; the plantar responses were upgoing. He improved for 12 hours following admission, but then deteriorated and developed a left hemiplegia. A CT brain scan (Figure 1) showed a large right temporal lobe haematoma, with mass effect and compression of the right lateral and 3rd ventricles, as well as a midline shift. A right carotid and vertebral angiogram showed a large anterior temporal arterial malformation, predominantly supplied by the right middle cerebral artery. His haematoma was surgically drained and the malformation was removed.

DA made a good and rapid post-operative recovery and was discharged a week later fully mobile and self-caring. He continued to improve and six months later, when assessed in our laboratory, had recovered all functions except for a mild stutter and mild anomic aphasia (see below).

A follow-up CT scan was unhelpful because of the artefact due to surgically placed clips on the right middle cerebral artery. Therefore, a single photon emission tomography (SPET) brain scan was performed using Tc 99m-HMPAO and the NOVO 810 tomographic brain scanner. This revealed a perfusion deficit in the right anterior temporal lobe, extending posteriorly as well as into higher parietal areas (Figure 2). The hypoperfusion seen in the SPET image exceeds the extent of the structural damage.

When assessed in our laboratory, DA also reported a number of epileptic seizures, which had started 15 years earlier and had never been recognised as ictal. Attacks occurred about once monthly, heralded by nausea and tingling around the abdomen area and followed by muteness and loss of concentration for about 3 minutes. He was not amnesic for the attacks

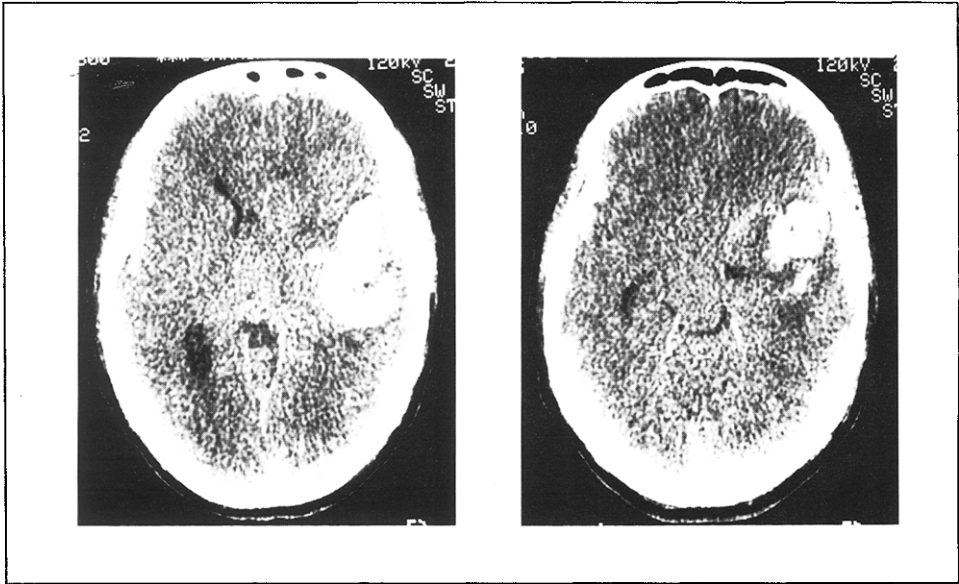
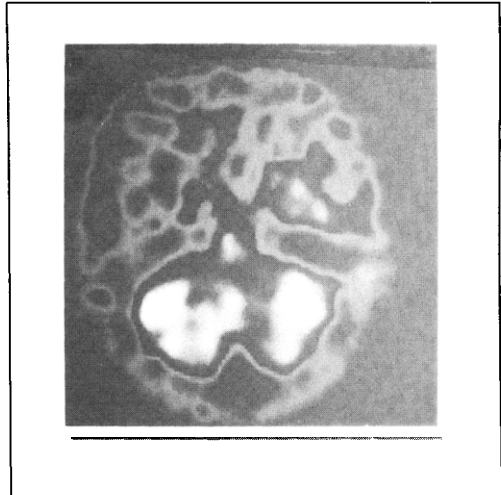


Fig. 1 - A CT brain scan performed one day following admission, showing an haematoma in the right anterior temporal lobe.

Fig. 2 - A SPET brain scan performed 6 months post operation, showing hypoperfusion confined to the right hemisphere.



and they never progressed to a grand mal convulsion.

DA, an only child, was strongly right handed, scoring 10/10 on the Edinburg Inventory (Olfield, 1971). Both his parents were right handed. The assessment we report here was carried out at the hospital, starting about six months post onset and continuing over a period of about one month; it was administered by a single member of our team (ST).

Nonverbal Performance

In a follow-up neurological examination DA showed no visual field loss, neglect or inattention, and performed normally the line bisection task (Werth and Poppel, 1988). He reported no recognition problems for either objects or faces. On the unusual/usual views test, which requires the recognition of objects photographed from unusual as well as usual angles (Warrington and Taylor, 1973) he scored 40/40. DA scored 10/10 on a face recognition/memory test, where he was shown 10 photographs of unfamiliar faces and then asked to select them out of a set of 20 photographs of unfamiliar faces. He scored 5/5 on a spatial memory test where 5 objects, placed in different locations in the examination room, were pointed out for him and, after being rotated in his chair a few times, DA had to point again in their direction with his eyes closed. He scored 13/14 (average being 11) on immediate reproduction of designs from the Wechsler Memory Scale, and showed no signs of reduction or motor neglect in drawing a clock and a house (Figure 3). He had a scaled score of 9 on the object assembly test of the Wechsler Adult Intelligence Scale (WAIS). On the block design test of

TABLE I
Summary of DA's Performance on Tests of Nonverbal Function

Test	Score
Unusual/usual views	40/40
Face recognition	10/10
Spatial orientation	5/5
Reproduction of designs	13/14
Object assembly (WAIS scaled score)	9
Block design (WAIS scaled score)	11
Ideomotor apraxia	10/10
Recognition of nonverbal sounds	10/10
Rhythm repetition (tapping)	5/5

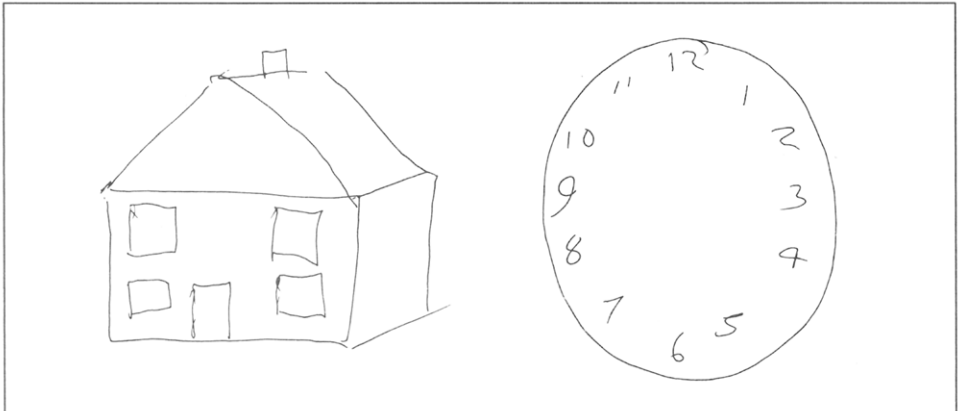


Fig. 3 - DA's drawing performance illustrating the absence of unilateral neglect.

the WAIS he scored 23 (scaled score 11), which is upper average. DA was given 10 of the limb tasks of the ideomotor apraxia battery of Poeck (1986) and he performed them all without difficulty.

DA was also given a recognition task for nonverbal sounds. Sitting with his back to the examiner, he was asked to repeat such sounds as hands clapping, tongue clicking, hissing,

cloths rubbing, etc., where he scored 10/10. Finally, he scored 5/5 on a tapping repetition task composed of 4-8 beats (one of each).

To sum up, DA showed no visual field deficits or recognition problems. His visuo-spatial orientation was normal and visuo-constructional ability very good. His representation and reproduction of designs was intact, and so was his symbolic and representational gesture. He had no problems with auditory recognition of nonverbal sounds and performed very well the audio-motor task of rhythm repetition.

Language Performance

Phonological, Lexical and Sentence Processing

Table II summarises DA's performance on a number of language processing tests. Two rhyming tests were given to assess DA's phonological processing. In the first he was shown 3 written words (eg, 'mail', 'sale', 'soul') and was asked to determine without reading aloud which two rhymed, where he scored 30/30. In the second, a similar task was repeated, but the target words were presented as pictures rather than in a written form. Here DA scored 17/20. Next DA was given the auditory part of a lexical decision test, requiring the determination of whether or not a spoken string of English phonemes forms a word in English.

TABLE II

Summary of DA's Performance on Tests of Phonological, Lexical and Sentence Processing (Mode of Presentation Appears in brackets)

Test	Score
Rhyme judgment (written)	30/30
Rhyme judgment (pictorial)	17/20
Lexical decision (auditory)	49/50
Word-picture matching (auditory)	40/40
Repetition of words (auditory)	20/20
Repetition of non-words (auditory)	20/20
Modified Token Test (auditory)	40/40
TROG (auditory and written)	80/80

He scored 49/50 on this test. He was also given the auditory part of Janis Kay's lexical comprehension test, requiring the matching of a picture to a spoken word. The target picture (eg, a cobweb) was presented together with 5 other pictures such as a semantic distractor (eg, a spider), a visual distractor (eg, a wheel), etc. DA scored 40/40 on this test. On a word repetition task DA scored 20/20, and so he did with non-word repetition. Next, a revision of the Token Test (De Renzi and Vignolo, 1962) was prepared, where the original colours and forms were substituted for others with lower frequency names (red, blue, green and yellow were respectively substituted for scarlet, turquoise, purple and grey; triangle and circle were substituted for hexagon and oval respectively). DA scored 40/40 on auditory presentation of this modified version. Another test of sentence processing was given, the TROG, where DA was required to match a picture to propositional phrases of various constructions. The test varies systematically the grammatical construction of the phrases, eg, passive versus active, embedded versus conjunctive clauses, etc. The distractor pictures depict reversed roles and actions between similar agents. DA scored 80/80 on this test.

Fluency and Discourse Level Language Performance

Analysis of DA's narration of the Cinderella story revealed a mild stutter comparable to that reported by Rosenbek et al. (1978): he repeated 2-3 times the initial sounds of words without compromising their phonetic integrity. When relaxed and concentrated, DA could speak fluently for a long time (up to 147 words in our sample), but emotional stress and loss

of concentration resulted in recurrence of stutter every 3-5 words, equally implicating consonants and whole syllables. Apart from this, his speech was fluent, producing in average 111.4 words per minute and having an average phrase length of 17.4 words. Compared with a control subject matched for sex, age and education, DA showed no abnormal level of circumlocution or word finding difficulties, having a relatively high share of open class words (49.9% of the total, compared with the control's 42.9%) and a low share of pronouns (11.2% of the total, compared with the control's 16.0%). Other aspects of the lexical analysis of his narrative were comparable, indeed, nearly identical to that of the control subject (Table III). His good production of language on discourse level was matched by DA's memory for verbal prose. Asked to repeat after the examiner a passage of simple prose selected from the Wechsler Memory Scale he scored 12/23 (the average being 10).

TABLE III

Lexical Analysis of DA's Cinderella Story, Compared to a Matched Control ('Total' represents actual word count. Other values represent the percentage of a particular category in the respective total of 'words' or 'vocabulary')

Category	DA	Control
Total		
Words	321	799
Vocabulary	139	198
Open Class Items		
Nouns		
Words	16.2	11.5
Vocabulary	19.4	14.7
Verbs		
Words	17.5	18.6
Vocabulary	20.1	24.2
Adverbs and Adjectives		
Words	16.2	12.8
Vocabulary	25.2	26.8
Total of open class items		
Words	49.9	42.9
Vocabulary	64.7	65.7
Closed Class Items		
Prepositions		
Words	12.1	13.1
Vocabulary	10.8	10.1
Pronouns		
Words	11.2	16.0
Vocabulary	7.2	10.6
Others		
Words	26.8	28.0
Vocabulary	17.3	13.6
Total of closed class items		
Words	50.1	57.1
Vocabulary	35.3	34.3

Naming and Word Retrieval

DA was given 3 different naming tests and showed clear impairments on all of them. On a well known test of picture naming of both high and low frequency objects, the Boston Naming Test, he scored 50/60, whilst 10 controls matched for educational background scored a mean of 57.4/60 (SD = 0.96; range 56-59/60). On a set of pictures of low frequency objects, compiled by Warrington and McKenna, DA scored 19/30, whilst the group of 10 controls scored a mean of 23.9/30 (SD = 1.29; range 22-26/30). In 8 of his 11 failures DA managed to retrieve the target word with the help of a phonemic cue, suggesting that DA's

premorbid vocabulary matched that of the best of our normal controls. Finally, a test was devised by our team as a high level responsive naming test, where naming was in response to a dictionary style, oral definition of the target words, which included items such as 'wisdom', 'liberty', 'amnesia', etc. Forty items were originally prepared and then tested with 5 control subjects. Six items with which one or more of the controls showed difficulty were rejected. DA scored on this test 22/34.

The remarkable point about DA's naming performance lay not only in his rate of failure, but also in the fact that in almost 90% of failures (29/33) he successfully retrieved the word when given an additional cue. Cues were usually phonemic (22/29), comprising the first phoneme of the target word. The semantic cues drew DA's attention to inaccuracies in his response, for example, DA produced the word 'circle' to the target 'radius', wherein the examiner said 'but circle is the whole thing and I want the name of this bisecting line'.

Table IV lists DA's failures on all 3 naming tests. A high proportion of these (15/33) involved a failure to offer either the target or a substitute name, where DA usually (in 8 of 12 relevant cases) offered an adequate functional description. Fourteen of a total of 18 naming errors were semantic coordinates, 2 were associates and 2 superordinates.

DA's naming difficulties were reflected in a verbal fluency test, requiring the production of as many words of a specified class as possible within a period of 1 minute. His production

TABLE IV
A List of DA's Naming Failures on 3 Naming Tests

Target	Response	Error type
From the Boston Naming Test		
Broom	Sweeping brush	coordinate
Wreath	no response	---
Beaver	Bear	coordinate
Domino	description of game	---
Accordion	Concertina	coordinate
Asparagus	no response	---
Yoke	Stirrups	coordinate
Palatte	Easle	coordinate
Protractor	functional description	---
Abacus	functional description	---
From Warrington and McKenna		
Tassle	deictic gesture	---
Blinkers	Bridle	superordinate
Anteater	Wild boar	coordinate
Radius	Circle	superordinate
Mitre	description of use	---
Yashmak	functional description	---
Sextant	functional description	---
Centaur	no response	---
Tutu	no response	---
Cowl	Habit	coordinate
Retort	functional description	---
From the Charing Cross Responsive Naming Test		
Conformist	no response	---
Anthropologist	Historian	coordinate
Pioneer	Founder	coordinate
Amnesia	Insomnia	coordinate
Entrepreneur	Philantropist	coordinate
Hexagon	Cube	coordinate
Liberty	no reponse	---
Republic	Democracy	coordinate
Wisdom	no response	---
Native	Resident	coordinate
Threat	Sentence	associate
Share	Position	associate

was generally low relative to DA's level of education, but this was more marked for classes specified by initial phoneme than for classes specified by semantic category. Thus, DA produced 10 words starting with /s/, 11 with /l/ and 12 with /r/, whilst producing 15 animal names, 17 food names and 18 town names. For comparison, our matched control produced 18 words starting with /s/, 14 with /l/ and 13 with /r/, as well as 20 animal names, 20 food names and 18 town names.

DISCUSSION

DA is a strongly right-handed CA patient whose neurological loss is probably limited to the right cerebral hemisphere, both structurally and functionally (Figures 1 and 2). The intra-hemispheric location of his damage in temporo-parietal regions is analogous to that of most anomic aphasics (Benson, 1979). DA's performance on all nonverbal tasks appears intact, suggesting that his visuo-constructional, auditory-nonverbal and spatial functions are localised in the left hemisphere. Stutter similar to that of DA has been reported in patients with left hemisphere brain damage (Rosenbek et al., 1978).

The most salient feature of DA's language performance is a mild naming deficit that has persisted for a fairly long time post onset, indicating the disturbance of a specific component of language processing. Only one other case of crossed anomic aphasia has been reported so far (Castro-Caldas et al., 1987), but no processing account for this case is available because of the absence of a detailed language assessment. DA's anomia is similar to that of a previously reported case of 'anomic disconnection' (Hadar et al., 1987), characterised by a high proportion of non response in naming failures (when neither the target nor a substitute item are produced), a good functional definition of the failed items, an exceptionally high rate of benefits from phonemic cues and absence of anomic symptoms in continuous speech. This, together with the fact that DA performed the verbal fluency tasks better to semantic than to phonemic specification, suggests that his naming deficits originate in the 'blocking' of, or increased activation levels required for, retrieval from an *intact* phonological lexicon (see Kay and Ellis, 1987).

The above features group DA together with other recently reported cases (Carr et al., 1981; Henderson, 1983; Basso et al., 1985; Reinvang, 1987) that contradict the thesis of incomplete hemispheric specialisation, both in its strong claim for a uniform pattern of deficit (Brown and Hécaen, 1976), and in its weak version of non-specific deficits (Brown and Chobor, 1987). Instead, support is given to the distinction made by Kapur and Dunkley (1984) between two groups of CA patients, one with specific and one with non-specific language deficits. The former group is difficult to define because most past reports lack a detailed processing account, but good candidates are suggested in some cases classed as transcortical sensory aphasia (Carr et al., 1981; Larrabee et al., 1982; Roeltgen and Heilman, 1983; Reinvang, 1987) or anomic aphasia (Castro-Caldas et al., 1987) and the present case. The emerging picture is that patients with specific language deficits also tend to show the preservation of visuo-constructional and spatial abilities¹, suggesting the reversal of right-hemisphere function of the left hemisphere, with intra-hemispheric localisation analogous to that of the more common pattern of specialisation of hemispheric function. This represents a complete reversal of the normal pattern of hemispheric specialisation (Reinvang, 1987). Conversely, CA patients with a range of non-specific language dysfunctions also tend to show an impairment of visuo-constructional or spatial function, as well as variable intra-hemispheric localisation, usually involving deep structures (Habib et al., 1983). This probably represents diffuse nervous organisation (Brown and Chobor, 1987).

Two other factors are often cited as characteristic of CA, the rate of recovery and age of onset of language dysfunction which, unlike organisational and functional patterns, do not seem to distinguish between the above groups. Previous studies have suggested that recovery

¹ Some nonverbal dysfunctions, notably ideomotor and ideational apraxia, also occur after left hemisphere damage and are usually associated with aphasia (Poeck, 1986). These have been observed in CA patients as well, but, interestingly enough, primarily in patients who also show evidence of a specific language dysfunction (Castro-Caldas et al., 1987).

of CA patients is faster and more complete than in the aphasic population generally (see Castro-Caldas and Confraria, 1984). This alone does not necessarily reflect an underlying homogeneity, because it may originate from different mechanisms. Patients with non-specific deficits could recover because their cerebral organisation is relatively amenable to compensatory transfer of function, as suggested by Brown and Hécaen (1976). By distinction, those with specific deficits could recover well because the related lesion (and brain dysfunction) tends to be limited (Kertesz, 1984). The age of onset does not appear to differentiate between CA subgroups and is generally lower in CA than in left hemisphere stroke patients (Castro-Caldas and Confraria, 1984). This, it has been suggested, may represent an inherent structural weakness connected with the early pathological processes that forced the crossed or diffuse nervous organisation (Brown and Hécaen, 1976). Reversed language specialisation often follows an early left hemisphere dysfunction and represents functional compensation (Rasmussen and Milner, 1977). DA, like other relatively young CVA patients, demonstrates an early, probably congenital, brain damage, seen in both epileptic episodes and arterial malformation but, paradoxically, this is located in the *right* hemisphere. Here, apparently, the reversal of hemispheric specialisation was independent of, and persisted despite, DA's right-hemisphere lesion, suggesting a strong genetic bias, but it would be premature to speculate about this in the absence of more direct evidence.

ABSTRACT

A detailed case study is reported of crossed aphasia (CA) in a dextral patient, bearing upon such controversial issues as intrahemispheric localisation of language function and hemispheric reversal of nonverbal function. DA, a man aged 37, developed a mild naming problem due to right temporal lobe haematoma. Apart from a mild acquired stutter, his continuous speech was fluent and had a normal proportion of open to closed class lexical items. His naming deficit appears to originate in the 'blocking' or 'disconnection' of the phonological lexicon: he could usually give a functional definition of un-named items and retrieve them with the help of a phonemic cue. Lexical retrieval appears his only language deficit, as he had no comprehension or phonological discrimination deficits. DA showed no visuo-spatial or auditory-nonverbal deficits, suggesting the complete reversal of hemispheric specialisation.

Acknowledgements. We thank Mr Peter Richards, Consultant neurosurgeon at the Charing Cross Hospital, for allowing us to investigate his patient. Thanks also go to the SPET team in the Nuclear Medicine Department, Charing Cross Hospital, for performing the SPET scan, and to two anonymous reviewers. Dr Hadar was supported by the Leverhulme Trust.

REFERENCES

- BASSO, A., CAPITANI, E., LAIACONA, M., and ZANOBI, M.E. Crossed aphasia: one or more syndromes? *Cortex*, 21: 25-45, 1985.
- BENSON, F.D. Neurological correlates of anomia. In A.B. Baker and L.H. Baker (Eds.), *Clinical Neurology*, Vol. 1. New York: Academic Press, 1979, pp. 293-328.
- BRADSHAW, J.L., and NETTLETON, N.C. *Human Cerebral Asymmetry*. New York: Academic Press, 1983.
- BROWN, J.W. The neural organisation of language: aphasia and lateralisation. *Brain and Language*, 3: 482-494, 1976.
- BROWN, J.W., and HÉCAEN, H. Lateralisation and language representation. *Neurology*, 26: 183-189, 1976.
- BROWN, J.W., and CHOBOR, K. Absence of aphasia in a dextral with a left hemisphere lesion: a case report. *Aphasiology*, 1: 435-441, 1987.
- CARR, M.S., JACOBSON, T., and BOLLER, F. Crossed aphasia: analysis of four cases. *Brain and Language*, 14: 190-202, 1981.
- CASTRO-CALDAS, A., and CONFRARIA, A. Age and type of crossed aphasia in dextrals due to stroke. *Brain and Language*, 23: 126-133, 1984.

- CASTRO-CALDAS, A., CONFRARIA, A., and POPPE, P. Nonverbal disturbances in crossed aphasia. *Aphasiology*, 1: 403-413, 1987.
- COLTHEART, M. Functional architecture of the language processing system. In M. Coltheart, R. Job and G. Sartori (Eds.), *The Cognitive Neuropsychology of Language*. Hillsdale (NJ): Lawrence Erlbaum, 1987.
- DE RENZI, E., and VIGNOLO, L.A. The token test: a sensitive test to detect receptive disturbances in aphasics. *Brain*, 85: 665-678, 1962.
- HABIB, M., JOANNETTE, Y., ALI-CHERIF, A., and PONCET, M. Crossed aphasia in dextrals: a case report with special references to site of lesion. *Neuropsychologia*, 21: 413-418, 1983.
- HADAR, U., JONES, C., and MATE-KOLE, C. The disconnection in anomic aphasia between semantic and phonological lexicons. *Cortex*, 23: 505-517, 1987.
- HENDERSON, V.W. Speech fluency in crossed aphasia. *Brain*, 106: 837-857, 1983.
- KAPUR, N., and DUNKLEY, B. Neuropsychological analysis of a case of crossed dysphasia verified at post-mortem. *Brain and Language*, 23: 134-147, 1984.
- KAY, J., and ELLIS, A. A cognitive neuropsychological case study of anomia. *Brain*, 110: 613-629, 1987.
- KERTESZ, A. Recovery from aphasia. In F.C. Rose (Ed.), *Progress in Aphasiology*. New York: Raven Press, 1984.
- KIMURA, D. Some effects of temporal lobe damage on auditory perception. *Canadian Journal of Psychology*, 15: 156-165, 1961.
- KIMURA, D. Right temporal lobe damage. *Archives of Neurology*, 8: 264-271, 1963.
- LARRABEE, G.J., KANE, R.L., and RODGERS, J.A. Neuropsychological analysis of a case of crossed aphasia. Implications for reversed laterality. *Journal of Clinical Neuropsychology*, 4: 131-142, 1982.
- LECOURS, A.R., BASSO, A., MORASCHINI, S., and NESPOULOUS, J-L. Where is the speech area and who has seen it. In D. Caplan, A.R. Lecours and A. Smith (Eds.), *Biological Perspectives on Language*. Cambridge (Mass): MIT Press, 1984, pp. 221-246.
- MILNER, B. Brain mechanisms suggested by studies of the temporal lobes. In F.L. Darley (Ed.), *Brain Mechanisms Underlying Speech and Language*. New York: Grune and Stratton, 1969, pp. 122-131.
- OLDFIELD, R.C. The assessment and analysis of handedness: the Edinburgh Inventory. *Neuropsychologia*, 9: 97-113, 1971.
- PERANI, D., PAPAGNO, C., CAPPÀ, S., GERUNDINI, P., and FAZIO, F. Crossed aphasia: functional studies with single photon emission computerised tomography. *Cortex*, 24: 171-178, 1988.
- POECK, K. The clinical examination for motor apraxia. *Neuropsychologia*, 24: 129-134, 1986.
- RASMUSSEN, T., and MILNER, B. The role of early left brain injury in determining the lateralization of cerebral speech functions. *Annals of the New York Academy of Science*, 29: 355-369, 1977.
- REINVANG, I. Crossed aphasia and apraxia in an artist. *Aphasiology*, 1: 423-434, 1987.
- ROELTGEN, D.P., and HEILMAN, M. Apractic agraphia in a patient with normal praxis. *Brain and Language*, 18: 35-46, 1983.
- ROSENBEK, J.C., MESSERT, B., COLLINS, M., and WERTZ, R.T. Stuttering following brain damage. *Brain and Language*, 6: 82-96, 1978.
- WARRINGTON, E., and TAYLOR, A. The contribution of the right parietal lobe to object recognition. *Cortex*, 9: 159-164, 1973.
- WECHSLER, A.F. Crossed aphasia in an illiterate dextral. *Brain and Language*, 3: 164-172, 1976.
- WERTH, R., and POPPEL, E. Compression and lateral shift of mental coordinate systems in a line bisection task. *Neuropsychologia*, 26: 741-745, 1988.
- YIN, R.K. Face recognition by brain injured patients: a dissociable ability. *Neuropsychologia*, 8: 395-402, 1970.