

LETTER TO THE EDITOR

Pure apraxic agraphia: a disconnection syndrome after left subcortical stroke

A. Assmus^{a,c}, A. Buss^a, E. L. Milkereit^a,
J. Meyer^b and G. R. Fink^{a,c}

^aDepartment of Neurology, University Hospital RWTH Aachen, Aachen, Germany; ^bDepartment of Neuroradiology, University Hospital RWTH Aachen, Aachen, Germany; ^cInstitute of Medicine, Research Centre Juelich, Juelich, Germany

OnlineOnly: This article is available online only at www.blackwell-synergy.com

Correspondence: Ann Assmus, Department of Neurology, University Hospital RWTH Aachen, Pauwelsstr. 30, 52074 Aachen, Germany (tel.: +49 241 8089796; fax: +49 241 8082444; e-mail: aassmus@ukaachen.de).

Keywords: disconnection syndrome, agraphia, subcortical infarction, handwriting

Received 25 November 2005

Accepted 27 February 2006

Sir,

A 72-year-old right-handed female patient presented with difficulty of speaking and writing which had developed acutely 3 days prior to admission. She used to have fast fluent handwriting, but now complained about having problems to initiate the correct writing movements. She was used to write long letters of which every page looked similar because of her even calligraphy. In contrast, she now needed several attempts to write single words that looked untidy compared with her premorbid handwriting. She did not make spelling or syntactic errors, but her writing tended to become smaller towards the end of each word.

There was no past medical history of note and the patient was without medication. She was fully alert and co-operative. The neurological examination showed only a mild central facial weakness on the right side. No limb weakness or apraxia were detected. Phonemic and semantic word fluency were below average, while vocabulary was normal.

Because the patient's first language was English and her every-day language was German, the patient's writing in both English and German was assessed under a number of different conditions: She was asked to copy, write to dictation and spontaneously. The tests were performed with the right-hand. There was no

subjective or objective difference in her writing between English and German. Letter formation was poor, but when legible, letters were in most cases correctly selected and the spelling was unimpaired (Fig. 1b, see Fig. 1c) for a sample of the patient's premorbid handwriting). Words, pseudo-words and numbers were equally affected. Drawing and reading were adequate. We diagnosed pure apraxic agraphia.

Brain MRI showed an approximately 3×1.5 cm infarction in the left lenticulo-striate artery territory involving the centrum semiovale and the anterior limb of the internal capsule, proximate to the left caudate head (Fig. 1a).

In 1856, Marcé described patients whose speech and writing disorders were not recovered at the same time [1]. He concluded that these skills must be partly independent from each other. In 1867, Ogle introduced the English term 'agraphia' to designate acquired writing disorders [2]. On the basis of his clinical studies, he noted that the ability to write depends on both linguistic and motoric factors. In 1884 Pitres published the first clinical report of pure agraphia [3]. Hodges described a patient with pure apraxic agraphia without limb praxis or language disorder caused by a left frontal cyst [4]. The patient's writing was characterized by poor forms of the graphemes in the absence of spelling errors. Spontaneous writing and copying

were equally impaired. The lesion of the patient extended from the superior surface of the left frontal lobe to the anterior horn of the lateral ventricle. The author hypothesized that damage to an area located in the left superior premotor cortex (corresponding to Exner's area) was responsible for the writing disorder. Left parietal lesions can also lead to apraxic agraphia, probably because sequences of movements for writing cannot be activated, although linguistic knowledge and other sensorimotor functions may be preserved [5]. Croisile *et al.* reported a patient, with a haematoma in the left centrum semiovale, who suffered from impaired grapheme production in the absence of limb apraxia [6]. In contrast to the patient described by Hodges [4] the lesion spared both frontal and parietal cortex, however involvement of the body of the caudate nucleus could not be excluded. This is of importance, as pure agraphia can also be associated with damage to the basal ganglia [7]. The lesion of our patient was located in the centrum semiovale in the vicinity of the caudate head, but did not involve it. Accordingly, our findings confirm the assumption presupposed by Croisile *et al.* [6], that apraxic agraphia (like other forms of apraxia) can result from a selective disconnection of cortico-cortical (fronto-parietal) or cortico-subcortical pathways between left frontal cortex and the left basal ganglia.

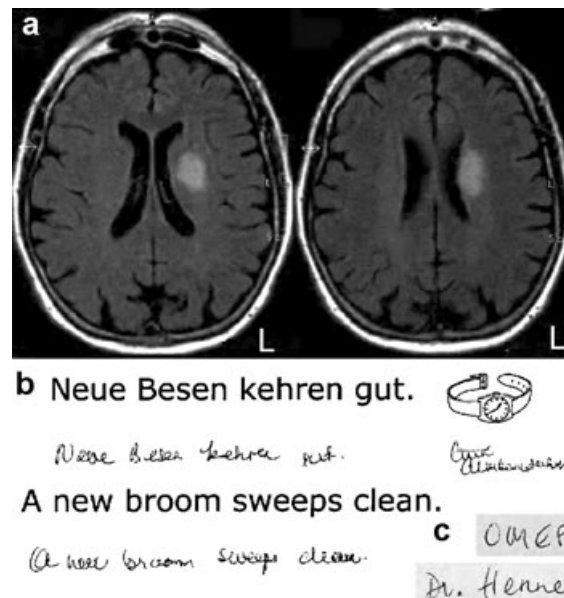


Figure 1 a) FLAIR-weighted MR images, b) sample of the patient's handwriting, c) sample of the patient's premorbid handwriting.

References

1. Marcé LV. Mémoire sur quelques observations de physiologie pathologique tendant à démontrer l'existence d'un principe coordinateur de l'écriture et ses rapports avec le principe coordinateur de la parole. *Compte-rendu de la Société de Biologie, Paris* 1856; **3**: 93–115.
2. Ogle JW. *Aphasia and agraphia*. Report of the MRC of St George's Hospital, London, 1867: 83–122.
3. Pitres A. Considerations sur l'agraphie. *Revue de Médecine* 1884; **4**: 855–873. English translation by Barrière I, Lorch M. The history of written language disorders: Reexamining Pitres' case (1884) of pure agraphia. *Brain and Language* 2003; **85**: 262–270.
4. Hodges JR. Pure apraxic agraphia with recovery after drainage of a left frontal cyst. *Cortex* 1991; **27**: 469–473.
5. Alexander MP, Fischer RS, Friedman R. Lesion localization in apractic agraphia. *Archives of Neurology* 1992; **49**: 246–251.
6. Croisile B, Laurent B, Michel D, Trillet M. Pure agraphia after deep left hemisphere haematoma. *Journal of Neurology, Neurosurgery, and Psychiatry* 1990; **53**: 263–265.
7. Laine T, Marttila RJ. Pure agraphia: a case study. *Neuropsychologia* 1981; **19**: 311–316.