

## LETTER TO THE EDITOR

**Unilateral progressive brain lesions confirmed as multiple sclerosis**K. Mitosek-Szewczyk<sup>a</sup>, P. Luchowski<sup>a</sup>, B. Jarosz<sup>b</sup> and Z. Stelmasiak<sup>a</sup><sup>a</sup>Department of Neurology, Medical University of Lublin; and <sup>b</sup>Neuropathological Laboratory, Department of Neurosurgery, Medical University of Lublin, Lublin, Poland**OnlineOnly:** This article is available online only at [www.blackwell-synergy.com](http://www.blackwell-synergy.com)Correspondence: Krystyna Mitosek-Szewczyk, Department of Neurology, Medical University of Lublin, Jaczewskiego 8, 20-090 Lublin, Poland (tel.: +48 81 7244720; fax: +48 81 7425534; e-mail: [krystyna.mitosek@am.lublin.pl](mailto:krystyna.mitosek@am.lublin.pl)).**Keywords:** brain biopsy, multiple sclerosis, symptomatic epilepsy

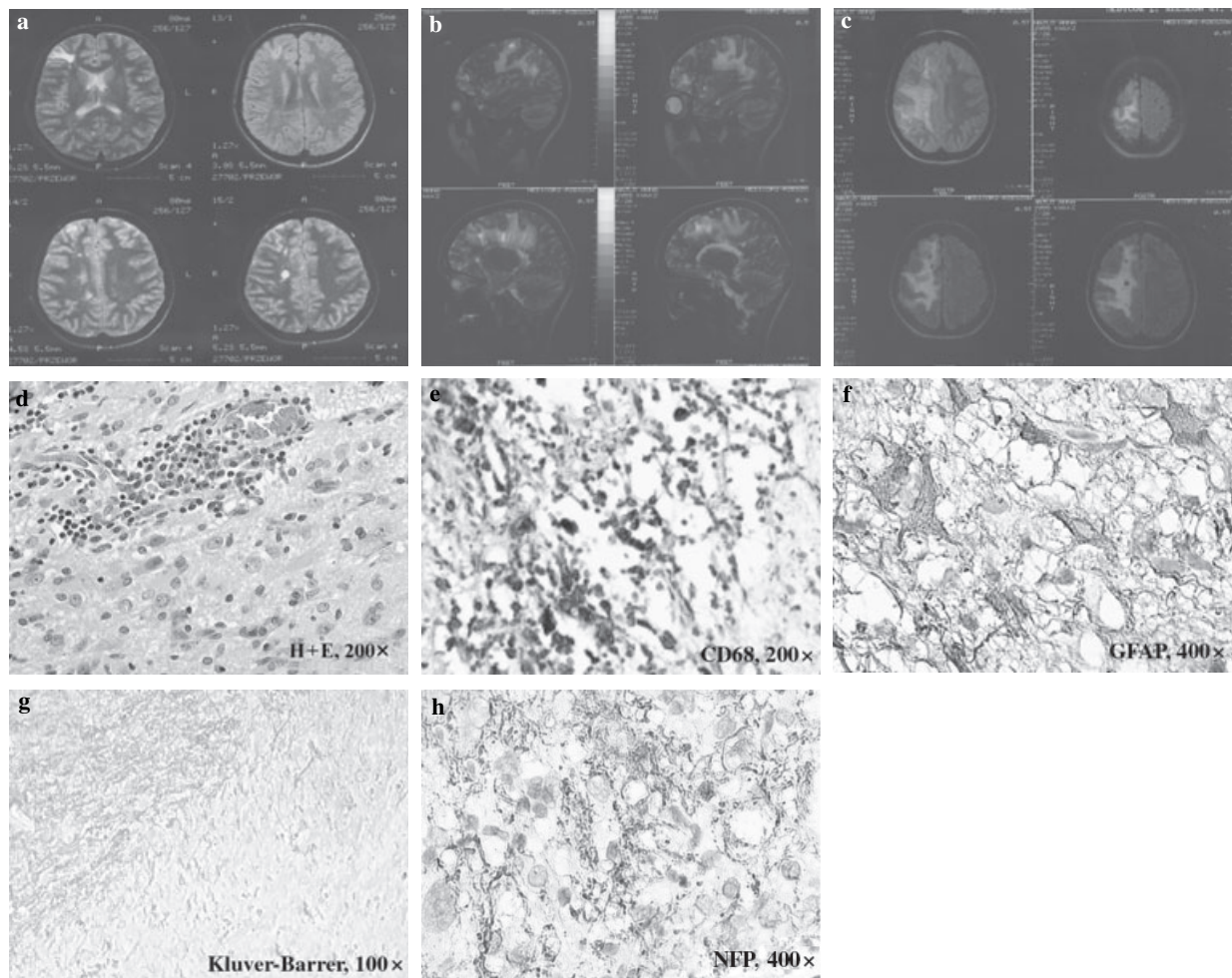
Received 26 September 2005

Accepted 12 December 2005

Multiple sclerosis (MS) often demonstrates highly variable clinical course and some heterogeneity in histopathology [1]. The diagnosis of MS is based on a classic history and symptoms and/or typical findings on magnetic resonance imaging (MRI). Newer MRI techniques, such as MR spectroscopy (MRS) promise to yield important information regarding MS recognition, prognosis, and treatment effects [2]. We report a case of MS confirmed by brain biopsy, that did not fulfill McDonald's criteria [3].

Our patient at the age of 19 had her first episode of seizures (initially adverse, later on grand-mal epilepsy). Physical examination was normal, whilst neurological examination demonstrated four-limb

hyperreflexia, bilaterally presented Babinski's sign and clonus. MRI revealed the presence of few T2 hyperintensities in the periventricular region, two lesions within the corpus callosum, as well as few cortical-subcortical lesions limited to the right hemisphere (Fig. 1a). Vasogenic brain lesion and symptomatic epilepsy was diagnosed. MRI scans, performed 6 months and 3 years later, revealed minimal or even no changes when compared with the previous one. At the age of 24, emotional disturbances were present (panic disorder, generalized anxiety disorder) and the patient was hospitalized in Psychiatric Department. One year later, the occurrence of seizures had increased and she started complaining of left limb weakness. At this time she was admitted to our Department. Neurologically, a slight upper left limb paresis with pyram-



**Figure 1** Magnetic resonance imaging (a–c). Hyperintensities on axial brain images in 1996 (a) and sagittal (b) and axial (c) images 6 years later. Histopathological examination (d–h). Perivascular infiltration of lymphocytes (d) and macrophages (e) within white and gray matter, with reactive gliosis (f). Kluver–Barrera staining showed demyelinated areas (g) with axon preservation (h) (For details see text).

idal signs and four-limb hyperreflexia was present. Standard laboratory workup revealed no abnormalities. Brain imaging study showed huge progress of the process, still limited to the right hemisphere (Fig. 1 b and c). Cerebrospinal fluid examination detected no atypical cells and the glucose level was normal. Meanwhile, the presence of oligoclonal bands was demonstrated. Further, we excluded leucodystrophies, neuroborreliosis, mitochondrial cytopathy and vasculitides. As the diagnosis was uncertain, the patient underwent MRS which suggested active parasitic process rather than myelin breakdown or neoplasm. The absence of antibodies against toxoplasmosis, toxocariasis and cysticercosis rules out the presence of these pathologies. Finally, the patient underwent biopsy and brain pathologic tissue was taken for histopathologic examination. The biopsy material was routinely formalin-fixed, paraffin-embedded and stained with hematoxylin and eosin. Immunohistochemical reactions were performed in the

Department of Clinical Pathology of the Medical University of Lublin using the following antibodies: Glial fibrillary acidic protein (GFAP), Neurofilament protein (NFP) and CD68 (all 1:50). The histopathologic examination revealed perivascular infiltration of lymphocytes (Fig. 1d) and macrophages (CD68+) (Fig. 1e) within white and gray matter with reactive gliosis (GFAP+) (Fig. 1f). Luxol fast blue-cresyl fast violet stain showed demyelinated areas (Fig. 1g) with axon preservation (NFP+) (Fig. 1h), typical findings characteristic of MS disease [4].

In conclusion, we report on a patient with progressive one-side brain abnormalities, diagnosed as MS. Epileptic seizures were one of the first symptoms to be observed and they were in agreement with data demonstrating three to six times higher prevalence of epilepsy in MS patients [5]. To our knowledge, there have been no reports of such long-term disproportion of pathology between hemispheres in the course of MS.

## References

1. Lucchinetti C, Bruck W, Parisi J, Scheithauer B, Rodriguez M, Lassmann H. Heterogeneity of multiple sclerosis lesions: implications for the pathogenesis of demyelination. *Annals of Neurology* 2000; **47**: 707–717.
2. Burlina AP, Aureli T, Bracco F, Conti F, Battistin L. MR spectroscopy: a powerful tool for investigating brain function and neurological diseases. *Neurochemical Research* 2000; **25**: 1365–1372.
3. McDonald WI, Compston A, Edan G *et al.* Recommended diagnostic criteria for multiple sclerosis: guidelines from the International Panel on the diagnosis of multiple sclerosis. *Annals of Neurology* 2001; **50**: 121–127.
4. Lassmann H. Recent neuropathological findings in MS – implications for diagnosis and therapy. *Journal of Neurology* 2004; **251**: IV2–IV5.
5. Poser CM, Brinar VV. Epilepsy and multiple sclerosis. *Epilepsy & Behavior* 2003; **4**: 6–12.