

Valproic Acid Aggravates Epilepsy due to MELAS in a Patient with an A3243G Mutation of Mitochondrial DNA

Chih-Ming Lin · Peterus Thajeb

Received: 24 July 2006 / Accepted: 10 November 2006 /

Published online: 17 January 2007

© Springer Science+Business Media, LLC 2007

Abstract Epilepsy is one of the most common presentations of patients with mitochondrial myopathy, encephalopathy, lactic acidosis, and stroke-like episodes (MELAS). MELAS is typically caused by an A-to-G substitution at nucleotide position 3243 of mitochondrial DNA. Valproic acid, a common anticonvulsant, can actually increase the frequency of seizures in individuals with MELAS. Here, we report a single case-study of a 38-year-old man who presented with focal seizures and had MELAS Syndrome due to the A3243G mitochondrial DNA mutation. Manifestation of epilepsia partialis continua was aggravated by use of valproic acid. Convulsions abated after discontinuation of valproic acid. Our experience suggests that valproic acid should be avoided for the treatment of epilepsy in individuals with mitochondrial disease.

Keywords Epilepsy · Mitochondrial disease · Valproate · Valproic acid · MELAS

Introduction

Mitochondrial disorders constitute a collection of genotypically and phenotypically heterogeneous systemic diseases that affect multiple organ systems. Mitochondrial myopathy, encephalopathy, lactic acidosis, and stroke-like episodes (MELAS) is one of the most common mitochondrial disorders (Chinnery et al., 1997; Dimauro and Davidzon, 2005; Liou et al., 1994). Epileptic and myoclonic seizures are a common feature of MELAS and are typically treated with anticonvulsants. Valproic acid, a commonly used anticonvulsant, has been shown to be epileptogenic when used in treating patients with mitochondrial diseases. Here we present a case study of an individual whose seizures were successfully controlled until his antiepileptic therapy was changed from carbamazepine to valproic acid. The interaction of valproic acid and mitochondrial disorders is also discussed.

C.-M. Lin (✉) · P. Thajeb
Department of Neurology, Mackay Memorial Hospital,
No. 92, Chungshan North Road, Section 2, Taipei, Taiwan
e-mail: googlejoseph@yahoo.com.tw

Case report

A 38-year-old man presented at our department with continuous focal motor convulsions of the left limbs without loss of consciousness in January 1999. He had a history of diabetes mellitus and his mother had a history of bilateral ptosis. Blood tests revealed elevated lactate (87 mg/dL; reference: 5–19 mg/dL) and pyruvate (1.74 mg/dL; reference: 0.3–0.7 mg/dL) levels with a respective ratio of 50. Analysis of the mitochondrial DNA from peripheral blood leukocytes revealed an A-to-G mutation at nucleotide position (np) 3243 in both the patient and his mother.

The patient's seizures were successfully treated with oral carbamazepine CR (400 mg) twice daily until April of 2000 when he had a stroke and subsequently developed a left hemiparesis. Magnetic resonance imaging (MRI) of the brain indicated an acute cerebral infarction involving the right middle cerebral artery (MCA). Magnetic resonance angiography (MRA) showed a focal stenosis of the horizontal portion of the right MCA (M1 segment). His cervical carotid duplex was normal, but his transcranial color-coded duplex showed a high Pulsatility Index (PI) up to 2.1 over the right proximal MCA area. Ictal electroencephalography (EEG) showed independent focal spikes and wave discharges at the right frontal-parietal-temporal area (Fig. 1). The patient was diagnosed with epilepsy partialis continua (EPC). Aspirin (100 mg daily) and coenzyme-Q10 (30 mg daily) taken in three daily doses, were added to the Carbamazepine for secondary stroke prevention and mitochondrial myopathy. The neurological deficits improved and the patient was able to walk without assistance five months later.

Between 2002 and 2005, the patient was hospitalized six times for treatment of episodes of acute conscious disturbance with constant vomiting, seizures, and pneumonia. A MRI revealed multiple new bilateral lesions (Fig. 2). Carbamazepine was replaced by valproic acid 500 mg twice daily on March 2003 and then increased to 1500 mg per day after 60 days. Plasma levels of valproic acid were within the therapeutic range (64 mcg/mL; reference values: 50–100 mcg/mL). Serum aspartate aminotransferase was 26 IU/L (reference value: 5–35 IU/L) and alanine aminotransferase was 20 IU/L (reference value: 5–30 IU/L).

Between March 2003 and August 2005 the patient's seizure frequency increased from once per month to five times per day, severely impairing daily life activities. His seizure severity also worsened from focal convulsions to generalized tonic seizure. He was unable to care for himself and had to live with his mother. The valproic acid was removed from the patient's drug treatment regime and carbamazepine was reinstated. Seizure frequency abated. The patient continues to be seizure-free as of his last follow-up in March, 2006.

Discussion

The clinical features, maternal inheritance pattern, and impairment of the mitochondrial electron transport chain of MELAS were first described by Pavlakis and colleagues (1984). MELAS is the most common mitochondrial disorder in Taiwan (Liou et al., 1994) and results in decreases in mitochondrial protein synthesis, altered calcium homeostasis and impaired nitric oxide metabolism (Scaglia and Northrop, 2006). Patients with MELAS and other mitochondrial disorders have defective oxidative phosphorylation mechanisms, possibly due to defects in mitochondrial complexes I or IV, or both (Pavlakis et al., 1984). The manifestation of epilepsy in MELAS may be due to necrosis of the cerebral cortex and hippocampus, a highly epileptogenic nucleus (Kunz, 2002). An alternative cause of the seizures may be the inhibition of mitochondrial oxidative phosphorylation in these

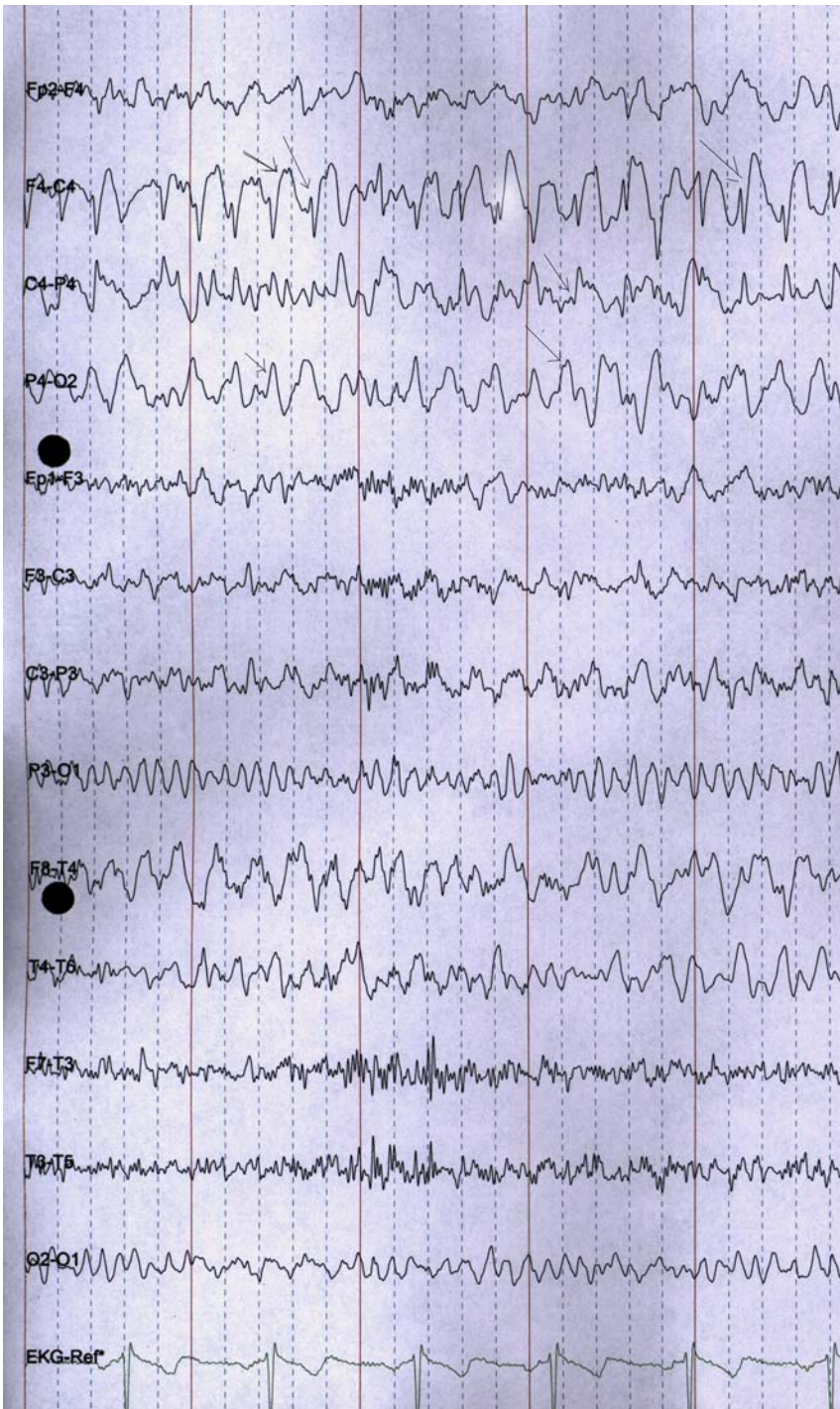


Fig. 1 Electroencephalogram traces for a 38 year old patient with MELAS. Paroxysmal spike-and-wave complexes are located predominantly at the F4-C4, C4-P4, P4-O2 areas and interspersed with a theta activity

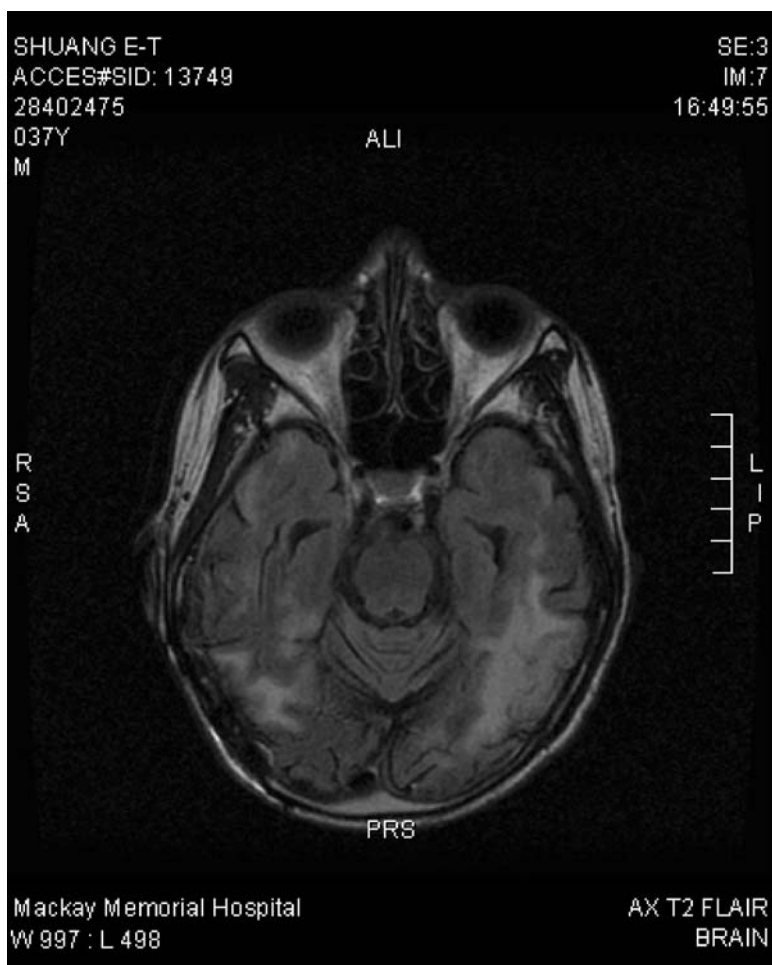


Fig. 2 Brain MRI with FLAIR showed high signal intensities in the bilateral temporal cortical area and the occipital subcortical white matter areas in a patient with MELAS

epileptogenic brain areas (Morris, 1999; Chabrol et al., 1994; Aure et al., 2005). Other multi-organ symptoms are also commonly seen in MELAS. These include diabetes mellitus, hearing loss, and cardiac dysfunction (Aure et al., 2005).

In our patient, the clinical manifestation of MELAS was the focal seizure activity, confirmed by EEG abnormalities. Seizures were initially controlled with carbamazepine. After a stroke and evidence of bilateral lesions, valproic acid was substituted for carbamazepine. However, the change in anti-convulsent therapy resulted in an intolerable increase in seizure frequency. This increase was reversed with the withdrawal of valproic acid.

Valproic acid has a well-known anti-epileptic effect, though the mechanism of action is unclear (Altrup et al., 1992). Valproic acid can also have detrimental effects on the liver or can have a pro-seizure effect in a small number of individuals (Lam et al., 1997; Krahenbuhl et al., 2000; Ponchaut et al., 1992; Kunz, 2002). However, there is evidence that it has an effect on the structure of mitochondria. Altrup and colleagues (Altrup et al., 1992) have

shown that valproic acid can alter the fundamental structures of the mitochondrial membrane by inducing paroxysmal depolarization shifts (PDS). The PDS threshold can be altered by derivatives of valproic acid. Lam and colleagues (1997) have speculated that valproic acid triggers seizures in patients with mitochondrial disorders by impairing the proton pumping activity of Complex IV, cytochrome c oxidase. It has been shown in rodents that valproic acid impairs the activity of Complex IV (cytochrome c oxidase) in the respiratory chain (Ponchaut et al., 1995).

Given the crucial role of Complex IV in the respiratory chain, it is not surprising that valproic acid is able to further precipitate the symptomatology of mitochondrial disorders. Deficiency of cytochrome c oxidase in the liver was proposed to be a risk factor in developing an “encephalopathic” state or hepatic failure for those with mitochondrial diseases (Krahenbuhl et al., 2000; Ponchaut et al., 1992; Kunz, 2002). It is unclear if there is an additional effect of valproic acid that undermines the already fragile oxidative phosphorylation system due to a lack of large-scale studies.

Early diagnosis of mitochondrial disease provides crucial information for both patients and clinical practitioners in terms of seizure management. A diagnosis of a mitochondrial disorder, including MELAS, indicates valproic acid should be counter-indicated for the treatment of seizures. Valproic acid may further exasperate the seizure symptoms of patients with mitochondrial disorders. Though mitochondrial disorders are the rare and the mechanism of action of the valproic acid is unclear, it is advised that physicians be alert to possible mitochondrial diseases and avoid treatment with valproic acid in these patients.

References

- Altrup U, Gerlach G, Reith H, Said MN, Speckmann EJ (1992) Effects of valproate in model nervous system (buccal ganglia of *Helix pomatia*): I. Antiepileptic actions. *Epilepsia* 33:743–752
- Altrup U, Reith H, Speckmann EJ (1992) Effects of valproate in a model nervous system (buccal ganglia of *Helix pomatia*): II. Epileptogenic actions. *Epilepsia* 33:753–759
- Aure K, Jardel C, Lombs A (2005) Mitochondrial diseases: Molecular mechanisms, clinical presentations and diagnosis investigations. *Ann Pathol* 25:270–281
- Chabrol B, Mancini J, Chretien D, Rustin P, Munnich A, Pinsard N (1994) Valproate-induced hepatic failure in a case of cytochrome c oxidase deficiency. *Eur J Pediatr* 153:133–135
- Chinnery PF, Howell N, Lightowers RN, Tumball DM (1997) Molecular pathology of MELAS and MERRF: The relationship between mutation load and clinical phenotypes. *Brain* 120:1713–1721
- Dimauro S, Davidzon G (2005) Mitochondrial DNA and disease. *Ann Med* 37:222–232
- Krahenbuhl S, Brandner S, Kleinle S, Liechi S, Straumann D (2000) Mitochondrial diseases represent a risk factor for valproate-induced fulminant liver failure. *Liver* 20:346–348
- Kunz WS (2002) The role of mitochondria in epileptogenesis. *Curr Opin Neurol* 15:179–184
- Lam CW, Lau CH, Williams JC, Chan YW, Wong LJ (1997) Mitochondrial myopathy, encephalopathy, lactic acidosis and stroke-like episodes (MELAS) triggered by valproate therapy. *Eur J Pediatr* 156:562–564
- Liou CW, Huang CC, Chee EC, Jong YJ, Tsai JL, Pang CY, Lee HC, Wei YH (1994) MELAS Syndrome: Correlation between clinical features and molecular genetic analysis. *Acta Neurol Scand* 90:354–359
- Morris AA (1999) Mitochondrial respiratory chain disorders and the liver. *Liver* 19:357–368
- Pavlakis SG, Phillips PC, DiMauro S, De Vivo DC, Rowland LP (1984) Mitochondrial myopathy, encephalopathy, lactic acidosis, and stroke-like episodes: A distinctive clinical syndrome. *Ann Neurol* 16:481–488
- Ponchaut S, Van Hoof F, Veitch K (1992) Cytochrome aa3 depletion is the cause of the deficient mitochondrial respiration induced by chronic valproate administration. *Biochem Pharmacol* 43:644–647
- Ponchaut S, Van Hoof F, Veitch K (1995) Valproate and cytochrome c oxidase deficiency. *Eur J Pediatr* 154:79
- Scaglia F, Northrop JP (2006) The mitochondrial myopathy encephalopathy, lactic acidosis with stroke-like episodes (MELAS) syndrome: A review of treatment options. *CNS Drugs* 20:443–464