

Re-organization of language function within the right hemisphere

M. Abo^a, H. Takao^b, K. Hashimoto^a,
M. Suzuki^a and N. Kaito^b

Departments of ^a*Rehabilitation Medicine*;
and ^b*Neurosurgery, Jikei University School
of Medicine, Minato-ku, Tokyo, Japan*

OnlineOnly: This article is available online only at www.blackwell-synergy.com

Correspondence: Dr Masahiro Abo,
Department of Rehabilitation Medicine,
Jikei University School of Medicine,
3-25-8, Nishi-Shinbashi, Minato-ku,
Tokyo 105-8461, Japan (tel.: +81 3 3433
1111; fax: +81 3 5497 4120 ; e-mail:
abo@jikei.ac.jp).

Keywords: aphasia, left hemisphere,
MRI, re-organization, right hemisphere,
stroke

Received 6 January 2006

Accepted 21 April 2006

In March 1992, a 43-year-old right-handed woman (Edinburgh Inventory [1]) with no past illness was admitted to our hospital because of sudden-onset aphasia and right hemiplegia. Computed tomography showed a low-density area in the territory of the left middle cerebral artery (MCA). Magnetic resonance images (MRI) taken 2 months later confirmed the left hemisphere infarction within the blood supply area of the MCA (Fig. 1a and b).

The Japanese Standard Language Test for Aphasia (SLTA) was used to evaluate language function. The SLTA consists of auditory verbal comprehension, speaking, reading comprehension, writing, and calculation. The overall response in SLTA is scaled from 0% (most severe) to 100% (normal). The patient could produce only 'a-' and showed severe failure on a sentence level with errors in auditory verbal

comprehension and reading comprehension. Based on SLTA, the type of aphasia in this patient was considered global aphasia. Occupational, physical and speech therapies commenced 3 days after onset, provided 5 days/week, each session lasted 40 min. She showed gradual improvement and in November 1992, she was able to walk and was discharged from the hospital, although the right upper limbs showed disuse of synergic pattern. A repeat SLTA (3 days after onset to discharge) showed improvements with auditory verbal comprehension of 10–80%, speaking of 0–70%, reading comprehension of 20–75% and writing of 0–50%, compared with normal values. She continued speech therapy once a week, but the result of SLTA did not improve after November 1992.

In July 2004, at the age of 55 years (12 years since the first admission), she was admitted again to our hospital because of worsened right hemiplegia. Spasticity of the right upper and lower extremities was lower compared with neurological examination conducted during the first hospitalization. The leg showed flaccid paralysis. MRI taken 2 months later showed infarct lesions in the left hemisphere (Fig. 1c and d). Occupational, physical and speech therapies were provided from day 4 of hospitalization. Four months after the onset of the second episode, she walked using right ankle foot orthosis on the floor. She was later discharged from the hospital. The scores of auditory verbal comprehension, speaking and reading comprehension of SLTA at 1, 2 and 6 months after the second episode were almost identical to those recorded in November 1992, except for the writing ability, which was especially worse after the second episode (50% → 5%).

Functional imaging in adults during/after recovery from aphasia due to left-hemisphere lesion reported increased hemodynamic activation of contralateral structures in association with verbal repetition [2] and comprehension tasks [3]. Furthermore, these reactions showed significant correlation with training-induced improvement of verbal comprehension [4]. These observations are further corroborated by the clinical data presented here. Most presumably, the loss of auditory/reading comprehension and speaking after the first left-sided stroke was compensated for by the contralateral hemisphere because the subsequent ipsilateral infarction did not compromise these recovered language functions. The further decline of writing abilities, considered to be bound to the angular gyrus of the left hemisphere, can be explained by the larger extension of the second ischemic event in posterior direction. Both strokes, by and large, spared the rostral area of blood supply of the anterior cerebral artery. As these structures do not pertain to the perisylvian cortex, a significant contribution to language recovery is rather improbable.

References

1. Oldfield RC. The assessment and analysis of handedness: the Edinburgh inventory. *Neuropsychologia* 1971; **9**: 97–113.
2. Abo M, Senoo A, Watanabe S, *et al.* Language-related brain function during word repetition in post-stroke aphasics. *Neuroreport* 2004; **15**: 1891–1894.
3. Thulborn KR, Carpenter PA, Just MA. Plasticity of language-related brain function during recovery from stroke. *Stroke* 1999; **30**: 749–754.
4. Musso M, Weiller C, Kiebel S, Muller SP, Bulau P, Rijntjes M. Training-induced brain plasticity in aphasia. *Brain* 1999; **122**: 1781–1790.

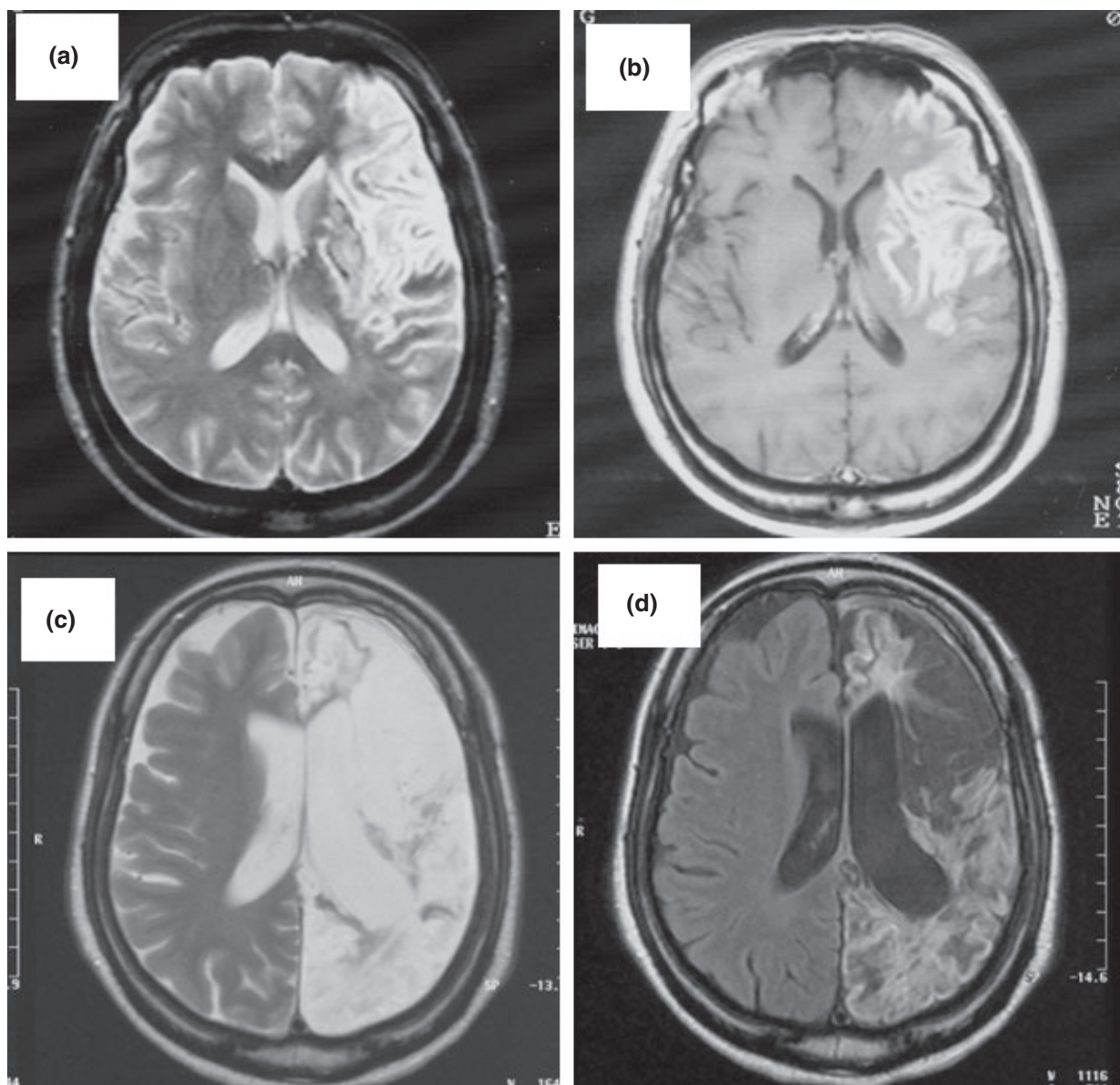


Figure 1 Magnetic resonance imaging; (a) T2 imaging, (b) flare image (May, 1992). The T2 image and the Flare image showed high intensity areas in the left hemisphere. Note the cerebral infarct in the territory of the left middle cerebral artery (prefrontal, insular, precentral, central and lenticulostriate artery). (c) T2 imaging, (d) flare image (September, 2004). Note the cerebral infarct in the areas of the left anterior and left posterior cerebral arteries, indicating that the cerebral infarct is in the left hemisphere. Note also the porencephaly in the old infarction area.