

Case reports

Diffusion-weighted magnetic resonance images in a patient
with neuropsychiatric lupus

Yasuyuki Iguchi *, Kazumi Kimura, Tsuyoshi Inoue, Yuji Ueno, Yoshihide Sunada

Department of Stroke Medicine and Neurology, Kawasaki Medical School, 577 Matsushima, Kurashiki City, Okayama 701-0192, Japan

Received 1 April 2005; accepted 10 December 2005

Abstract

We report herein the case of a 27-year-old woman with neuropsychiatric lupus who experienced disturbance of consciousness and left hemiparesis. Steroid treatment was initiated and symptoms resolved within 2 months. T2- and diffusion-weighted imaging revealed signal hyperintensity in the right cerebral cortex. Apparent diffusion coefficient values in these lesions increased, but normalized over 2 months. These findings indicate that cortical lesions in patients with neuropsychiatric lupus could represent vasogenic oedema.

© 2006 Elsevier Ltd. All rights reserved.

Keywords: Neuropsychiatric lupus; Diffusion-weighted MRI; Apparent diffusion coefficient**1. Introduction**

Systemic lupus erythematosus (SLE) is characterized by widespread inflammatory changes in the connective tissue of skin and the systemic organs. The central nervous system is involved in 25–50% of all patients with SLE, representing neuropsychiatric lupus (NPSLE).¹ However, the pathogenesis of NPSLE is poorly understood. Conventional magnetic resonance imaging (MRI) can be used to visualize abnormalities in >50% of patients with NPSLE.² Diffusion-weighted MRI (DWI) is a powerful tool for detecting early ischaemic brain lesions with a significant reduction in apparent diffusion coefficient (ADC). To the best of our knowledge, the findings of DWI and ADC mapping have not previously been reported for a patient with NPSLE. We report herein DWI and ADC values for a patient with NPSLE.

2. Case report

A 27-year-old Japanese woman in the 3rd month of pregnancy developed fever and an itchy rash in March 2004. The patient had no previous history of rheumatic or collagen diseases. She visited a clinic and was treated

with 10 mg/day prednisolone for urticaria. In April 2004, she was admitted to a general hospital with general malaise, myalgia and fever, and 20 mg/day prednisolone was administered. She experienced emotional instability 7 days later, and was transferred to our hospital on 25 April 2004.

On admission, responses to external stimuli were reduced and the patient was unable to walk unaided. Neurological examination revealed disturbance of consciousness, but no aphasia, apraxia or neglect. Both eyes were in the midline and ocular movements were normal in all directions. Pupils were equal and reactive to light. Tongue protrusion was slightly to the left, and left hemiparesis was present without left central facial weakness. The patient's height was 163 cm and her body weight was 58 kg. Her temperature was 37.2 °C, her blood pressure was 110/54 mmHg and her heart rate was regular at 86 beats/min. Laboratory examination findings on admission were as follows: erythrocyte count, $430 \times 10^4/\text{mm}^3$; haemoglobin, 11.9 g/dL; hematocrit, 36.8%; leukocyte count, $14 \times 10^4/\text{mm}^3$; platelets $12.9 \times 10^4/\text{mm}^3$. Urinalysis revealed no abnormalities. Hepatic and renal functions were normal. Immunological studies showed: anti-nuclear antibody (+); anti-dsDNA antibody, 5 IU/L (normal, <10 IU/L); C-reactive protein, 5.49 mg/dL (normal, <0.03 mg/dL); serum IgG, 936 mg/dL (normal, 1000–1800 mg/dL); anti-cardiolipine β_2 -GPI antibody, 1.24 U/mL (normal, 3.5 U/mL); and

* Corresponding author. Tel.: +81 86 462 1111; fax: +81 86 462 1199.
E-mail address: yigu@med.kawasaki-m.ac.jp (Y. Iguchi).

lupus anticoagulant (-). Cell count, protein content and level of glucose in cerebral spinal fluid (CSF) were normal.

The patient was examined the day after admission using a commercially available echo-planer instrument on a 1.5-T MR unit (Signa EchoSpeed Horizon; GE Medical Systems, Milwaukee, WI, USA). Conventional MRI including T1-weighted imaging (T1WI) (repetition time [TR]/echo time [TE], 400 ms/15 ms), T2WI (TR/TE, 4000 ms/90 ms) and fluid-attenuation inversion recovery (FLAIR) imaging (TR/TE, 10 000 ms/100 ms) were performed. Other imaging parameters included: signals acquired, 1; field-of-view, 24 cm; acquisition matrix, 320×256 ; and section thickness, 6 mm with a 1.0-mm intersection gap. Diffusion gradients were applied sequentially in three orthogonal directions: anteroposterior, left–right, and superior–inferior. Imaging was performed using the following parameters: TR/TEeff, 5500 ms/100 ms; and b values, 0 and 1000 s/mm². An inversion recovery pulse (TI, 2200 ms) designed to suppress CSF was used in an attempt to limit the influence of partial-volume averaging effects on the accuracy of diffusion measurements. Field of view was 24 cm \times 24 cm, and was displayed using a 128×128 matrix. A section thickness of 5 mm and an intersection gap of 1.5 mm were used. Acquisition time for all DWI examinations was less than 1 min. The three orthogonal DW images were averaged to create an isotropic DW image. Finally, the image obtained with $b = 0$ s/mm² and the resultant isotropic image with $b = 1000$ s/mm² were transferred to an imaging workstation (Advantage Windows workstation; GE Medical Systems). One small (<40 mm²) region of interest (ROI) was placed in the hyperintense lesion of the right cortex on the isotropic image with $b = 1000$ s/mm². As a control for signal intensity, the same size ROI was placed in the same (mirror image) location in the contralateral hemisphere. ADC was calculated using a previously published and validated method using FuncTool 2000 software (GE Medical Systems).³ DWI and T2WI showed asymmetrical, laminar increases in signal intensity in the right frontotemporal cortex. DWI also showed signal hyperintensity in the left frontal cortex. However, no abnormalities in the basal ganglia, brainstem or cerebellum on either DWI or T2WI were observed (Fig. 1A,B). ADC was higher in the hyperintense lesion on DWI than on the contralateral side (0.92×10^{-3} mm²/s in the right cortex *vs* 0.80×10^{-3} mm²/s in left). Time-of-flight MR angiography and carotid ultrasonography showed no occlusive lesions in the cerebral arteries.

A discoid rash appeared on the torso of the patient 7 days after admission. Laboratory examination showed progressive lymphocytopenia and thrombocytopenia. SLE was diagnosed on the basis of the American College of Rheumatology criteria.⁴ She was treated with pulse corticosteroid therapy (1000 mg methylprednisolone sodium succinate every 3 days). The patient's temperature normalized and the rash disappeared. Neurological manifestations resolved within 20 days after starting pulse corticosteroid therapy.

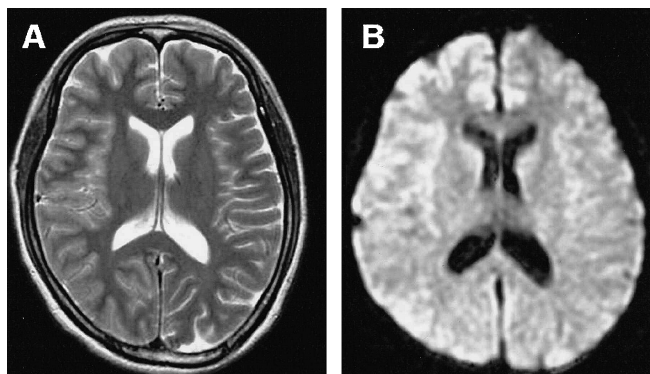


Fig. 1. (A) Axial T2-weighted MRI (T2WI) shows cortical hyperintensity in the right front-temporal lobe on initial hospitalization (2 days after onset of symptoms, disturbance of consciousness). (B) Diffusion-weighted imaging (DWI) also shows cortical hyperintensity in the same location as that found in T2WI.

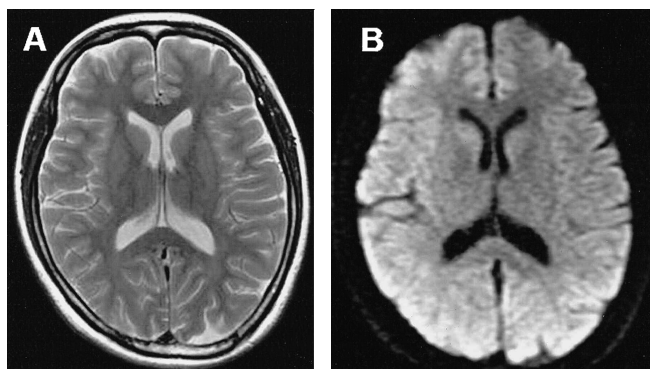


Fig. 2. (A) Follow-up T2-weighted MRI (2 months after admission) shows normal findings. (B) Dif shows normal intensity in the right frontal cortex.

Two months after admission, DWI and T2WI showed normal intensity in the right frontal cortex corresponding to the areas of lesions on initial DWI (Fig. 2A,B). ADC in these lesions was restricted (0.81×10^{-3} mm²/s in the right *vs* 0.79×10^{-3} mm²/s in the left).

3. Discussion

The present case demonstrates cortical involvement in a patient with NPSLE. Previous reports of conventional MRI in such patients noted that T1- and T2-weighted MRI showed signal hyperintensity and hypointensity in deep white matter lesions, respectively.⁵ Bell et al. described two types of distribution of deep white matter lesions in patients with NPSLE: focal and diffuse.⁶ Such lesions in deep white matter on T2WI were correlated with neuropsychiatric syndromes.² However, the present patient experienced neuropsychiatric symptoms, but had no abnormalities in deep white matter on T1- or T2-weighted MRI.

To the best of our knowledge, cortical involvement in NPSLE has not previously been described. Changes in DWI intensity in the cortex are seen in other diseases, such as viral meningitis, leptomenigeal metastasis and cerebral infarction. The present case could be differentiated from

those diseases based on laboratory data and physical findings.

DWI in this case showed signal hyperintensity in the cortex, and ADC values in these lesions were high. Pathological changes in these lesions could represent interstitial or vasogenic oedema.⁷ Vasogenic oedema has been observed in several conditions, including hypertensive encephalopathy, cyclosporine toxicity, hyperperfusion after carotid endarterectomy, HIV encephalopathy, trauma as diffuse axonal injury and multiple sclerosis.⁸ In the present case, DWI intensity changed from high to normal in parallel with the recovery of neurological deficits. This finding might reflect improvements in vasogenic oedema. SLE patients sometimes experience brain infarctions, particularly those with Libman-Sacks (L-S) endocarditis. In one study of 10 SLE patients with cortical infarct, nine displayed cardiac sources, and L-S endocarditis was observed in all of these patients.⁹ In general, signal intensity is high for DWI and the ADC value is restricted in acute cerebral ischemia.⁸ The ADC value is helpful for differentiating acute ischaemic lesions from other pathological lesions.

In our patient, the ADC value was high, which indicated vasogenic oedema rather than acute ischaemic lesions. Thus, when SLE patients suffer from stroke-like events such as hemiparesis or aphasia, determining the ADC value can help to distinguish acute infarction from NPSLE. This could represent an important tool for deciding on treatment strategies. In conclusion, MRI in our patient with NPSLE detected cortical involvement, indicating vas-

ogenic oedema. Measuring ADC can help to distinguish acute infarction from NPSLE.

References

1. Harris EN, Hughes GR. Cerebral disease in systemic lupus erythematosus. *Springer Semin Immunopathol* 1985;**8**:251–66.
2. Sanna G, Piga M, Terryberry JW, et al. Central nervous system involvement in systemic lupus erythematosus: cerebral imaging and serological profile in patients with and without overt neuropsychiatric manifestations. *Lupus* 2000;**9**:573–83.
3. Eastwood JD, Engelter ST, MacFall JF, et al. Quantitative assessment of the time course of infarct signal intensity on diffusion-weighted images. *AJNR Am J Neuroradiol* 2003;**24**:680–7.
4. Tan EM, Cohen AS, Fries JF, et al. The 1982 revised criteria for the classification of systemic lupus erythematosus. *Arthritis Rheum* 1982;**25**:1271–7.
5. Weiner SM, Otte A, Schumacher M, et al. Alterations of cerebral glucose metabolism indicate progress to severe morphological brain lesions in neuropsychiatric systemic lupus erythematosus. *Lupus* 2000;**9**:386–9.
6. Bell CL, Partington C, Robbins M, et al. Magnetic resonance imaging of central nervous system lesions in patients with lupus erythematosus. Correlation with clinical remission and antineurofilament and anti-cardiolipin antibody titers. *Arthritis Rheum* 1991;**34**:432–41.
7. Ebisu T, Naruse S, Horikawa Y, et al. Discrimination between different types of white matter edema with diffusion-weighted MR imaging. *J Magn Reson Imaging* 1993;**3**:863–8.
8. Schaefer PW, Grant PE, Gonzalez RG. Diffusion-weighted MR imaging of the brain. *Radiology* 2000;**217**:331–45.
9. Devinsky O, Petito CK, Alonso DR. Clinical and neuropathological findings in systemic lupus erythematosus: the role of vasculitis, heart emboli, and thrombotic thrombocytopenic purpura. *Ann Neurol* 1988;**23**:380–4.

doi:10.1016/j.jocn.2005.12.050

Acute autonomic sensory and motor neuropathy associated with central nervous system disturbance

Kenji Sakai ^{a,*}, Yasuko Matsumoto ^a, Ichiro Nozaki ^b, Masahito Yamada ^a

^a Department of Neurology and Neurobiology of Aging, Kanazawa University Graduate, School of Medical Science, 13-1 Takaramachi, Kanazawa 920-8054, Japan

^b Department of Neurology, Fukui Prefectural Hospital, Fukui, Japan

Received 5 October 2005; accepted 8 December 2005

Abstract

We report a 45-year-old woman with acute autonomic sensory and motor neuropathy (AASMN) showing central nervous system (CNS) disturbance. She presented with disturbance of consciousness, complex partial seizures with automatisms, autonomic, sensory and motor neuropathy, showing severe orthostatic hypotension and neurogenic bladder. Nerve conduction studies and nerve biopsy indicated axonal degeneration involving both the myelinated and unmyelinated fibers. Muscle biopsy revealed neurogenic muscular atrophy.

* Corresponding author. Tel.: +81 76 265 2292; fax: +81 76 265 0817.
E-mail address: ksakai@bri.niigata-u.ac.jp (K. Sakai).