

Cavernous angiomas of the central nervous system in children

R. MICHAEL SCOTT, M.D., PATRICK BARNES, M.D., WILLIAM KUPSKY, M.D., AND LESTER S. ADELMAN, M.D.

Departments of Neurosurgery, Radiology, and Pathology, Children's Hospital, and Departments of Pathology and Neurology, New England Medical Center, Boston, Massachusetts

✓ A surgical series of 19 patients under the age of 18 years with pathologically verified cavernous angioma is presented. Most lesions were located in the cerebral hemispheres, but four were in the pons or midbrain, two in the diencephalon, and one in the spinal cord. Fourteen patients presented with an acute or progressing neurological deficit, three with seizures, one infant with irritability, and one with headache alone. Five patients had family histories of vascular malformations of the central nervous system, and five had multiple lesions. Surgery for small or deep lesions was aided considerably by intraoperative ultrasonographic or stereotactic localization techniques. Pathological examination of the resected malformations revealed a complex histology containing not only typical closely approximated cavernous vessels, but also areas of marked proliferation of granulation tissue and partially re-endothelialized hemorrhage, suggesting a mechanism for the apparent growth of certain cavernous angiomas. The postoperative results were good, with only one patient suffering a permanent worsening of neurological status after surgery. Incomplete resection was initially carried out in five patients, two of whom rebelled within 1 year after operation. Long-term follow-up findings in these patients have emphasized the unusual history of certain of these malformations.

KEY WORDS • cavernous angioma • arteriovenous malformation • natural history • pathology • brain stem • spinal cord

CAVERNOUS angioma of the cerebrum, cerebellum, brain stem, and spinal cord is being diagnosed with increasing frequency in children, probably because of the common use of computerized tomography (CT) and magnetic resonance (MR) imaging. We report on 19 pediatric patients with cavernous angioma operated on over a 10-year period at Children's Hospital and the New England Medical Center. We review the clinical, radiological, and pathological findings in this series of patients, present surgical strategies for removal of the lesions, and discuss the natural history of cavernous angioma.

Clinical Material and Methods

Between January 1, 1981, and December 31, 1990, one of us (R.M.S.) operated on 19 patients under the age of 18 years for pathologically verified cavernous angioma. The children ranged in age from 7 months to 17 years, with an average of 9.1 years. There were nine girls and 10 boys. Table 1 summarizes the relevant clinical data. The most common symptom at presentation was acute or subacute onset of focal neurological

deficit, which occurred in 14 of the 19 children. Seizures were the initial complaint in three, and one teenager complained only of headache, although headache was a prominent complaint in six of the 14 children who had either seizures or focal deficit. One 7-month-old child (Case 19), the sibling of Case 12, was noted to be irritable by his mother; in this infant, CT unexpectedly showed hemorrhage from one of multiple malformations. In the series, 10 malformations were located in the hemispheres, four in the brain stem, two in the cerebellum, two in the basal ganglia (one of which extended into the midbrain), and one in the spinal cord. Multiple lesions were seen in five of the 19 patients. A family history of known cavernous angioma or cerebrovascular malformation was determined for five patients, three of whom had multiple lesions on scanning; two patients in this subset were siblings (Cases 10 and 17), both presenting with hemorrhage.

Neuroimaging Studies

All patients in this series with cavernous malformations underwent CT with and without contrast enhance-

Cavernous angiomas of the CNS in children

TABLE 1
*Characteristics of pediatric patients operated on for
pathologically verified cavernous angioma**

| Case No. | Age at Surgery | Location | Multiple Lesions | Family History | Presenting Symptom |
|----------|----------------|---------------------------|------------------|----------------|-------------------------|
| 1 | 11 yrs | cerebellum | — | — | deficit |
| 2 | 7 yrs | posterofrontal | — | — | seizures |
| 3 | 5 yrs | pons | — | — | deficit |
| 4 | 11 yrs | pons | — | — | deficit |
| 5 | 5 yrs | temporal | — | — | seizures |
| 6 | 6 yrs | occipital | — | — | deficit |
| 7 | 7 yrs | pons | + | — | deficit |
| 8 | 8 yrs | frontal | — | — | seizures |
| 9 | 17 yrs | parietal para-ventricular | — | — | headache |
| 10 | 8 yrs | temporal | — | + | deficit, seizure |
| 11 | 8 yrs | cerebellum | + | — | deficit |
| 12 | 10 mos | diencephalon | + | + | deficit |
| 13 | 13 yrs | parietal para-ventricular | — | — | deficit, headache |
| 14 | 13 yrs | cervical spinal cord | — | — | deficit |
| 15 | 13 yrs | subfrontal basal ganglia | — | — | deficit |
| 16 | 17 yrs | parietal | + | + | deficit, focal seizures |
| 17 | 5 yrs | parieto-occipital | — | + | deficit, headache |
| 18 | 12 yrs | midbrain | — | — | deficit |
| 19 | 7 mos | parietal para-ventricular | + | + | irritability |

* Abbreviations: — = feature not present; + = feature present.

ment. Thirteen of the 19 patients were also studied by MR imaging using T₁- and T₂-weighted images. Cerebral angiography was carried out in eight patients and spinal angiography in one.

Surgical Technique

Removal of the superficial lesions in this series was uncomplicated. These malformations were often visible on the surface of the brain, or the overlying pia was stained by hemosiderin. Deep paraventricular and basal ganglia lesions were approached via small corticectomies through noneloquent cortex with the aid of intra-operative stereotactic or ultrasonographic localization. The brain-stem malformations were operated on through the subtemporal route in three patients, the tentorium being divided to reach lateral pontine lesions in two. One dorsal pontine lesion was approached through the floor of the fourth ventricle. In every patient in this series, the malformation was surrounded by yellow gliotic brain tissue and/or liquefied or organized clot, confirming our clinical suspicion that the malformations had bled at some point before surgery. In some patients, the surrounding brain was firm and fibrotic, and histological examination revealed that this tissue contained dense fibrillary gliosis and extensive calcification, particularly along blood vessels.

When the malformations were initially exposed, they resembled a cluster of mulberries or purple grapes and

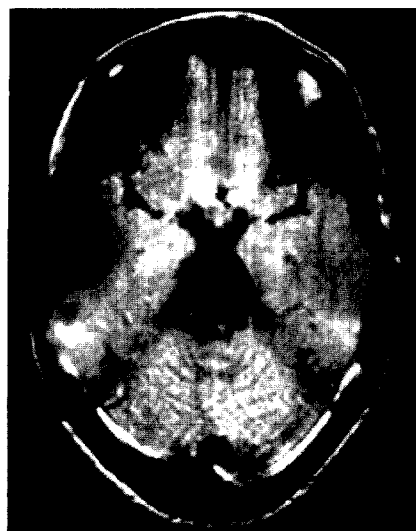


FIG. 1. Magnetic resonance image in Case 4, an 18-year-old woman, 7 years after subtotal removal of pontine cavernous angioma. Signal changes occupy one-half of the pons, yet she remains neurologically normal and has not rebled clinically.

received their blood supply from a variable number of small low-pressure vessels around the periphery of the malformation. The malformations were removed by dissecting around their margin with bipolar cautery, with a No. 5 or No. 7 suction used directly on the malformation for traction. The malformations were often firm enough to be grasped with microforceps to exert gentle traction while feeders from adjacent brain were being coagulated or microdissectors used to define dissection planes. Globules at the periphery of the malformation could be reduced in size with bipolar cautery to render deeper portions more accessible, although eventually an irreducible, firm, fibrous mass resulted. If the malformation was inadvertently torn, bleeding was usually venous, slow, and easily stopped with bipolar cautery or with the application of small pledgets of Gelfoam and gentle pressure. These malformations could also be safely debulked or partially excised to permit improved visualization of their deeper portions.

Illustrative Cases

Case 4

This 11-year-old girl presented with a 5- to 6-week history of progressive double vision, facial paresthesias, ataxia, and headache. A CT scan demonstrated a right ventrolateral pontine mass associated with hemorrhage; there was minimal contrast enhancement. Clot was drained from the lateral aspect of the pons, and the cavernous angioma was subtotally resected via a subtemporal exploration. The patient made a complete recovery and subsequently returned to full activities. Follow-up CT and MR imaging studies revealed striking abnormalities of the right side of the pons (Fig. 1),

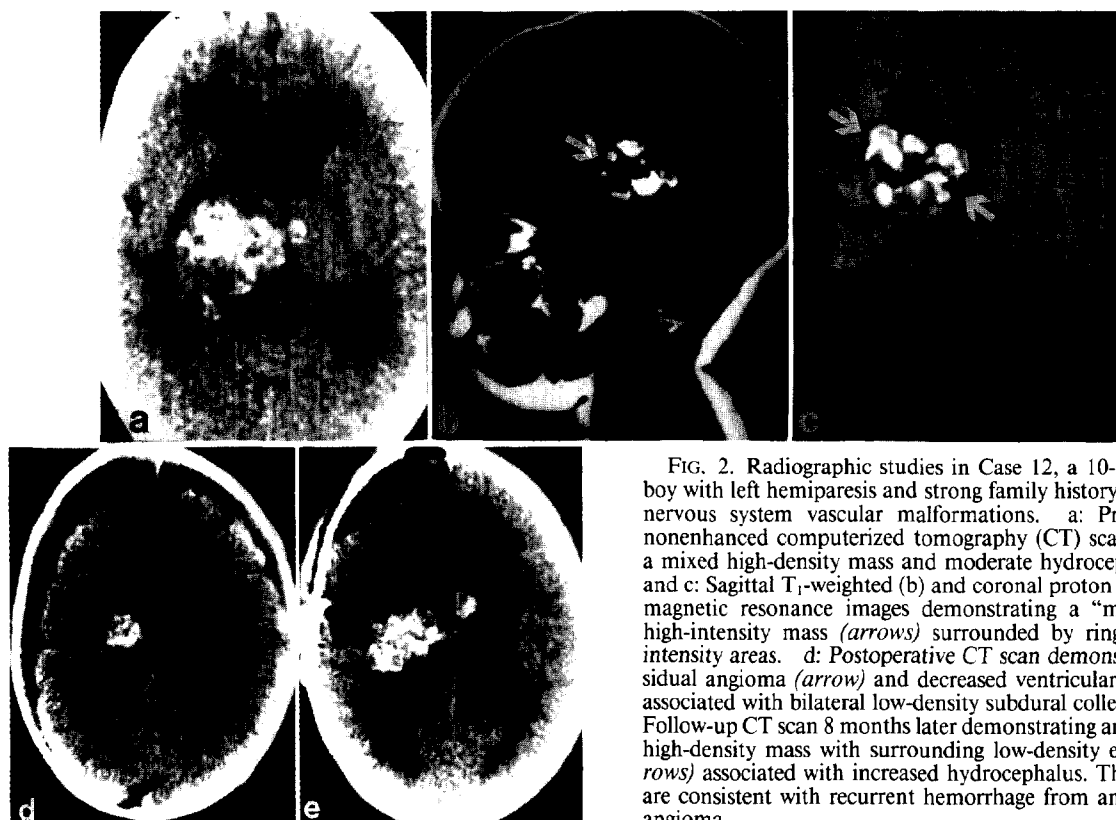


FIG. 2. Radiographic studies in Case 12, a 10-month-old boy with left hemiparesis and strong family history of central nervous system vascular malformations. a: Preoperative nonenhanced computerized tomography (CT) scan showing a mixed high-density mass and moderate hydrocephalus. b and c: Sagittal T₁-weighted (b) and coronal proton density (c) magnetic resonance images demonstrating a "multicystic" high-intensity mass (arrows) surrounded by ring-like low-intensity areas. d: Postoperative CT scan demonstrating residual angioma (arrow) and decreased ventricular dilatation associated with bilateral low-density subdural collections. e: Follow-up CT scan 8 months later demonstrating an enlarging high-density mass with surrounding low-density edema (arrows) associated with increased hydrocephalus. The findings are consistent with recurrent hemorrhage from an enlarging angioma.

which were thought to be most consistent with residual malformation and vascular changes and calcifications secondary to hemorrhage. Six years after surgery, she remains neurologically normal.

Comment. This patient had a prolonged hemorrhage-free clinical course after subtotal resection. Residual malformation is clearly present on late follow-up studies, with cavernous angioma occupying more than one-half of the pons on axial and sagittal MR imaging. Yet the patient remains asymptomatic and neurologically normal more than 6 years after subtotal resection of the angioma.

Case 12

This 10-month-old boy was brought for evaluation of the subacute onset of left hemiparesis. He was irritable but remained alert and awake; CT and subsequent MR imaging revealed a large lesion filling the right thalamus and extending into the midbrain (Fig. 2a–c). A second lesion was noted in the left frontal deep white matter. There was a strong family history of cerebrovascular malformations: several years previously his father had undergone surgery for a temporal cavernous angioma, which had hemorrhaged, and his paternal grandmother had died of an intracerebral hemorrhage at a young age.

This infant's malformation was approached through the corpus callosum. The portion of the malformation extending into the midbrain could not easily be seen or safely excised from this approach, and the procedure was terminated with an estimated 30% to 40% of the malformation still in place (Fig. 2d). The patient had no increase in deficit following the procedure, but 8 months later returned with irritability and worsening hemiparesis. Magnetic resonance imaging and CT demonstrated that the lesion had rebled and enlarged (Fig. 2e), and a repeat resection posterolaterally through the atrium of the lateral ventricle resulted in removal of the entire thalamic portion of the malformation. Hydrocephalus and subdural fluid collections required shunting.

Eight months later, another hemorrhage occurred, causing large unequal and nonreactive pupils and irritability, and the patient underwent a third resection under the temporal lobe to remove the residual midbrain remnant. The patient was neurologically unchanged after this procedure and continues to have a moderate hemiparesis and mild facial weakness. During the past year, his 7-month-old brother (Case 19) underwent CT because of irritability, which unexpectedly revealed a right parietal hemorrhage from one of multiple cavernous angiomas; this lesion was excised

Cavernous angiomas of the CNS in children

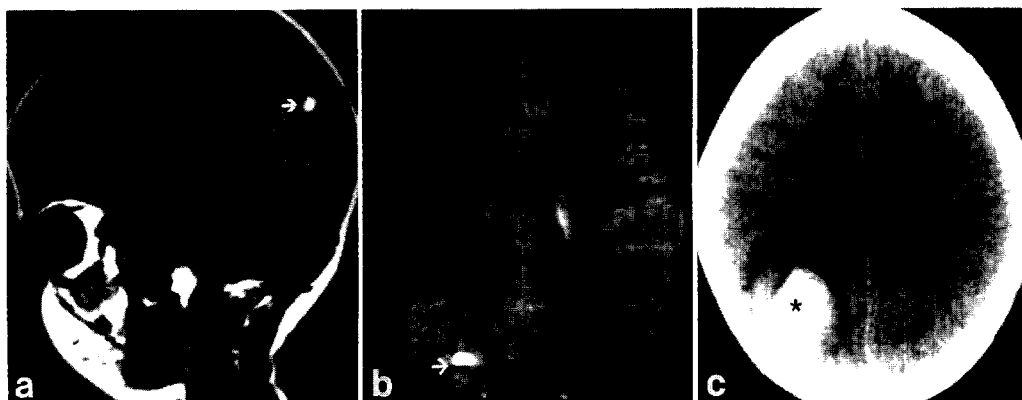


FIG. 3. Radiographic studies in Case 17, a 5-year-old boy, the sibling of Case 10. a and b: Screening sagittal T₁-weighted (a) and axial T₂-weighted (b) magnetic resonance images showing a focal right parietal lesion (arrows) with high-intensity (methemoglobin) and low-intensity (hemosiderin) signals. c: Computerized tomography scan 1 year later, following the acute onset of headache and lethargy, demonstrating a high-density hemorrhage (asterisk) with surrounding edema.

uneventfully, but follow-up MR images have clearly documented the appearance of at least one "new" malformation, which has developed in the frontal white matter since surgery.

Comment. This patient had an initial episode of bleeding at age 10 months, then repetitive bleeding and enlargement of the lesion throughout a 2-year period despite two subtotal surgical resections. This case demonstrates quite clearly that subtotal resection cannot be expected to eliminate the occurrence of rebleeding in the residual malformation. This patient has tolerated a large amount of major intracranial surgery, with an intact opposite hemisphere and brain-stem function and remarkably little ipsilateral neurological deficit considering the extensive surgery carried out in the mid-brain, hypothalamus, and thalamus. The cavernous angiomas in this family have been notable for their aggressive course and early presentation, and MR documentation of a newly visible lesion on sequential scans in the younger child is unique in this series.

Case 17

This 5-year-old boy is the sibling of Case 10. Four of the mother's six siblings had cavernous angiomas on screening MR imaging; one of these individuals had undergone radiation therapy for a pineal region tumor that in retrospect was probably not a neoplasm. This child's screening MR image revealed an asymptomatic parieto-occipital lesion 1 cm in size that was not operated on because of its size and apparent benignity (Fig. 3a and b). One year later, he suffered a large hemorrhage from the malformation (Fig. 3c) and underwent successful removal of the lesion, without neurological sequelae.

Comment. This patient's history demonstrates the difficulty of determining whether surgery should be

carried out on small asymptomatic lesions detected on incidental or screening examinations. The patient's 1-cm lesion appeared innocuous, yet a serious hemorrhage eventually occurred. In contrast, his 45-year-old aunt's screening studies demonstrated multiple small lesions, none of which had bled clinically.

Results

Neuroimaging Studies

Computerized tomography and MR studies revealed findings characteristic of cavernous angioma^{10,15} in all patients studied by these techniques in this series. The CT scans showed roughly circular or nodular lesions of increased signal attenuation, often containing punctate areas that suggested focal calcification. In 12 of the 18 patients with intracranial lesions, the nonenhanced study also revealed evidence of recent hemorrhage — usually areas of increased density with surrounding low-density edema and mass effect adjacent to the well-circumscribed lesion. The contrast-enhanced scan often showed a very slight increase in signal attenuation. On MR images, available preoperatively for 13 patients, the lesions were mottled or multicystic, with central high intensities. Peripheral marginal or ring-like low-intensity areas were present, and became more apparent on T₂-weighted images; MR imaging was also more accurate than CT in showing the multiple lesions in five patients. Often, these smaller additional lesions were low-intensity foci, seen best on T₂-weighted images. Sequential MR images in one patient (Case 19) demonstrated at least one "new" lesion on follow-up review. Cerebral angiography was obtained in eight patients and was negative in all, except for mass effect related to the presence of hemorrhage. In the one child with a cervical spinal cord cavernous malformation, spinal angiography was obtained and was negative.

TABLE 2
Surgical results and follow-up data for 19 patients with cavernous angioma*

| Case No. | Total Removal | Surgical Complication | Rebleed | Follow-Up Period (yrs) |
|----------|---------------|-----------------------|---------------------|------------------------|
| 1 | + | — | — | 9 |
| 2 | + | — | — | 9 |
| 3 | — | — | + | 8 |
| | | | (10 days postop) | |
| 4 | — | — | — | 7 |
| 5 | + | — | — | 6 |
| 6 | + | — | — | 4 |
| 7 | — | — | — | 3 |
| 8 | + | — | — | 3 |
| 9 | + | — | — | 3 |
| 10 | + | — | — | 2.5 |
| 11 | + | — | — | 2.5 |
| 12 | — | + | + | 2.5† |
| | | | (8 & 16 mos postop) | |
| 13 | + | — | — | 2 |
| 14 | + | — | — | 1.5 |
| 15 | + | — | — | 1.5 |
| 16 | + | + | — | 1‡ |
| 17 | + | — | — | 1 |
| 18 | — | + | — | 1§ |
| 19 | + | — | — | 0.5 |

* Abbreviations: — = feature not present; + = feature present.

† In Case 12, two additional operations were required to remove the malformation completely. Surgery was complicated by hydrocephalus and subdural fluid collections. Rehemorrhaging occurred twice prior to complete removal; see case report in text.

‡ In Case 16, an increased neurological deficit postoperatively had resolved at the 1-year follow-up examination.

§ In Case 18, the preoperative neurological deficit was worsened postoperatively and persisted at the 1-year follow-up examination.

Clinical Recovery and Complications

Table 2 summarizes the surgical results and follow-up data in the 19 patients in the series. The clinical recovery of these patients was very satisfactory. All but two patients with cerebral hemisphere lesions made complete recoveries from their preoperative neurological deficits, and no patient presenting with seizure or headache was worsened by the operation. One patient suffering an increased hemiparesis after surgery for an extensive motor strip lesion that had previously bled (Case 16) had returned to her preoperative baseline at follow-up review 1 year later. The patient with the spinal cord malformation (Case 14) improved from his preoperative status, but still has residual hemiparesis and spasticity, although he is ambulatory and fully independent. One child with a midbrain cavernous angioma that had previously bled twice (Case 18) suffered increased hemiparesis and bilateral partial third nerve palsies that persisted at the 1-year follow-up review.

The major problem encountered at surgery was the ascertainment of total removal, particularly in eloquent areas of the brain or brain stem, since fronds of malformation can be inadvertently dissected from these

lesions, particularly in areas of intense gliosis, and planes of dissection can be lost. In five patients, portions of the cavernous malformation were intentionally or inadvertently left behind. The case histories of four of these patients have been presented in detail elsewhere.³² Two of these children rebled within 1 year of surgery: in one (Case 3), the rebleed occurred 10 days after initial surgery; she made a complete recovery, however, and there have been no further episodes over the following 8 years. The second child with a rebleed (Case 12) required two additional procedures to excise completely a large thalamic and midbrain malformation. In 16 of the 19 children, the morbidity related to the surgery itself was negligible, and the remarkable neurological stability of the children after undergoing extensive or deep procedures was one of the most gratifying aspects in this series.

Histological Findings

Almost all of the pathological specimens in the present series had a complex histological appearance, with only portions of the lesions containing typical back-to-back cavernous vessels (Fig. 4). Most lesions contained areas of fibrous scarring, recent or old hemorrhage, and areas of calcification. Gliosis, hemosiderosis, and mineralization of the microvasculature were common in the adjacent brain, and nests of entrapped glial tissue were frequently seen within the substance of the malformation. There was often marked proliferation of granulation tissue accompanied by a number of thin-walled vessels adjacent to the areas of recent hemorrhage. In certain specimens, the large hemorrhage was partially or almost completely contained by an endothelialized lining (Fig. 5).

Discussion

Presentation and Diagnosis

Cavernous angiomas of the central nervous system were considered rare as recently as the beginning of this decade,^{30,34} particularly in children and infants,³⁷ but they are now being diagnosed with increasing frequency. In some pediatric institutions, they are the most common cerebrovascular malformation encountered.³¹ A review by Herter, *et al.*,¹¹ in 1988 noted that 330 cases had been reported, with 166 of these published within the last 11 years; more than 25% of these were in children under the age of 18 years. Gangemi, *et al.*,⁹ discussed the occurrence of cavernous angioma in the 1st year of life, finding 11 such cases in the literature and adding two of their own. Only two of the 19 patients in the present series became symptomatic before the age of 1 year (Cases 12 and 19). These lesions are more apt to be diagnosed in adults; in a series reported by Farmer, *et al.*,⁷ of 31 patients with histologically verified cavernous angioma, only three were aged 18 years or under, and all three presented with seizures.

A familial prevalence of cavernous angioma has been

Cavernous angiomas of the CNS in children

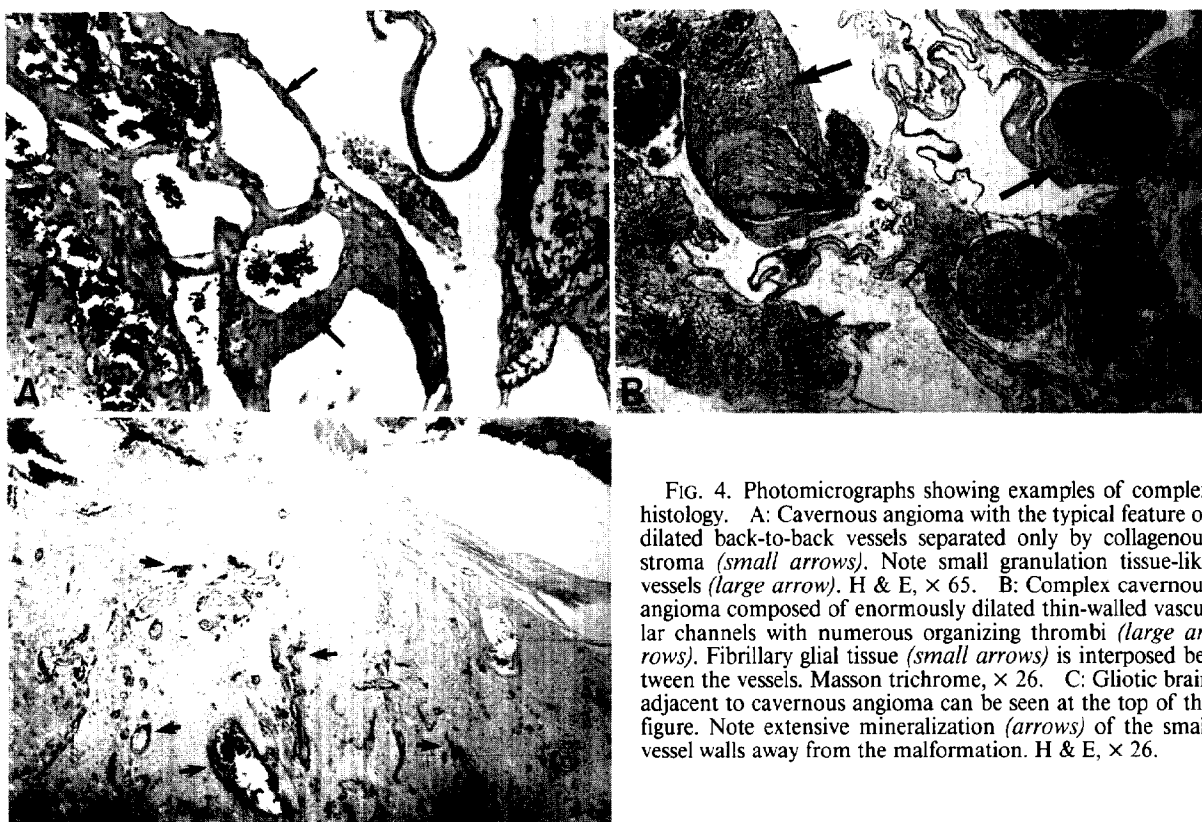


FIG. 4. Photomicrographs showing examples of complex histology. A: Cavernous angioma with the typical feature of dilated back-to-back vessels separated only by collagenous stroma (*small arrows*). Note small granulation tissue-like vessels (*large arrow*). H & E, $\times 65$. B: Complex cavernous angioma composed of enormously dilated thin-walled vascular channels with numerous organizing thrombi (*large arrows*). Fibrillary glial tissue (*small arrows*) is interposed between the vessels. Masson trichrome, $\times 26$. C: Gliotic brain adjacent to cavernous angioma can be seen at the top of the figure. Note extensive mineralization (*arrows*) of the small vessel walls away from the malformation. H & E, $\times 26$.

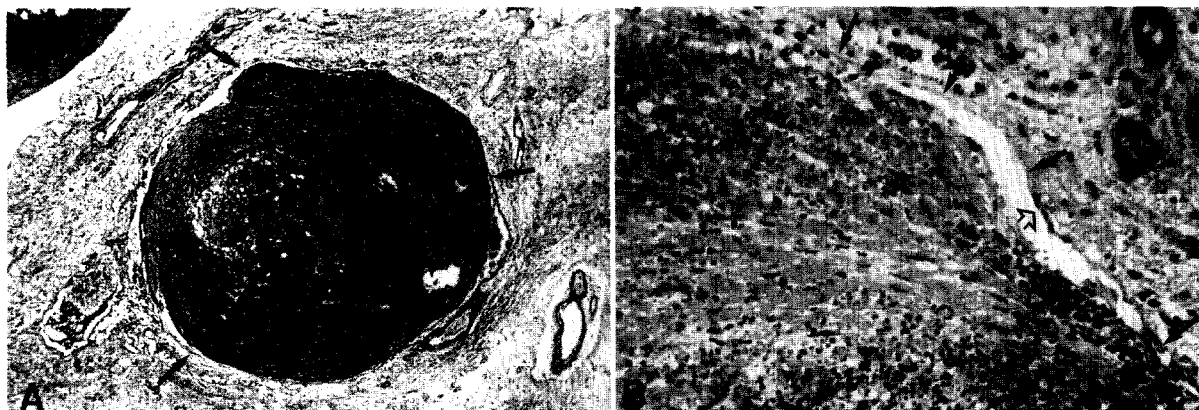


FIG. 5. A: Photomicrograph showing organized laminated intraparenchymal hemorrhage into gliotic brain adjacent to cavernous angioma in the upper left corner. Note the thin membrane/wall at the interface of the hematoma and brain (*arrows*). Masson trichrome, $\times 26$. B: Higher magnification of the same specimen showing the interface between organizing hematoma and gliotic brain parenchyma and the presence of thin discontinuous membrane (*filled arrows*). Note flattened endothelial nuclei on both the hematoma and parenchymal surfaces (*open arrows*). Two mineralized capillary-sized vessels are present in the gliotic tissue at the upper right. H & E, $\times 160$.

described, particularly in Hispanic families.^{17,26} Clark³ documented the familial occurrence of cavernous angioma in a 1970 report. Rigamonti, *et al.*,²⁶ described the familial form of the disorder, which was present in more than 50% of their 24 original patients and ap-

peared predominantly in Mexican-American patients. None of the three families in this series was Hispanic, and the findings of Rigamonti, *et al.*, may be related to regional population concentrations rather than a true preponderance. We have performed screening MR im-

aging of relatives and siblings whenever other family members had a history of neurological disorder or headache.

Clinically, these vascular malformations present with seizures, the sudden onset of neurological deficit and headache, or slowly progressive deficits simulating tumor. In a review of the literature, Simard, *et al.*,³³ noted that the clinical presentations tended to be equally distributed among these three categories. Buckingham, *et al.*,¹ reported on the surgical treatment of seven children with cavernous angioma, of whom six presented with seizures and one with neurological deficit secondary to hemorrhage. Fortuna, *et al.*,⁸ presenting a series of six pediatric patients, were able to document 50 previous cases reported prior to 1989, of which 45% presented with seizures, 27% with hemorrhage, 16% with increased intracranial pressure, and 11% with focal neurological deficits. Among the five pediatric patients in the series of Pozzati, *et al.*,²⁴ three presented with seizures and two with neurological deficits. In our series, however, the clinical presentation in two-thirds of the patients was that of a neurological deficit (progressive in three patients) with or without headache.

Lesions in the spinal cord occur quite rarely. A recent review of spinal cord cavernous angiomas documented only 37 published cases, and only one of the 19 malformations in this series was in the spinal cord.²³ These patients have a variable clinical presentation, ranging from rapid neurological deterioration secondary to hemorrhage to a slowly evolving chronic myelopathy.⁴ Spinal cavernous malformations may occur in association with intracranial lesions in both familial and non-familial forms¹⁴ and have been reported in association with hydrocephalus that has reversed following removal of the cavernous angioma.²⁵

In the early part of this series, the majority of patients were operated on to establish a diagnosis and rule out the presence of a malignant brain tumor. As CT technology improved and MR imaging became available, the diagnosis from these studies alone was often quite clear, and surgery was carried out to excise the lesion in order to prevent further hemorrhage rather than for diagnostic purposes. Cerebral arteriography is not necessary if the diagnosis is strongly suspected from the initial studies and large vascular channels are not seen on MR images. Arteriography was negative in the eight cases in this series in which it was performed, but demonstration of these lesions by angiography has been reported by Numaguchi, *et al.*,²¹ after prolonged administration of contrast material. The risks of this technique in children do not seem warranted, given the characteristic CT and MR findings. Dynamic CT with bolus injection of contrast medium also reveals a progressive uptake of contrast agent within these lesions over time; in a 43-year-old woman not included in this series, this technique was helpful in confirming the diagnosis of cavernous angioma.

This slow pattern of opacification explains why these lesions are so difficult to demonstrate by standard ar-

teriograms and why the lesions can be manipulated so vigorously at surgery without fear of massive hemorrhage. Positron emission tomography as well as single-photon emission CT should also be effective in differentiating cavernous angiomas from neoplastic disease in the brain⁵ and for postoperative follow-up purposes to ascertain total removal; however, these techniques have not been widely applied in pediatric patients. Stereotactic biopsy has been performed safely in children with cavernous angioma despite the apparent danger of hemorrhage; one patient in this series had the diagnosis confirmed by this technique at another institution, with no morbidity resulting.

Pathology

Cavernous angioma is defined in the neuropathological literature as a cerebrovascular malformation containing closely approximated, abnormal, dilated vessels that are not separated by significant amounts of neural tissue.^{2,12,29,38} It is now apparent, however, that the majority of lesions referred to in the past as cavernous angiomas only partially fulfill this diagnostic criterion.

In our patients, the small blood vessels and the chronic granulation and scar tissue accompanying the typical vascular anomaly resembled the constituents of organizing subdural hematoma ("subdural membranes"). The presence of organizing hematoma, endothelialized membranes surrounding the hematoma, and entrapped glial tissue suggests a mechanism for growth of these lesions. It is possible that growth is due to rupture with hemorrhage of these thin-walled vessels with repeated re-endothelialization of hemorrhagic cavities, growth of new blood vessels as part of the organization of the hematomas, and the laying down of additional fibrous scar tissue. Growth of the cavernous angioma was in fact demonstrated on sequential scanning in three patients in the present series; although these lesions are not neoplastic in the classic sense, they have been noted to present as progressing mass lesions. Murakami, *et al.*,²⁰ described a large encapsulated chronic hematoma associated with a cavernous angioma in a 14-year-old boy and suggested that the hemorrhage from the angioma encouraged the development of a chronic hematoma; they also make the analogy to a chronic subdural hematoma and suggest that repeated bleeding from the capillaries in the capsule caused the mass gradually to expand.

Natural History

The behavior of central nervous system cavernous malformations is unlike that of cavernous malformations elsewhere in the body, which frequently grow rapidly during the neonatal period and then almost invariably involute spontaneously.¹⁹ Cavernous angiomas of the central nervous system can present at any age³⁶ or may never become symptomatic, being detected only at postmortem examination or as an incidental finding on an MR or CT study. Although cavernous angiomas may cause fatal hemorrhage,¹⁸ the

Cavernous angiomas of the CNS in children

natural history of these lesions, treated and untreated, is still not clear.²² The rarity of cavernous angiomas in surgical series reported until recently and the inability to image them satisfactorily prior to the advent of CT and MR technology make it difficult to state with certainty the long-term prognosis of either symptomatic or asymptomatic lesions. Therefore, the management of asymptomatic cavernous angiomas detected either incidentally or as part of the screening of relatives of affected patients remains unclear. Long-term studies regarding prognosis of patients studied by MR imaging are just beginning to appear in the literature. A recent retrospective review of patients diagnosed by MR imaging estimated that continuing symptoms developed in 40% of these patients, with hemorrhage recurring in 8% over a variable follow-up interval; no patient in that series was followed for more than 6 years, however, and most were followed for considerably shorter intervals. All of the recurrent hemorrhages appeared in patients under the age of 35 years, but the report did not distinguish pediatric from adult patients.²⁷

Treatment Recommendations

It has been our policy to recommend surgery for patients with cavernous angioma if the lesion is safely accessible, is currently symptomatic either by mass effect and/or hemorrhage or seizure, or shows evidence of having bled in the past. In patients with multiple lesions, several of which appear to have bled, we have recommended surgery on easily accessible symptomatic lesions only. We have described one patient in this series with an accessible asymptomatic lesion in the right parieto-occipital area measuring less than 1 cm in diameter on screening MR images, who nevertheless had a spontaneous hemorrhage from the lesion 1 year later, fortunately causing no permanent morbidity. Five patients in the present series have undergone incomplete resection, with residual malformation seen on follow-up scans. One of these patients (Case 12) had two episodes of rebleeding, and the lesion enlarged on follow-up studies. Although it is not known if partial excision affects the natural history of the cavernous malformation, the other four patients remain asymptomatic at follow-up intervals ranging from 9 months to 9 years. Evidence of old hemorrhage at virtually every operation for cavernous angioma suggests that these lesions do bleed frequently and silently, typically with hemorrhages of small volume and low pressure. These small hemorrhages are presumably not life-threatening unless they are of a critical volume or in a critical location. Some lesions expand with time, and certain patients in this and other series¹⁶ have had progression of neurological deficits without clear evidence of repeated bleeding on radiological imaging.

The treatment of cavernous angioma in the brain stem and basal ganglia has been controversial, but recent reports suggest that surgical exploration should be considered when the patient's clinical course is one of repetitive and progressive neurological deficits, even

if the malformation is in a difficult-to-reach location.^{6,13,28} Most series have reported improvement in pre-existing neurological deficits postoperatively.^{6,13} Fahlbusch, *et al.*,⁶ suggested that surgery for cavernous angiomas in the brain stem should be carried out soon after hemorrhage since they considered that surgical excision was facilitated when the hematoma was not completely organized. However, two of their four patients worsened following surgery: one operated on within weeks of hemorrhage and the other months after the last clinical event. The authors concluded that an initial hemorrhage in such lesions should not indicate the need for immediate surgery but that repetitive clinical events demanded extirpation of the lesion.

Our Case 18 demonstrated that the initial hemorrhage of a brain-stem cavernous malformation need not herald an immediate period of increased risk of rebleeding since 3 years elapsed before the next hemorrhage in this youngster with a midbrain lesion. Despite the most meticulous surgical efforts, however, the patient was left with a permanently increased neurological deficit postoperatively. We conclude that the risks of surgical treatment must be carefully assessed in patients with cavernous malformations in critical areas of the brain, even if rebleeding has occurred.

More data from MR imaging series with long-term follow-up review will be needed to assess the natural history of the cavernous angioma and to determine the role of surgery and other therapies, such as stereotactic small-field irradiation and gamma knife or proton beam therapy, in their treatment. Although stereotactically focused high-energy irradiation by a variety of techniques has been proposed as treatment for cavernous angiomas in inaccessible locations, very little regarding the efficacy of these modalities has appeared in the literature. Most lesions so treated have not been pathologically verified and may have included low-flow arteriovenous malformations and venous malformations as well as cavernous angiomas. It has not been possible to draw meaningful conclusions about the best treatment from series reported thus far. There also appears to be an increased risk of treatment-induced associated neurological deficit for small, critically located malformations. In one such series of 32 patients with angiographically occult vascular malformations, six patients had experienced recurrent hemorrhage and four had worsened from probable radiation-induced injury after a 2-year follow-up period.³⁵ We have therefore been reluctant to recommend such therapies for the pediatric patient with a cavernous angioma because of uncertainties regarding the long-term effects of these treatments in the developing brain combined with the unclear ultimate prognosis of the malformation.

Acknowledgments

The author wishes to acknowledge colleagues at the New England Medical Center, in particular Samuel M. Wolpert, M.D., Department of Neuroradiology, for help and advice in

the evaluation and treatment of many of these patients. Joan Daniels helped in the preparation of the manuscript.

References

1. Buckingham MJ, Crone KR, Ball WS, et al: Management of cerebral cavernous angiomas in children presenting with seizures. *Childs Nerv Syst* 5:347-349, 1989
2. Burger PC, Vogel FS: *Surgical Pathology of the Nervous System and Its Coverings*, ed 2. New York: John Wiley & Sons, 1982, pp 411-418
3. Clark JV: Familial occurrence of cavernous angioma of the brain. *J Neurol Neurosurg Psychiatry* 33:871-876, 1970
4. Cosgrove GR, Bertrand G, Fontaine S, et al: Cavernous angiomas of the spinal cord. *J Neurosurg* 68:31-36, 1988
5. Ericson K, von Holst H, Mosskin M, et al: Positron emission tomography of cavernous haemangiomas of the brain. *Acta Radiol (Diagn)* 27:379-383, 1986
6. Fahlbusch R, Strauss C, Huk W, et al: Surgical removal of pontomesencephalic cavernous hemangiomas. *Neurosurgery* 26:449-457, 1990
7. Farmer JP, Cosgrove GR, Villemure JG, et al: Intracerebral cavernous angiomas. *Neurology* 38:1699-1704, 1988
8. Fortuna A, Ferrante L, Acqui M, et al: Cerebral cavernous angioma in children. *Childs Nerv Syst* 5:201-207, 1989
9. Gangemi M, Longatti P, Maiuri F, et al: Cerebral cavernous angiomas in the first year of life. *Neurosurgery* 25:465-469, 1989
10. Gomori JM, Grossman RI, Goldberg HI, et al: Occult cerebral vascular malformations: high-field MR imaging. *Radiology* 158:707-713, 1986
11. Herter T, Brandt M, Szüwart U: Cavernous hemangiomas in children. *Childs Nerv Syst* 4:123-127, 1988
12. Jellinger K: Vascular malformations of the central nervous system: a morphological overview. *Neurosurg Rev* 9:177-216, 1986
13. Kashiwagi S, van Loveren HR, Tew JM Jr, et al: Diagnosis and treatment of vascular brain-stem malformations. *J Neurosurg* 72:27-34, 1990
14. Lee KS, Spetzler RF: Spinal cord cavernous malformation in a patient with familial intracranial cavernous malformations. *Neurosurgery* 26:877-880, 1990
15. Lemme-Plaghos L, Kucharczyk W, Brant-Zawadzki M, et al: MRI of angiographically occult vascular malformations. *AJR* 146:1223-1228, 1986
16. Martin NA, Wilson CB, Stein BM: Venous and cavernous malformations, in Wilson CB, Stein BM (eds): *Intracranial Arteriovenous Malformations*. Baltimore: Williams & Wilkins, 1984, pp 234-245
17. Mason I, Aase JM, Orrison WW, et al: Familial cavernous angiomas of the brain in an Hispanic family. *Neurology* 38:324-326, 1988
18. McCormick WF, Hardman JM, Boulter TR: Vascular malformations ("angiomas") of the brain, with special reference to those occurring in the posterior fossa. *J Neurosurg* 28:241-251, 1968
19. Mulliken JB, Young AE: *Vascular Birthmarks. Hemangiomas and Malformations*. Philadelphia: WB Saunders, 1988
20. Murakami S, Sotsu M, Morooka S, et al: Chronic encapsulated intracerebral hematoma associated with cavernous angioma: a case report. *Neurosurgery* 26:700-702, 1990
21. Numaguchi Y, Kishikawa T, Fukue M, et al: Prolonged injection angiography for diagnosing intracranial cavernous hemangiomas. *Radiology* 131:137-138, 1979
22. Ojemann RG, Heros RC, Crowell RM: *Surgical Management of Cerebrovascular Disease*, ed 2. Baltimore: Williams & Wilkins, 1988, pp 401-413
23. Pagni CA, Canavero S, Forni M: Report of a cavernoma of the cauda equina and review of the literature. *Surg Neurol* 33:124-131, 1990
24. Pozzati E, Padovani R, Morrone B, et al: Cerebral cavernous angiomas in children. *J Neurosurg* 53:826-832, 1980
25. Ramos F Jr, de Toffol B, Aesch B, et al: Hydrocephalus and cavernoma of the cauda equina. *Neurosurgery* 27:139-142, 1990
26. Rigamonti D, Hadley MN, Drayer BP, et al: Cerebral cavernous malformations. Incidence and familial occurrence. *N Engl J Med* 319:343-347, 1988
27. Robinson JR, Little JR, Awad I: Natural history of cavernous angioma. *Stroke* 21:171, 1990 (Abstract)
28. Roda JM, Alvarez F, Isla A, et al: Thalamic cavernous malformation. Case report. *J Neurosurg* 72:647-649, 1990
29. Russell DS, Rubinstein LJ: *Pathology of Tumours of the Nervous System*, ed 5. Baltimore: Williams & Wilkins, 1989, pp 730-736
30. Savoirdo M, Strada L, Passerini A: Intracranial cavernous hemangiomas: neuroradiologic review of 36 operated cases. *AJNR* 4:945-950, 1983
31. Scott RM: Cerebral cavernous malformations. *N Engl J Med* 319:1414, 1990 (Letter)
32. Scott RM: Subtotal removal of cavernous angiomas of the brain stem and thalamus in children, in Marlin AE (ed): *Concepts in Pediatric Neurosurgery* 10. Basel: Karger, 1990, pp 129-136
33. Simard JM, Garcia-Bengochea F, Ballinger WE Jr, et al: Cavernous angioma: a review of 126 collected and 12 new clinical cases. *Neurosurgery* 18:162-172, 1986
34. Stein BM: Comment on: Vaquero J, Leunda G, Martinez R, et al: Cavernomas of the brain. *Neurosurgery* 12:210, 1983
35. Steinberg GK, Levy RP, Fabrikant JI, et al: Stereotactic heavy-charged-particle bragg peak radiosurgery for angiographically occult intracranial vascular malformations. *Stroke* 21:172, 1990 (Abstract)
36. Voigt K, Yaşargil MG: Cerebral cavernous haemangiomas or cavernomas. Incidence, pathology, localization, diagnosis, clinical features and treatment. Review of the literature and report of an unusual case. *Neurochirurgia* 19:59-68, 1976
37. Yamasaki T, Handa H, Yamashita J, et al: Intracranial cavernous angioma angiographically mimicking venous angioma in an infant. *Surg Neurol* 22:461-466, 1984
38. Zülch KJ: *Brain Tumors. Their Biology and Pathology*, ed 3. Berlin: Springer-Verlag, 1986, pp 451-457

Manuscript received January 2, 1991.

Accepted in final form June 18, 1991.

Address reprint requests to: R. Michael Scott, M.D., Department of Neurosurgery, Children's Hospital, 300 Longwood Avenue, Boston, Massachusetts 02115.



