

Periodic Lateralized Epileptiform Discharges in Neurosyphilis

Mohan L. Noone, Sanjib Sinha, Arun B. Taly, and Siddappa Chandrika

Department of Neurology, NIMHANS, Bangalore, India

Summary: We report two patients of neurosyphilis with periodic lateralized epileptiform discharges (PLEDs) in the EEG. Patient 1, a 32-yr-old man manifested with rapidly progressive cognitive decline and abnormal behavior and recurrent generalized tonic-clonic seizures. EEG revealed periodic epileptiform discharges arising from the anterior temporal and frontal region, predominantly from the right. Diffusion weighted MRI of brain did not show any focal restricted diffusion. Patient 2, a 33-yr-old woman presented with 2-year history of behavioral abnormali-

ties, generalized tonic-clonic seizures and unconcerned urinary incontinence. EEG revealed PLEDs arising from the left anterior temporal region. Her CT scan showed gross cerebral atrophy. Both the patients improved partially with treatment and PLEDs resolved completely. PLEDs may be recorded in EEG of patients with neurosyphilis without imageological evidence of focal cerebral lesion. **Key Words:** EEG—Neurosyphilis—PLED—Seizures.

Periodic lateralized epileptiform discharges (PLEDs) are EEG abnormalities characterized by repetitive spike or sharp wave complexes, recurring at a variable intervals of 0.5–3 s. These may be focal, lateralized over one hemisphere (PLEDs) or occur independently over both hemispheres (bi PLEDs). These have been frequently described in acute destructive lesions of cerebral cortex like cerebral infarctions and focal encephalitis such as like herpes simplex encephalitis. While recurrent seizures and status epilepticus are known to occur in neurosyphilis (Primavera et al., 1998), reports of PLEDs in neurosyphilis are rare.

We report two patients of Neurosyphilis with PLEDs without any focal cerebral lesion and discuss the possible pathogenesis.

CASE DESCRIPTION

Patient 1

A 32-year old goldsmith presented with rapidly progressive cognitive decline and altered sexual and eating behavior of 4-month duration. A week prior to presentation he had recurrent episodes of generalized tonic-clonic seizures. At admission he was partially disoriented and had mini mental score examination—Folstein (MMSE) score of 19/30. Detailed neuropsychological assessment

revealed deficits of recent memory and executive function, suggesting involvement of temporal and frontal lobes. Ocular movements, pupils and fundi were normal. There were no focal deficits. Muscle stretch reflexes were normal and plantar response was flexor.

Hemogram and routine biochemical investigations were normal. Serum VDRL (reactive in 1:128 dilutions) and Treponema Pallidum Hemagglutination (TPHA) tests were positive. Serology for HIV I and II was negative. CSF revealed 30 cells (20 lymphocytes and 10 mononuclear cells), raised protein of 77 mg/dL and normal glucose (64 mg/dL). CSF VDRL was reactive in 1:2 dilutions. PCR for herpes simplex virus was negative. His wife tested negative for VDRL. CT scan (brain) showed mild diffuse cerebral atrophy. Gadolinium-MRI revealed mild diffuse cerebral atrophy. There was no restricted diffusion in diffusion-weighted images. (DWI, Fig. 1A–C) A 21-channel scalp interictal electroencephalograph (EEG), recorded for 30 min, revealed mild diffuse slowing of background activity. There were PLEDs consisting of sharp waves/spikes and slow waves, recurring at approximately 1 Hz over the right side, arising from the anterior temporal and frontal region. These discharges were less abundant and had a lower amplitude on the left side. (Fig. 2A)

He received phenytoin 1000 mg IV slow loading dose followed by a maintenance dose of 100 mg three times daily. Serial EEG on day 2 of hospitalization also revealed PLEDs that did not respond to administration of intravenous lorazepam (4 mg). Intravenous crystalline penicillin (4 million units 4th hourly) was administered for 2 weeks. A repeat EEG after 14 days of treatment showed

Accepted July 26, 2006

Address correspondence and reprints to Dr. Sanjib Sinha at Department of Neurology, National Institute of Mental Health and Neurosciences (NIMHANS), Bangalore 560 029, Karnataka, India. E-mail: sanjib_sinha2004@yahoo.co.in, sanjib_sinha@nimhans.kar.nic.in
doi:10.1111/j.1528-1167.2007.00921.x

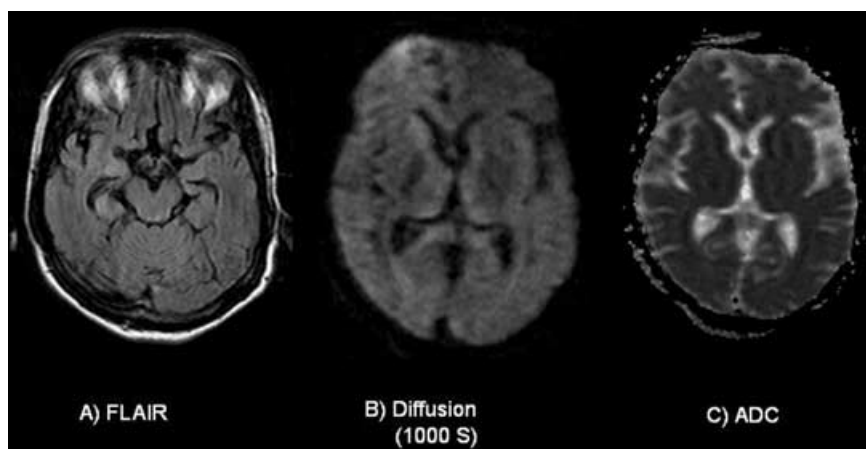


FIG. 1. A–C: MRI of patient 1—**A:** FLAIR, **B:** DWI, and **C:** ADC sequences showed mild diffuse cerebral atrophy and there was no signal change.

a decrease in the abundance of discharges. These paroxysmal discharges were mainly arising from right side and the periodicity was less frequent. After 3 months, he had resumed work, and was able to carry out basic designing. He was however not able to handle the financial matters. He scored 24/30 in MMSE. EEG showed only minimal slowing of BGA and no PLEDs. (Fig.2B)

Patient 2

A 33-yr-old lady was hospitalized for 2-year history of behavioral abnormalities, and frequent generalized tonic-clonic seizures, and unconcerned urinary incontinence of 3 month duration. Behavioral symptoms included disinhibition, nihilistic delusions and visual hallucinations, wan-

dering tendency and disorganized thought. She had geographic disorientation and impaired comprehension. She was not on anticonvulsants. Her husband had history of multiple extramarital affairs however, he was not available for evaluation. She scored 3/30 on Folstein's MMSE. There were focal neurological signs. Muscle stretch reflexes were normal and plantar response was flexor.

Hemogram and routine biochemical investigations were normal. Serum VDRL (1:2 Dilution) and TPHA tests were positive. CSF was acellular with minimal raised protein (51 mg/dL) and normal glucose (54 mg/dL). CSF VDRL was reactive in 1:2 dilutions. Antibody against herpes simplex virus was not detected. CT scan of brain showed gross cortical atrophy. MRI could not be carried out. Scalp EEG revealed slowing of BGA to theta range with PLEDs

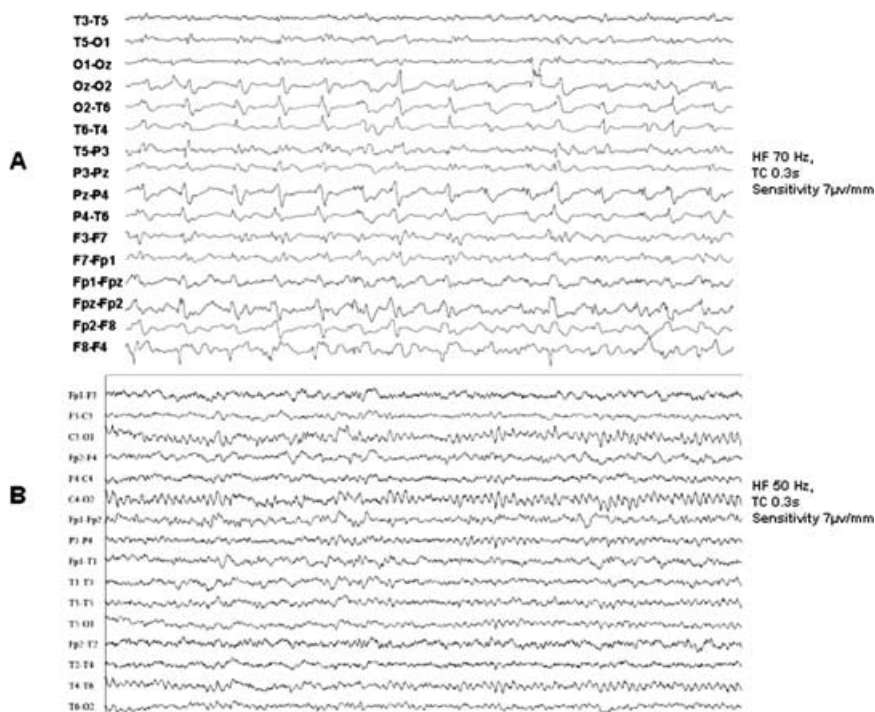


FIG. 2. A, B: EEG of 1st patient - **A:** Initial EEG showing mild diffuse slowing of background activity and PLED consisting of sharp waves/spikes and slow waves at 1 Hz over the right anterior temporo-frontal region. Lesser amplitude and abundant discharges on the left side are also seen **B:** Repeat EEG after 3 months showed only minimal slowing of BGA.

comprising of sharp waves occurring once in 2 s and arising from the left anterior temporal region. (Fig. 3A)

With intravenous lorazepam and phenytoin, there were no discernable clinical or EEG changes. She received intravenous crystalline penicillin (4 million units intravenously three times daily) for 2 weeks. At the time of discharge from hospital, there was partial improvement and a repeat EEG after 3 weeks was normal (Fig. 3B). She was lost to follow up.

DISCUSSION

PLEDs were first described in 1964 (Chatrian et al., 1964). These are characterized by the relative periodicity of lateralized epileptiform discharges at 0.5–3 s intervals. Pohlmann-Eden et al. (1996) considered PLEDs as an EEG signature of a dynamic pathophysiological state due to unstable neurobiological process creating an ictal-interictal continuum. The nature of the neuronal injury, preexisting propensity to have seizures, and the coexistence of dysmetabolic state might contribute to seizures. Ischemic stroke is the commonest cause of PLEDs and seizures occur in 50–85% of these patients (Baykan et al., 2000; Garcia-Morales et al., 2002). Their presence is helpful in the diagnosis of herpes simplex encephalitis in appropriate clinical settings. PLEDs arising from temporal region in a patient with subacute behavioral symptoms would suggest the possibility of Herpes simplex encephalitis, as in our patients.

Seizures are known to occur in meningovascular and general paresis forms of neurosyphilis (Merritt, 1955) and their frequency ranges from 14 to 60% (Primavera et al., 1998; Cisse et al., 2002). While intractable seizures have been described (Phan et al., 1999), generalized convulsive status epilepticus (SE), as a presenting manifestation of neurosyphilis is exceptional (Primavera et al., 1998; Ances et al., 2004). Kojan et al. (2000) have described a rare association of nonconvulsive SE and neurosyphilis. Neuroradiological findings in neurosyphilis vary with the stage of the disease and include ischemic lesions, pachymeningitis, gummata and cerebral atrophy.

Camacho-Salas et al. (2002) described a patient of neurosyphilis with PLEDs arising from the left fronto-temporal region. There was evidence of ischemia of the temporal lobe in the MRI, ipsilateral to the PLEDs. Radhakrishnan et al. (1984) reported a patient of meningovascular syphilis with left sided periodic generalized slow wave discharges and evidence of left parietal infarct on CT. Recently, Anghinah et al. (2006) have reported two patients with neurosyphilis and generalized periodic EEG activity. Both of our patients had generalized tonic-clonic seizures at presentation. CT scan in both the patients revealed diffuse cerebral atrophy. The second patient could not undergo MRI and therefore a possibility of underlying focal lesion could not be excluded. However, MRI in the first case did not demonstrate any focal structural abnormality or evidence of restricted diffusion. To the best of our knowledge there are no earlier studies de-

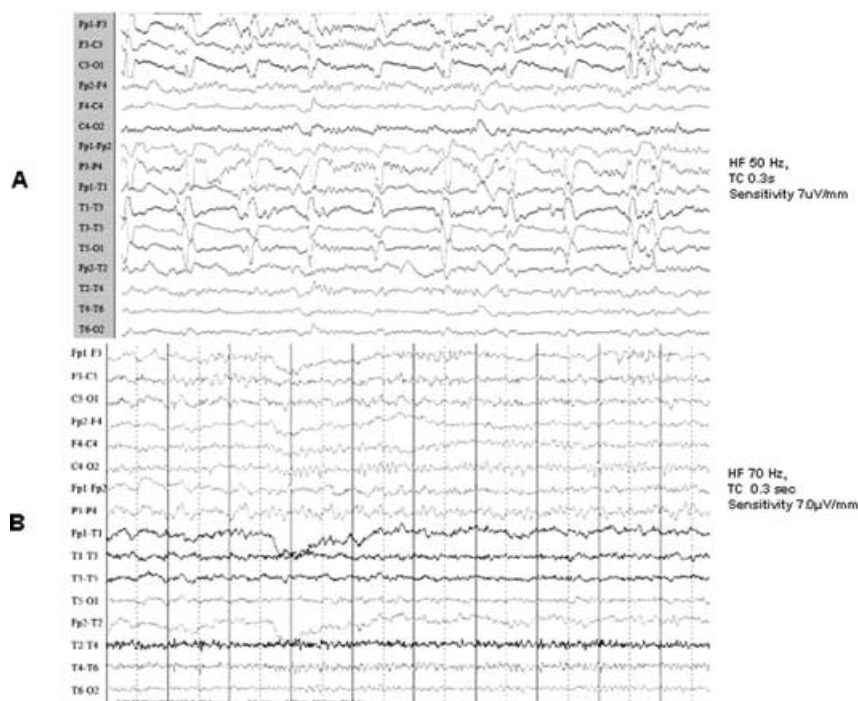


FIG. 3. A,B: EEG of 2nd patient : First EEG revealing mild background slowing to theta range and PLEDs comprising of sharp waves (once in 2 seconds) from left anterior temporal region. B: Repeat EEG after 3 weeks was normal.

scribing association of PLEDs without restricted diffusion on DWI. The mechanism of PLEDs in absence of ischemia or any other focal lesion remains unexplained, but might be a reflection of heightened neuronal excitability. The periodic discharges in our patients did not disappear with AEDs and therefore do not represent an ictal pattern. However, prolonged EEG monitoring was not carried out to document subclinical or subtle seizures. Both the patients improved in their behavior and cognition to a variable extent with recommended treatment for neurosyphilis and did not have further seizures.

Presence of PLEDs in EEG in a patient with behavioral and cognitive changes would usually suggest a possibility of Herpes simplex encephalitis, Creutzfeldt Jacob disease, Hashimoto's Encephalopathy, chronic hepatic encephalopathy among others. Neurosyphilis is a treatable condition and needs to be considered in patients presenting with subacute to chronic behavioral/cognitive disturbances with PLEDs or Generalized periodic discharges. The pathophysiology of PLEDs in the absence of focal structural changes and restricted diffusion needs further exploration.

REFERENCES

- Ances BM, Shellhaus R, Brown MJ, Rios OV, Herman ST, French JA. (2004) Neurosyphilis and status epilepticus: case report and literature review. *Epilepsy Research* 59:67–70.
- Anghinah R, Camargo EC, Braga NI, Waksman S, Nitrini R. (2006) Generalized periodic EEG activity in two cases of neurosyphilis. *Arquivos de Neuro-Psiquiatria* 64:122–124.
- Baykan B, Kinay D, Gokyigit A, Gurses C. (2000) Periodic lateralized epileptiform discharges: association with seizures. *Seizure* 9(6):402–406.
- Camacho-Salas A, Martiez-Salio A, Garcia-Morales I, Villarejo-Galende A, de la Pena P. (2002) Periodic lateralised epileptiform discharges as a form of presentation of neurosyphilis. *Revista de Neurologia* 35:734–737.
- Chatrian GE, Shaw CM, Leffman H. (1964) The significance of periodic lateralized epileptiform discharges in EEG: an electrographic, clinical and pathological study. *Electroencephalography and Clinical Neurophysiology* 17:177–93.
- Cisse A, Souare IS, Larkhis S, Cisse B, Beavogui K, Morel Y, Cisse M, Bah H, Cisse AF. (2002) Atypical neurosyphilis: 28 cases observed at the University Hospital Center of Conakry. *Médecine Tropicale (Mars)* 62:150–154.
- Garcia-Morales I, Garcia MT, Galan-Davila L, Gomez-Escalonilla C, Saiz-Diaz R, Martinez-Salio A, de la Pena P, Tejerina JA. (2002) *Journal of Clinical Neurophysiology* 19(2):172–177.
- Kojan S, Van Ness PC, Diaz-Arrastia R. (2000) Nonconvulsive status epilepticus resulting from Jarisch-Herxheimer reaction in a patient with neurosyphilis. *Clinical EEG (Electroencephalography)* 31:138–140.
- Merritt HH. (1955) Syphilis. In Merritt HH (Ed) *A Textbook of Neurology*. Lea & Febiger, Philadelphia, pp. 107.
- Phan TG, Somerville ER, Chen S. (1999) Intractable epilepsy as the initial manifestation of neurosyphilis. *Epilepsia* 40:1309–1311.
- Pohlmann-Eden B, Hoch DB, Cochius JL, Chiappa KH. (1996) Periodic lateralized epileptiform discharges—a critical review. *Journal of Clinical Neurophysiology* 13(6):519–530.
- Primavera A, Solaro C, Cocito L. (1998) De novo status epilepticus as the presenting sign of neurosyphilis. *Epilepsia* 39:1367–1369.
- Radhakrishnan K, Ashok PP, Sridharan R, El-Mangoush MA. (1984) Periodic EEG pattern in meningovascular syphilis. *Journal of Neurology, Neurosurgery, and Psychiatry* 47:1360–1361.