

PEDIATRICS®

OFFICIAL JOURNAL OF THE AMERICAN ACADEMY OF PEDIATRICS

Radiologic and Neurophysiologic Aspects of Stroke-like Episodes in Children With Congenital Disorder of Glycosylation Type Ia

Argirios Dinopoulos, Ismail Mohamed, Blaise Jones, Sanjai Rao, David Franz and
Ton deGrauw

Pediatrics 2007;119:e768; originally published online February 16, 2007;
DOI: 10.1542/peds.2006-0763

The online version of this article, along with updated information and services, is
located on the World Wide Web at:

<http://pediatrics.aappublications.org/content/119/3/e768.full.html>

PEDIATRICS is the official journal of the American Academy of Pediatrics. A monthly publication, it has been published continuously since 1948. PEDIATRICS is owned, published, and trademarked by the American Academy of Pediatrics, 141 Northwest Point Boulevard, Elk Grove Village, Illinois, 60007. Copyright © 2007 by the American Academy of Pediatrics. All rights reserved. Print ISSN: 0031-4005. Online ISSN: 1098-4275.

American Academy of Pediatrics

DEDICATED TO THE HEALTH OF ALL CHILDREN™



Radiologic and Neurophysiologic Aspects of Stroke-like Episodes in Children With Congenital Disorder of Glycosylation Type Ia

Argiros Dinopoulos, MD, PhD^a, Ismail Mohamed, MD^a, Blaise Jones, MD^b, Sanjai Rao, DO^a, David Franz, MD^a, Ton deGrauw, MD, PhD^a

Divisions of ^aNeurology and ^bRadiology, Cincinnati Children's Hospital Medical Center, Cincinnati, Ohio

The authors have indicated they have no financial relationships relevant to this article to disclose.

ABSTRACT

In an effort to shed light on the mechanism of hemiparetic stroke-like events experienced by patients with congenital disorder of glycosylation type Ia, we evaluated 3 children with this disorder by brain imaging studies and continuous electroencephalogram monitoring during such events. No evidence of ischemia or infarction was revealed on imaging studies and electrographic seizures or intermittent epileptiform activity was demonstrated on electrographic recordings. All 3 patients showed clinical and electrographic improvement after administration of antiepileptic medication. Epileptic phenomena can complicate the stroke-like events of patients with congenital disorder of glycosylation type Ia, and the cause of the hemiparesis may indeed be an active epileptic inhibitory process. As such, electroencephalogram monitoring is warranted, and treatment with anticonvulsant agents is indicated.

CONGENITAL DISORDERS OF glycosylation (CDG) comprise a group of inherited multisystem diseases characterized by defects in the glycosylation of glycoproteins. CDG type Ia (phosphomannomutase 2 deficiency) is, by far, the most frequently diagnosed N-glycosylation disease. It has a static clinical course that is characterized by mental retardation, hypotonia, cerebellar dysfunction, polyneuropathy, seizures, and stroke-like episodes of unknown origin. These episodes are known to occur in 40% to 55% of cases and are thought to be triggered by infection. They are associated with irritability, mental status changes, and hemiparesis and are sometimes accompanied by seizures. Their duration varies, with recovery ranging from days to weeks.^{1,2}

In an effort to shed light on the mechanism of these hemiparetic stroke-like events, we evaluated 3 patients with genetically confirmed CDG-Ia by continuous electroencephalogram (EEG) monitoring and brain imaging studies during such events. We report our findings here and propose a possible etiology.

CASE REPORTS

PATIENT 1. A 2½-year-old girl with CDG-Ia presented at the emergency department (ED) 36 hours after acute onset of left hemiparesis, irritability, and a diminished level of consciousness after a febrile illness. At presentation, unresponsiveness and upward eye-rolling were observed.

Treatment with intravenous lorazepam (0.2 mg/kg) was followed by respiratory suppression, which required intubation. Continuous bedside EEG monitoring during the hemiparesis revealed right parietal-occipital slowing with frequent intermittent spikes and 6 electrographic seizures arising from the right posterior quadrant. These seizures varied in duration, with the longest lasting up to 15 minutes (Fig 1). With the exception of hemiparesis, there were clinically no motor correlates to these seizures. Imaging studies (Table 1) performed during the hemiparetic event showed no evidence of ischemia or infarction. The patient was treated with intravenous fosphenytoin. Shortly after the initiation of treatment, her EEG showed resolution of electrographic seizures, and her mental status was steadily improved. Hemiparesis completely resolved 96 hours after the onset of symptoms and 24 hours after the administration of intrave-

Key Words: hemiparesis, stroke-like, epilepsy, congenital disorder of glycosylation, CDG

Abbreviations: CDG, congenital disorders of glycosylation; EEG, electroencephalogram; ED, emergency department; DWI, diffusion-weighted imaging
www.pediatrics.org/cgi/doi/10.1542/peds.2006-0763

doi:10.1542/peds.2006-0763

Accepted for publication Sep 18, 2006.

Address correspondence to Argiros Dinopoulos, MD, PhD, Cincinnati Children's Hospital Medical Center, Division of Neurology, 3333 Burnet Ave, MLC11006, Cincinnati, OH 45229. E-mail: argidino@yahoo.com

PEDIATRICS (ISSN Numbers: Print, 0031-4005; Online, 1098-4275). Copyright © 2007 by the American Academy of Pediatrics

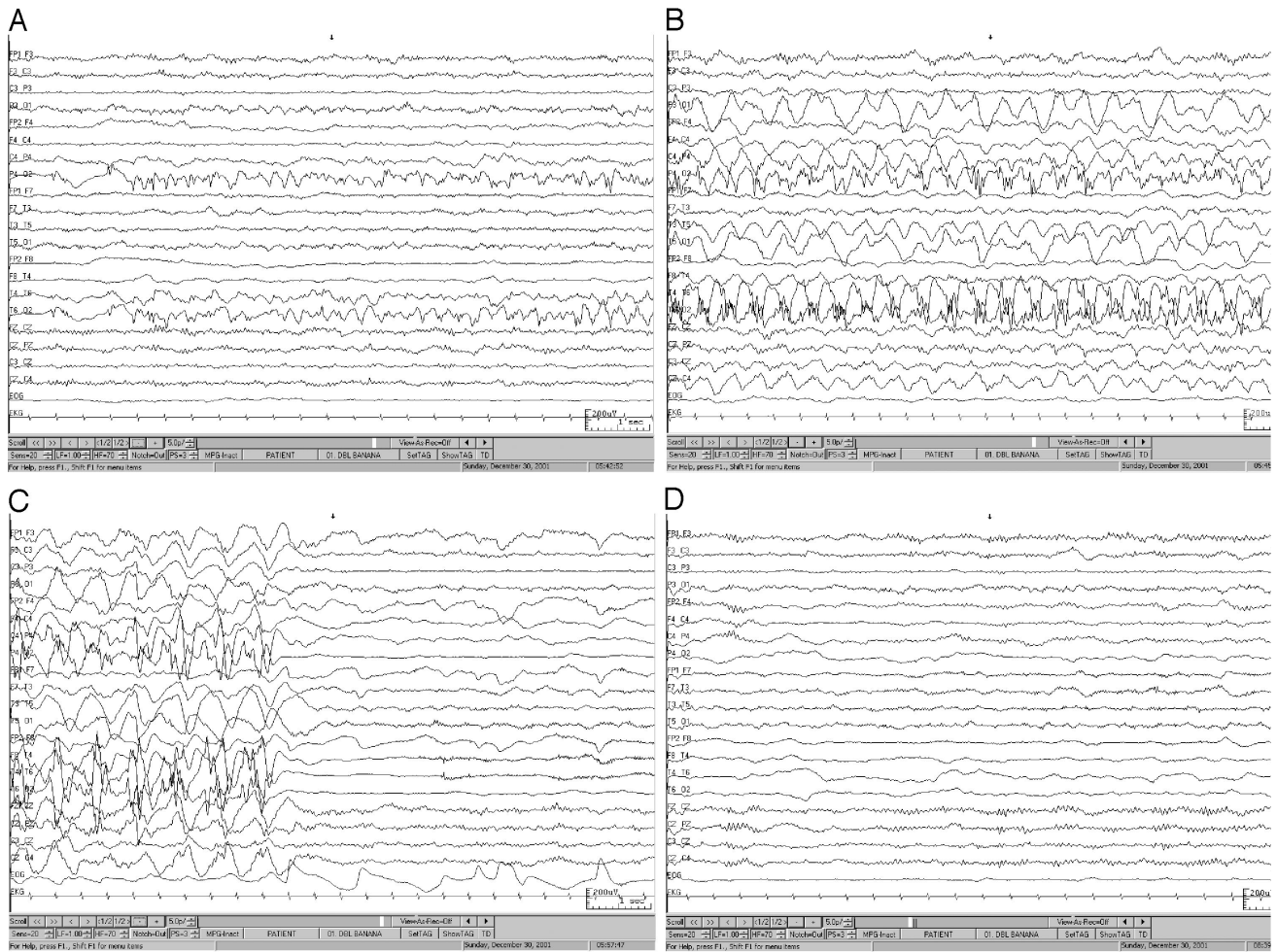


FIGURE 1

Patient 1: The tracings shown in A, B, and C (10-second epochs-bipolar montage) are segments of the EEG recording while the patient was hemiparetic. The tracing in A shows the beginning, in B shows the evolution, and in C shows the end of an electrographic seizure. The seizure arose from the right posterior quadrant (T6-O2), spread over the parietal-occipital head region (P4-O2), and lasted 15 minutes. The tracing in D (10-second epoch-bipolar montage) shows a segment of the recording 2½ hours afterward, while the patient was clinically improved and after administration (second dose) of intravenous fosphenytoin.

nous fosphenytoin. The patient was discharged on carbamazepine and has had no additional episodes over the subsequent 4 years.

PATIENT 2. An 11-year-old girl with CDG-Ia presented at the ED 8 hours after acute onset of left-side hemiparesis, irritability, and a diminished level of consciousness concurrent with a viral infection. She had had 3 previous episodes of stroke-like events (at 3, 6, and 9 years of age) that lasted up to 72 hours; because these events occurred in conjunction with seizures, they were described by previous clinicians as Todd's paralysis. After admission, continuous bedside EEG monitoring showed continuous focal right frontal slowing with intermixed runs of semi-rhythmic spikes and sharp waves that lasted up to 8 seconds (Fig 2). Imaging studies (Table 1) performed during the hemiparesis showed no evidence of ischemia or infarction. Treatment with intravenous lorazepam (0.1 mg/kg) resulted in disappearance of the rhythmic

spikes and sharp-wave activity (Fig 2) and complete resolution of the hemiparesis 12 hours later. The patient was discharged on oxcarbazepine and has had no additional hemiparetic episodes over the subsequent 3½ years.

PATIENT 3. A 14-year-old girl with CDG-Ia presented at the ED 48 hours after developing agitation, right-arm weakness, and fever. After becoming increasingly lethargic, she was admitted to the ICU. Bedside EEG monitoring showed continuous rhythmic high-amplitude bifrontal sharply contoured δ activity with higher amplitude on the left frontocentral region. Shortly after the administration of intravenous lorazepam (0.1 mg/kg), rhythmic frontal slowing disappeared and clinical improvement was observed (Fig 3). Hemiparesis resolved 2 hours after the administration of intravenous lorazepam and 72 hours after the onset of symptoms. Computer tomography of the head during the hemiparesis showed no acute

TABLE 1 Patient Data

Case No.	Mutations of <i>PMM2</i> Gene and Coagulation Deficiencies	Imaging Modalities and Timing in Relation to Onset of Hemiparesis	Continuous EEG Monitoring
1	Mutations: I120T/V231M; coagulation deficiencies: factor XI, antithrombin III, heparin cofactor II	HCT: 38 h after onset of hemiparesis; MRI ^a (sagittal T1, axial T2, and FLAIR, DWI, ADC, coronal FSE); ¹ HMRS: 50 h after onset of hemiparesis and while patient was hemiparetic	EEG recording (started 42 h after the onset of the hemiparesis); right parietal-occipital slowing with frequent intermittent spikes; 6 electrographic seizures arose from the right posterior quadrant; resolution of the electrographic seizures after treatment with intravenous fosphenytoin
2	Mutations: R141H/F119L; coagulation deficiencies: factor XI, antithrombin III, protein C, heparin cofactor II	HCT: 10 h after onset of hemiparesis; MRI ^a (sagittal T1, axial T2 and FLAIR, coronal FSE); ¹ HMRS: 28 h after onset of hemiparesis and while patient was hemiparetic	EEG recording (started 15 h after the onset of the hemiparesis); continuous focal right frontal slowing with intermittent semirhythmic runs of spikes and sharps waves lasting up to 8 sec; disappearance of the spike and sharp-wave discharges after 2 doses of intravenous lorazepam
3	Mutations: R141H/F119L; coagulation deficiencies: factor XI, antithrombin III, protein C and Sc	HCT: 48 h after onset of hemiparesis; MRI ^a (sagittal T1, axial T2 and FLAIR, DWI, ADC, coronal FSE); ¹ HMRS, MRA, and MRV: 120 h after onset of hemiparesis and 48 h after resolution	EEG recording (started 50 h after the onset of the hemiparesis); continuous rhythmic high-amplitude bifrontal sharply contoured δ activity with higher amplitude on the left frontocentral region; attenuation of the EEG pattern 7 min after intravenous lorazepam

PMM2 indicates phosphomannomutase 2; HCT, head computer tomography; FLAIR, fluid-attenuated inversion recovery; FSE, fast-spin echo; ADC, apparent diffusion coefficient; ¹HMRS, proton magnetic resonance spectroscopy; MRA, magnetic resonance angiography; MRV, magnetic resonance venography.

^a All MRI studies were performed on a 1.5-T magnetic resonance scanner (GE Medical Systems, Milwaukee, WI).

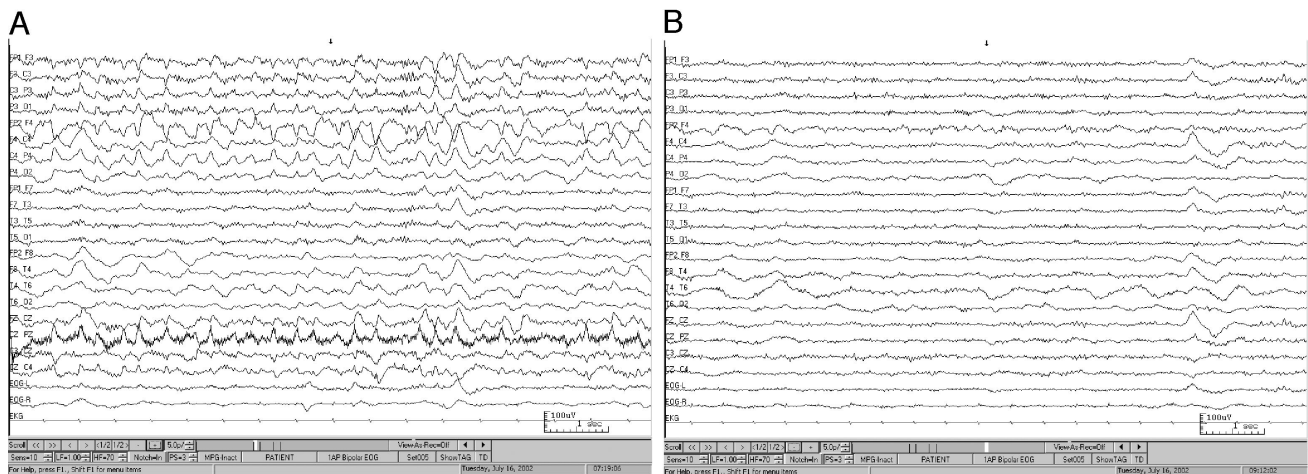


FIGURE 2

Patient 2: The tracings shown in A and B (10-second epochs-bipolar montage) are segments of the EEG recording during the stroke-like event. The tracing in A shows a segment of the ongoing semirhythmic slowing with intermixed-spikes activity over the right frontocentral head region (F4-C4). The tracing in B shows a sample of the recording 2 hours afterward, while the patient was clinically improved and after treatment with intravenous lorazepam.

changes, and both MRI and magnetic resonance angiography performed after the resolution of the hemiparesis showed no evidence of ischemia. The patient was discharged on topiramate and has had no additional hemiparetic episodes over the subsequent 2½ years.

DISCUSSION

Here we report the electrographic and imaging findings of 3 patients with CDG-Ia during a hemiparetic stroke-like event. Signs of neuronal hyperexcitability were demonstrated on the electrographic recordings of all 3

patients, with no evidence of ischemia revealed by the imaging studies. To our knowledge, ours is the first study to document electrographic and imaging findings during hemiparetic stroke-like events.

Several studies have described the neurologic manifestations of CDG-Ia¹⁻³; however, because detailed evaluation during hemiparetic stroke-like episodes is lacking, the pathophysiology and specific mechanism of these episodes remain unknown. Ischemia has been proposed as a possible etiology of these stroke-like events, because both procoagulant (factor XI) and anticoagulant

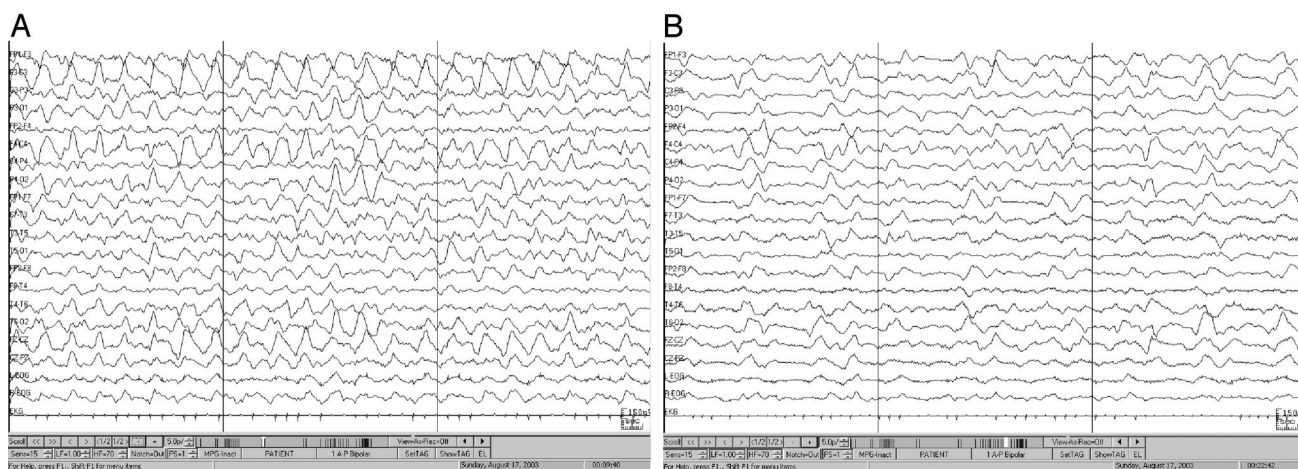


FIGURE 3
 Patient 3: The tracing shown in A (30-second epoch-bipolar montage) is a segment of the EEG recording during the hemiparetic stroke-like event and shows continuous rhythmic high-voltage slow waves (~1 Hz) over the frontal head region bilaterally, but it is better seen on the left (F3-C3). The tracing in B (30-second epoch-bipolar montage) is a segment of the EEG.

(protein C, antithrombin III, and protein V) proteins are reported to be deficient in most patients with CDG-Ia.^{4,5} Other factors that support ischemia as the cause of the events include platelet hyperaggregability and transient decrease of endogenous anticoagulants during catabolic stress.⁶ Nevertheless, there has been no report that provided clear neuroradiologic or pathologic evidence of ischemic stroke, and there have been very few reports of other thrombotic accidents in patients with CDG-Ia.^{7,8} The above-described coagulation deficiencies were also observed in all 3 of our patients (Table 1); however, no evidence suggestive of ischemia was seen in the neuroimaging studies performed during the hemiparetic events. Moreover, for 2 patients, no restricted diffusion was observed on diffusion-weighted imaging (DWI) or apparent diffusion coefficient maps. Signal-intensity changes can be detected within minutes of arterial occlusion with DWI, and increased signal intensity detected with T2-weighted sequences is usually observed after 8 hours.⁹ Regardless of the fact that MRI modalities have been shown to miss transient ischemic events, DWI and apparent diffusion coefficient mapping, in particular, usually detect events associated with prolonged duration and disturbances of higher brain function.¹⁰ If the prolonged hemiparesis (lasting >48 hours) in our cases was caused by a cortical ischemic infarction, this infarction would have likely been detected on standard MRI. The cytotoxic edema caused by the infarction would be even more likely to exhibit a restricted diffusion on DWI.

Epileptic seizures are not uncommon in patients with CDG-Ia and often are observed in association with stroke-like events. A transient focal neurologic deficit known as postictal paralysis (Todd's paralysis) can follow a convulsive motor seizure. Our data are insufficient to prove that the paralysis in our patients was ictal; however, the phenomenon cannot be considered a simple

Todd's paralysis, because the hemiparesis persisted beyond 24 hours, ictal discharges were present on EEG, and clinical motor seizures were absent before hemiparesis.¹¹ The EEG recording during the hemiparesis showed clear electrographic seizures in patient 1. No electrographic seizures were captured for patients 2 and 3. However, EEG recording showed a continuous semi-rhythmic slowing with intermittent runs of spikes and sharp-waves activity in patient 2 (Fig 2) and a continuous sharply contoured rhythmic δ activity in patient 3 (Fig 3). Both patterns resolved after the administration of lorazepam. Continuous rhythmic sharp waves and frequent rhythmic spikes and sharp waves are commonly seen in comatose patients but also can be seen in patients with nonconvulsive status epilepticus.¹² The significance of such patterns is unclear and reflects the difficulty of differentiating ongoing epileptic discharges from abnormalities caused by diffuse metabolic neuronal dysfunction. The rapid electrographic response and, more importantly, the clinical response observed after treatment with antiepileptic drugs favor an epileptic etiology in our patients.

During the events, electrographic seizures in patient 1 and epileptiform discharges in patients 2 and 3 lateralized with the hemiparesis and, specifically for patients 2 and 3, the maximal activity was observed on the premotor cortex. Inhibitory motor seizures with ictal hemiparesis of variable duration, and even inhibitory motor status epilepticus with hemiparesis lasting from 14 hours to 6 weeks, have been described in the literature.¹³⁻¹⁵ Penfield and Jasper¹⁶ and, more recently, Luders et al¹⁷ have reported a negative motor response elicited by stimulation of the human premotor cortex. Despite the inherent limitations of EEG surface recordings, we postulate that the clinical hemiparesis was the result of

subclinical electrographic seizures that actively inhibited motor function.

The pathogenesis of the observed neuronal hyperexcitability in patients with CDG-Ia is unclear, but it is presumably related to a deficient glycosylation at the neuronal level.¹⁸ Transient disease-related noncytotoxic edema is also a possibility; Pearl and Krasnewich² described a patient with CDG-Ia who demonstrated neuroradiologic evidence of transient edema during a stroke-like event. Transient cortical hypoperfusion, induced by the coagulation defects, that was severe enough to cause neuronal dysfunction but mild enough to be undetected by the MRI modalities cannot, however, be excluded. Focal neuronal hyperexcitability has been documented also in patients with mitochondrial encephalopathy lactic acidosis and stroke syndrome and has been proposed as the triggering mechanism of stroke-like events.¹⁹

CONCLUSIONS

On the basis of our clinical observations, EEG recordings, and neuroimaging findings, the diffuse and focal neuronal dysfunction that is evident during stroke-like events in patients with CDG-Ia cannot be explained solely by ischemia. Clinical and subclinical seizure activity may complicate the stroke-like events, and the cause of the hemiparesis may indeed be an active epileptic inhibitory process. As such, EEG or, ideally, video-EEG monitoring is warranted, and treatment with anticonvulsant agents is indicated.

ACKNOWLEDGMENTS

We thank Dr G. Matthijs from the Center for Human Genetics in Leuven, Belgium, for the mutation screening in the *PMM2* gene; Dr M. Privitera for thoughtful comments; and A. P. Cohen, medical writer, for assistance in writing this manuscript.

REFERENCES

1. Drouin-Garraud V, Belgrand M, Grunewald S, et al. Neurological presentation of a congenital disorder of glycosylation CDG-Ia: implications for diagnosis and genetic counseling. *Am J Med Genet.* 2001;101:46–49

2. Pearl PL, Krasnewich D. Neurologic course of congenital disorders of glycosylation. *J Child Neurol.* 2001;16:409–413
3. Miossec-Chauvet E, Mikaeloff Y, Heron D, et al. Neurological presentation in pediatric patients with CDG type Ia. *Neuropediatrics.* 2003;34:1–6
4. Young G, Driscoll M. Coagulation abnormalities in the carbohydrate-deficient glycoprotein syndrome: case report and review of the literature. *Am J Hematol.* 1999;60:66–69
5. Fiumara A, Barone R, Buttitta P, et al. Haemostatic studies in carbohydrate-deficient glycoprotein syndrome type I. *Thromb Haemost.* 1996;76:502–504
6. Van Geet C, Jaeken J, Freson K, et al. Congenital disorders of glycosylation type Ia and IIa are associated with different primary haemostatic complications. *J Inherit Metab Dis.* 2001;24:477–492
7. Funk M, Becker S, Potzsch B, Kreuz W, Bohles H. Thrombophilia in a child with CDG-syndrome type I. *Thromb Haemost.* 1995;74:1199–1200
8. Huemer M, Huber W, Shima W, et al. Budd-Chiari syndrome associated with coagulation abnormalities in a child with carbohydrate deficient glycoprotein syndrome type Ix. *J Pediatr.* 2000;136:691–695
9. Yuh WTC, Crain MR, Loes DJ, et al. MR imaging of cerebral ischemia: findings in the first 24 hours. *AJNR Am J Neuroradiol.* 1991;12:621–629
10. Inatomi Y, Kimura K, Yonehara T, Fujioka S, Uchino M. DWI abnormalities and clinical characteristics in TIA patients. *Neurology.* 2004;62:376–380
11. Gallmeizer P, Leatmezer F, Serles W, Assem-Hilder E, Spatt J, Bawmgartner C. Postictal paresis in focal epilepsies: incidence, duration and causes. *Neurology.* 2004;62:2160–2164
12. Walker M, Cross H, Smith S, et al. Nonconvulsive status epilepticus: Epilepsy Research Foundation Workshop Reports. *Epileptic Disord.* 2005;7:253–296
13. Dale RC, Cross JH. Ictal hemiparesis. *Dev Med Child Neurol.* 1999;41:344–347
14. Thomas P, Giraud K, Alchaar H, Chatel M. Ictal asomatognosia with hemiparesis. *Neurology.* 1998;51:280–282
15. Smith R, Devinsky O, Luciano D. Inhibitory motor status: two new cases and a review of inhibitory motor seizures. *J Epilepsy.* 1997;10:15–21
16. Penfield WG, Jasper HH. *Epilepsy and Functional Anatomy of the Human Brain.* Boston, MA: Little Brown; 1954
17. Luders HO, Lesser RP, Dinner DS, et al. A negative motor response elicited by electrical stimulation of the human frontal cortex. *Adv Neurol.* 1992;57:149–157
18. Marx J. A new link in the brain's defenses. *Science.* 1992;256:1278–1280
19. Iizuka T, Sakai F. Pathogenesis of stroke-like episodes in MELAS: analysis of neurovascular cellular mechanisms. *Curr Neurovasc Res.* 2005;2:29–45

Radiologic and Neurophysiologic Aspects of Stroke-like Episodes in Children With Congenital Disorder of Glycosylation Type Ia

Argiros Dinopoulos, Ismail Mohamed, Blaise Jones, Sanjai Rao, David Franz and Ton deGrauw

Pediatrics 2007;119:e768; originally published online February 16, 2007;
DOI: 10.1542/peds.2006-0763

Updated Information & Services	including high resolution figures, can be found at: http://pediatrics.aappublications.org/content/119/3/e768.full.html
References	This article cites 18 articles, 6 of which can be accessed free at: http://pediatrics.aappublications.org/content/119/3/e768.full.html#ref-list-1
Subspecialty Collections	This article, along with others on similar topics, appears in the following collection(s): Neurology http://pediatrics.aappublications.org/cgi/collection/neurology_sub Radiology http://pediatrics.aappublications.org/cgi/collection/radiology_sub
Permissions & Licensing	Information about reproducing this article in parts (figures, tables) or in its entirety can be found online at: http://pediatrics.aappublications.org/site/misc/Permissions.xhtml
Reprints	Information about ordering reprints can be found online: http://pediatrics.aappublications.org/site/misc/reprints.xhtml

PEDIATRICS is the official journal of the American Academy of Pediatrics. A monthly publication, it has been published continuously since 1948. PEDIATRICS is owned, published, and trademarked by the American Academy of Pediatrics, 141 Northwest Point Boulevard, Elk Grove Village, Illinois, 60007. Copyright © 2007 by the American Academy of Pediatrics. All rights reserved. Print ISSN: 0031-4005. Online ISSN: 1098-4275.

American Academy of Pediatrics

DEDICATED TO THE HEALTH OF ALL CHILDREN™

