

Vascular

Temporary neurologic deterioration due to cerebral hyperperfusion after superficial temporal artery-middle cerebral artery anastomosis in patients with adult-onset moyamoya disease

Miki Fujimura, MD^{a,*}, Tomohiro Kaneta, MD^b, Shunji Mugikura, MD^b, Hiroaki Shimizu, MD^c, Teiji Tominaga, MD^a

Departments of ^aNeurosurgery and ^bRadiology, Tohoku University School of Medicine, Sendai 980-8574, Japan

^cDepartment of Neurosurgery, Kohnan Hospital, Sendai, Japan

Received 10 April 2006; accepted 3 July 2006

Abstract

Background: Surgical revascularization for moyamoya disease prevents cerebral ischemic attacks by improving CBF, but little is known about the change in CBF and its effect on neurologic status during the acute stage after revascularization.

Methods: ¹²³I-IMP-SPECT was performed 1 and 7 days after STA-MCA anastomosis on 34 sides of 27 consecutive patients with adult-onset moyamoya disease (6 men, 21 women; 22–62 years old). The follow-up period ranged from 5 to 28 months (mean, 17.6 months).

Results: Thirteen patients (13 sides, 38.2%) suffered temporary neurologic deterioration due to hyperperfusion several days after surgery, which was sustained for several days (7.4 days in average). Postoperative magnetic resonance imaging/angiography showed the STA as a higher intensity signal than the preoperative finding without ischemic changes in all 13 patients. Postoperative SPECT revealed focal intense increase in CBF at the sites of anastomosis in all 13 patients. Eleven patients (32.4%) had transient focal neurologic deficit mimicking ischemic attack. Two patients (5.9%) had cerebral hyperperfusion syndrome associated with subarachnoid hemorrhage extending to the ipsilateral sylvian cistern. Symptoms were relieved by intensive blood pressure control, and no patients had permanent neurologic deficit or delayed neurologic deterioration during the follow-up period.

Conclusions: Surgical revascularization including STA-MCA anastomosis is a safe and effective treatment for moyamoya disease, although temporary neurologic deterioration due to hyperperfusion could occur at a substantial rate. Routine CBF measurement is recommended for accurate diagnosis of postoperative hyperperfusion in moyamoya disease because its treatment is contradictory to that for ischemia.

© 2007 Elsevier Inc. All rights reserved.

Keywords: Cerebral blood flow; Cerebral hyperperfusion; Moyamoya disease; Superficial temporal artery-middle cerebral artery anastomosis; Hyperperfusion; Single-photon emission computed tomography

Abbreviations: CBF, cerebral blood flow; CT, computed tomography; 3DSRT, 3-dimensional stereotactic region of interest template; DTA, deep temporal artery; DWI, diffusion-weighted imaging; EDMS, encephaloduro-myosynangiosis; FLAIR, fluid-attenuated inversion recovery; ¹²³I-IMP-SPECT, *N*-isopropyl-*p*-[¹²³I]iodoamphetamine single-photon emission computed tomography; MRI, magnetic resonance imaging; MRA, magnetic resonance angiography; PWI, perfusion-weighted imaging; ROS, reactive oxygen species; STA-MCA anastomosis, superficial temporal artery-middle cerebral artery anastomosis.

* Corresponding author. Tel.: +81 22 717 7230; fax: +81 22 717 7233.

E-mail address: fujimur@nsg.med.tohoku.ac.jp (M. Fujimura).

0090-3019/\$ – see front matter © 2007 Elsevier Inc. All rights reserved.

doi:10.1016/j.surneu.2006.07.017

1. Introduction

Moyamoya disease is a chronic, occlusive cerebrovascular disease with unknown etiology characterized by bilateral steno-occlusive changes at the terminal portion of the internal carotid artery and an abnormal vascular network at the base of the brain [20]. Surgical revascularization for moyamoya disease is believed to be beneficial to prevent cerebral ischemic attacks by improving CBF, and STA-MCA anastomosis with or without indirect bypass is generally used as

the standard surgical treatment of moyamoya disease [3,6,7,9,17]. However, little is known about the change in CBF and its effect on neurologic status during the acute stage after direct bypass for moyamoya disease [3,4,13].

Cerebrovascular reconstruction surgery including carotid endarterectomy or extracranial-intracranial bypass in patients with atherosclerotic cerebral steno-occlusive diseases can cause a rapid increase in CBF in the chronic ischemic brain, resulting in complications such as cerebral hyperperfusion syndrome. Cerebral hyperperfusion syndrome is characterized by unilateral headache, facial and ocular pain, seizures, and focal symptoms that occur secondary to cerebral edema or intracerebral hemorrhage [15,18,19]. Patients with poorer cerebrovascular reactivity are known to have potentially higher risk for hyperperfusion syndrome [10,11,23]. It was reported that STA-MCA anastomosis as a treatment for moyamoya disease could result in transient neurologic deterioration due to an unknown mechanism [5,21]. However, it remains undetermined whether STA-MCA anastomosis for moyamoya disease, which usually provides low-flow revascularization due to the anatomy of their recipient arteries, can result in neurologic deterioration due to hyperperfusion postoperatively. To address this issue, we prospectively performed ^{123}I -IMP-SPECT 1 and 7 days after STA-MCA anastomosis on 34 sides of 27 consecutive patients with adult-onset moyamoya disease treated in our institute. Comprehensive evaluation of postoperative CBF and its comparison with neurologic status in patients with adult-onset moyamoya disease allowed us to reveal the possible contribution of focal intense increase in CBF to the transient focal neurologic deterioration after STA-MCA anastomosis.

2. Patients and methods

The correlation between postoperative changes in CBF and clinical course was investigated in 27 consecutive patients (6 men, 21 women; 22–62 years old) with adult-

onset moyamoya disease on 34 sides, treated by the same surgeon (M.F.) in Tohoku University Hospital from March 2004 to February 2006. All patients were strictly followed up in our institute with a mean follow-up period of 17.6 months. All patients satisfied the criteria of the Research Committee on Spontaneous Occlusion of the Circle of Willis, of the Ministry of Health, Labor, and Welfare, Japan, except for 3 patients with “probable moyamoya disease” with unilateral involvement. All patients underwent STA-MCA anastomosis with or without EDMS and dural pedicle insertion [17,22]. The CBF was routinely measured by ^{123}I -IMP-SPECT 1 and 7 days after surgery in all patients. The CBF was quantified by the autoradiographic method, and the CBF in each subregion of the cerebral cortex was automatically calculated by 3DSRT software (version 2) provided by Daiichi Radio-Isotope (Tokyo, Japan). The 1.5-T MRI and MRA were routinely performed 2 and 8 days after surgery. MRI includes DWI, FLAIR, T1-/T2-weighted images, and T2*-weighted images.

3. Results

Among the 27 consecutive patients with 34 surgeries, no patients had perioperative cerebral infarction, and in all patients who had transient ischemic attack, the ischemic attack disappeared or improved during the follow-up period. One hemorrhagic-onset patient had cerebral hemorrhage on the contralateral side 3 months after surgery, which did not affect his neurologic status. The patency of STA-MCA bypass was confirmed in all 27 patients with 34 surgeries by MRA during the follow-up period. Thirteen patients (13 sides, 38.2%) had temporary neurologic deterioration due to hyperperfusion from 2 to 7 days after surgery, which was sustained for several days (Table 1). Postoperative MRI/MRA showed no ischemic changes, and the thick, high signal of STA-MCA anastomosis was evident in all 13 patients. Postoperative SPECT revealed focal intense increase in CBF at the sites of anastomosis in all 13 patients.

Table 1
Summary of 13 patients with temporary neurologic deterioration due to hyperperfusion

Case No.	Age/sex	Type of onset	Side of operation	Symptoms	Period of deficit	Hyperperfusion by SPECT
1	55/F	Hemorrhage	Right	Dysarthria, SensD, SZ	POD 7-20	POD 6
2	38/F	Infarction	Left	Aphasia	POD 2-6	POD 1, 5, 7
3	36/F	TIA, seizure	Left	Aphasia, SensD	POD 2-10	POD 1, ^a 7
4	37/M	Infarction	Right ^b	Aphasia, SensD	POD 3-30	POD 2, 7
5	36/F	Infarction	Right	HA, SAH	POD 2	POD 1
6	26/F	TIA	Right	Dysarthria, SensD, FP	POD 3-13	POD 1, 7
7	62/M	Hemorrhage	Right	Dysarthria, FP	POD 9	POD 1, 7
8	42/F	TIA	Right	HA, SAH	POD 2-4	POD 1, 7
9	47/F	TIA	Right ^b	Aphasia, SensD	POD 2-11	POD 1, 7
10	40/F	TIA	Right	Dysarthria, SZ	POD 5-10	POD 1, 7
11	36/M	TIA	Left	Aphasia	POD 5-16	POD 1, 7
12	29/F	Infarction	Right	Dysarthria, SensD	POD 3-6	POD 2, 7
13	36/M	TIA	Left	Aphasia, SensD	POD 3-6	POD 1, 7

M indicates male; F, female; POD, postoperative day; TIA, transient ischemic attack; HA, headache; SAH, subarachnoid hemorrhage; FP, facial palsy; SensD, sensory disturbance (numbness) at upper limb and/or face on the contralateral side; SZ, seizure.

^a Slight increase at the site of the anastomosis.

^b Language dominance in the right hemisphere as shown by functional MRI or by Edinburgh test.

Eleven patients (11 sides, 32.4%) had transient focal neurologic deficit due to hyperperfusion that mimicked ischemic attack, which started from 2 to 9 days after surgery and was sustained for several days (7.4 days, on average). The anatomical location and the temporal profile of hyperperfusion were completely in accordance with the transient neurologic deficits in these 11 patients (Table 1). Two patients (2 sides, 5.9%) complained of severe headache and had cerebral hyperperfusion syndrome associated with subarachnoid hemorrhage extending to the ipsilateral sylvian cistern. Symptoms were relieved by intensive blood pressure control with the use of the free radical scavenger, edaravone (Mitsubishi Pharma Co, Tokyo, Japan), and no patients had permanent neurologic deficit or delayed neurologic deterioration during the follow-up period.

4. Representative cases

4.1. Case 1

A 55-year-old woman presented with left hemiparesis due to right putaminal hemorrhage in October 2002 and was admitted to another hospital where she was treated conservatively. The diagnosis was stage III moyamoya disease according to the criteria of the Research Committee on Spontaneous Occlusion of the Circle of Willis of the Ministry of Health, Labor, and Welfare, Japan. She was discharged without neurologic deficit and was introduced to our service in December 2003.

She was admitted to our hospital to undergo bypass surgery for moyamoya disease in July 2004. SPECT showed her bilateral CBF and cerebrovascular reserve capacities

were markedly affected, so bilateral bypass surgery was planned. The first-stage surgery on the right side was performed in July 2004. After exploration of the frontal branch of the right STA, frontotemporoparietal craniotomy was performed. The recipient artery at the M4 segment of the anterior parietal branch of the MCA was explored and anastomosis was performed between the stump of the STA (1.0 mm in diameter) and the M4 segment (0.8 mm in diameter) that supplied the parietal lobe. Then, EDMS and dural pedicle insertion were performed. The patient showed no neurologic deficit immediately after surgery.

^{123}I -IMP-SPECT 1 day after surgery showed no apparent change in CBF on the right side (Fig. 1B) compared with the preoperative findings (Fig. 3A), but focal intense increase in CBF at the site of anastomosis was evident 6 days after surgery (Fig. 1C, arrows). Postoperative MRA showed the apparently patent STA-MCA bypass as a higher intensity signal than the opposite side STA (Fig. 2A and B, arrows), and diffusion-weighted MRI showed no evidence of ischemic change (Fig. 2C). She had dysarthria, numbness in the left upper limb, and emotional incontinence 7 days after surgery. She had a simple partial seizure on her left limbs 10 days after surgery. Intensive blood pressure control and the use of free radical scavenger relieved her symptoms that completely disappeared 20 days after surgery, when focal intense increase in CBF disappeared as shown by SPECT (Fig. 1D). She was discharged without neurologic deficit on August 22, 2004. Three months later, STA-MCA anastomosis with EDMS was performed on the left side, and she was discharged without neurologic deficit after an uneventful postoperative course. Postoperative external carotid angiography 3 months after the second surgery showed that the

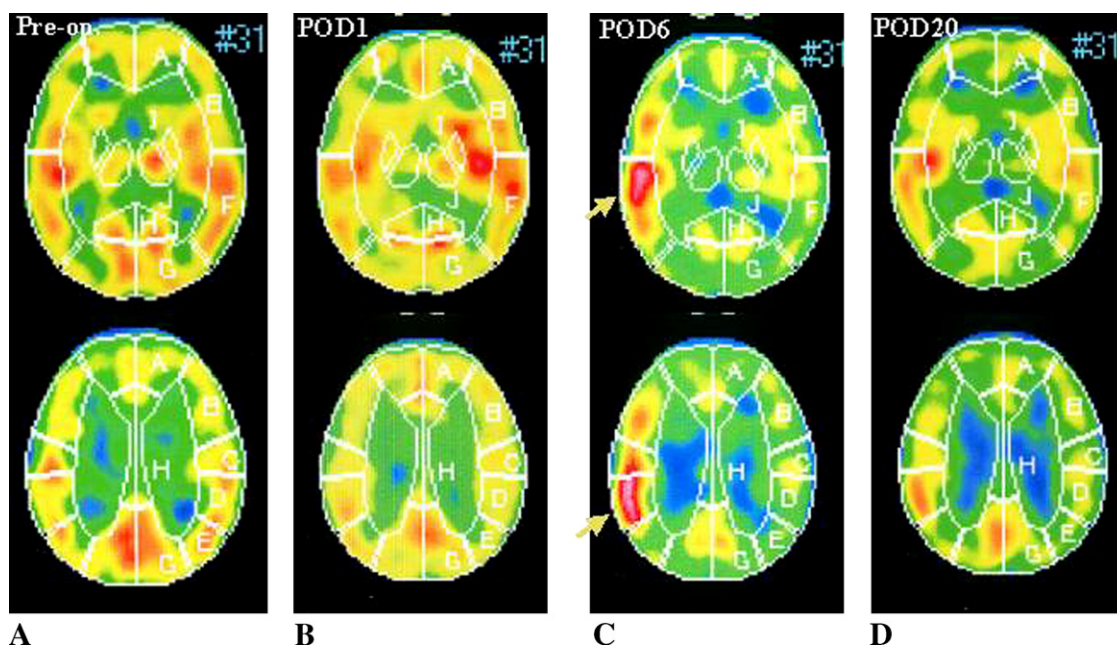


Fig. 1. Case 1. ^{123}I -IMP-SPECT scans before surgery (A) and 1 (B), 6 (C), and 20 days (D) after surgery. The focal intense increase in CBF at the site of anastomosis (arrows in C) was evident as early as 6 days after surgery and preceded the manifestation of dysarthria and sensory disturbance on the left hand 7 days after surgery.

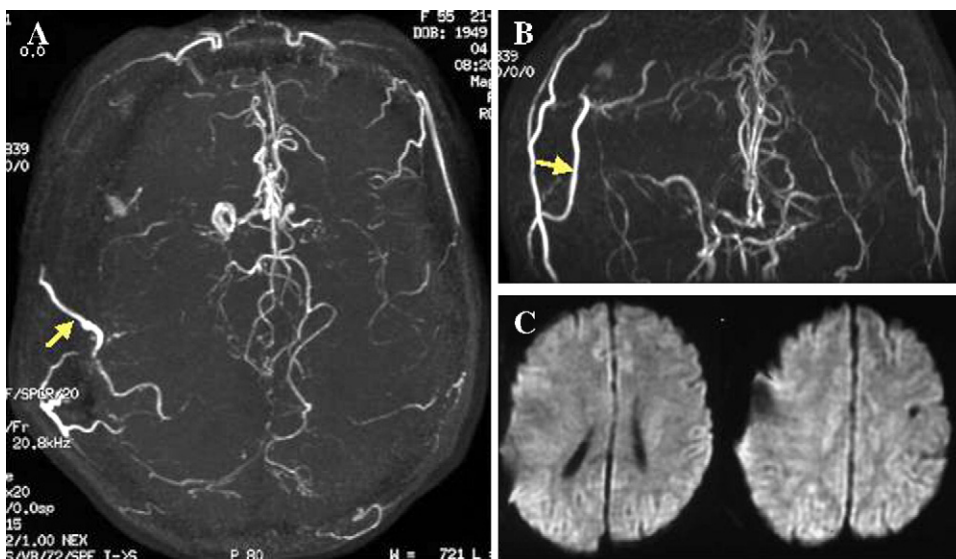


Fig. 2. Case 1. Postoperative MRA showing the apparently patent STA-MCA bypass as a higher intensity signal than the opposite side STA (arrows in A and B). C: Diffusion-weighted MR images 2 days after surgery, showing no evidence of ischemic change.

bilateral MCA territories were supplied by the thick STA-MCA bypass (data not shown). She did not experience neurologic deterioration during the follow-up period.

4.2. Case 2

A 38-year-old woman was admitted to our hospital for second-stage bypass surgery for moyamoya disease in April 2004. She experienced repeated numbness in the left upper extremity after hyperventilation for the previous 18 years. She had sudden onset of left hemiparesis due to cerebral infarction at the posterior limb of the right internal capsule in November 2003 and was admitted to another hospital. She was treated conservatively and was discharged without

neurologic deficit. However, she had repeated transient ischemic attacks of the left upper limb and was introduced to our service.

Cerebral angiography delineated steno-occlusive changes at the terminal portions of the bilateral internal carotid arteries, and abnormal networklike vessels were apparent at the bilateral basal ganglia. The diagnosis was stage III moyamoya disease according to the criteria of the Research Committee on Spontaneous Occlusion of the Circle of Willis of the Ministry of Health, Labor, and Welfare, Japan. STA-MCA anastomosis with EDMS and dural pedicle insertion was performed on the right side in December 2003. The postoperative course was uneventful and she was

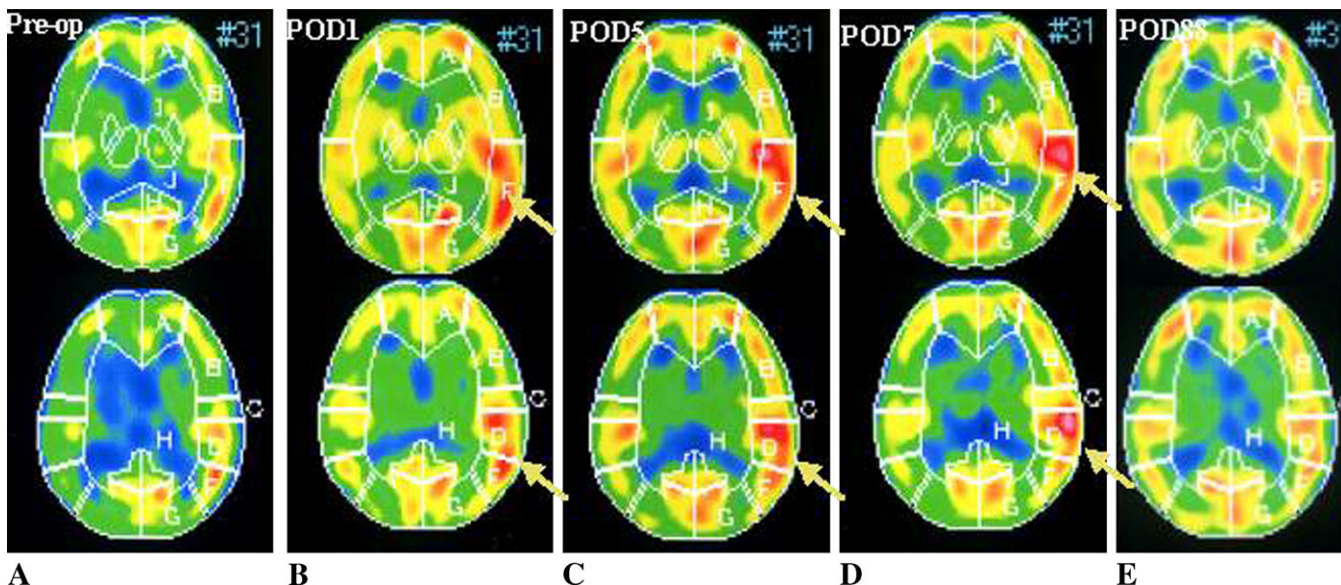


Fig. 3. Case 2. ¹²³I-IMP-SPECT scans before surgery (A) and 1 (B), 5 (C), 7 (D), and 88 days (E) after surgery. The transient focal intense increase in CBF at the site of anastomosis (arrows in B-D) was evident as early as 1 day after surgery and preceded the manifestation of motor aphasia on postoperative day 2.

discharged without neurologic deficit in January 2004. Because her CBF and cerebrovascular reserve capacity were markedly affected on both sides (data not shown), second-stage surgery was carried out on the left side in April 2004. After exploration of the frontal branch of the left STA, frontotemporoparietal craniotomy was performed. The recipient artery at the M4 segment of the MCA was then explored and anastomosis was performed between the stump of the STA (1.0 mm in diameter) and the proximal portion of the M4 segment (1.2 mm in diameter) that supplied the temporal lobe. Then, EDMS and dural pedicle insertion were performed. She showed no neurologic deficit immediately after surgery.

^{123}I -IMP-SPECT 1 day after surgery showed focal intense increase in CBF at the site of anastomosis (Fig. 3B, arrows) compared with the preoperative findings (Fig. 3A). Postoperative diffusion-weighted MRI showed no evidence of ischemic change, and MRA showed the apparently patent STA-MCA bypass as a higher intensity signal than the preoperative finding. She developed fluctuating aphasia on the next day (postoperative day 2), which persisted until postoperative day 6. The focal intense increase in CBF persisted until postoperative day 7 (Fig. 3C and D, arrows), but she recovered from the aphasia and was discharged without neurologic deficit. Focal intense increase in CBF was not evident by SPECT 88 days after surgery (Fig. 3E). She did not experience neurologic deterioration during the follow-up period.

4.3. Case 3

A 36-year-old woman presented with transient left hemiparesis and subsequent generalized convulsion in

December 2003 and was introduced to our service. Stage III moyamoya disease was identified. She had had transient ischemic attacks in the bilateral upper extremities. SPECT showed her bilateral CBF and cerebrovascular reserve capacities were markedly affected. Therefore, bilateral bypass surgery was planned. STA-MCA anastomosis with EDMS was performed on the right side in March 2004, and she was discharged without neurologic deficit after an uneventful postoperative course.

Second-stage surgery on the left side was performed in August 2004. After exploration of the parietal branch of the left STA, frontotemporoparietal craniotomy was performed. The recipient artery at the M4 segment of the anterior parietal branch of the MCA was explored and anastomosis was performed between the stump of the STA (1.2 mm in diameter) and the M4 segment (1.0 mm in diameter) that supplied the temporal lobe. Then EDMS and dural pedicle insertion were performed. The patient showed no neurologic deficit immediately after surgery.

^{123}I -IMP-SPECT 1 day after surgery showed a slight increase in CBF in the left hemisphere (Fig. 4B, arrow) compared with the preoperative findings (Fig. 4A). Postoperative diffusion-weighted MRI showed no evidence of ischemic change, and MRA demonstrated the apparently patent STA-MCA bypass as a higher intensity signal than the preoperative finding. Several hours later, she had fluctuating aphasia and numbness in the right upper limb. ^{123}I -IMP-SPECT showed focal intense increase in CBF at the site of anastomosis 7 days after surgery (Fig. 4C, arrows). Intensive blood pressure control and the use of free radical scavenger relieved her symptoms gradually, which completely disappeared 14 days after surgery. She was

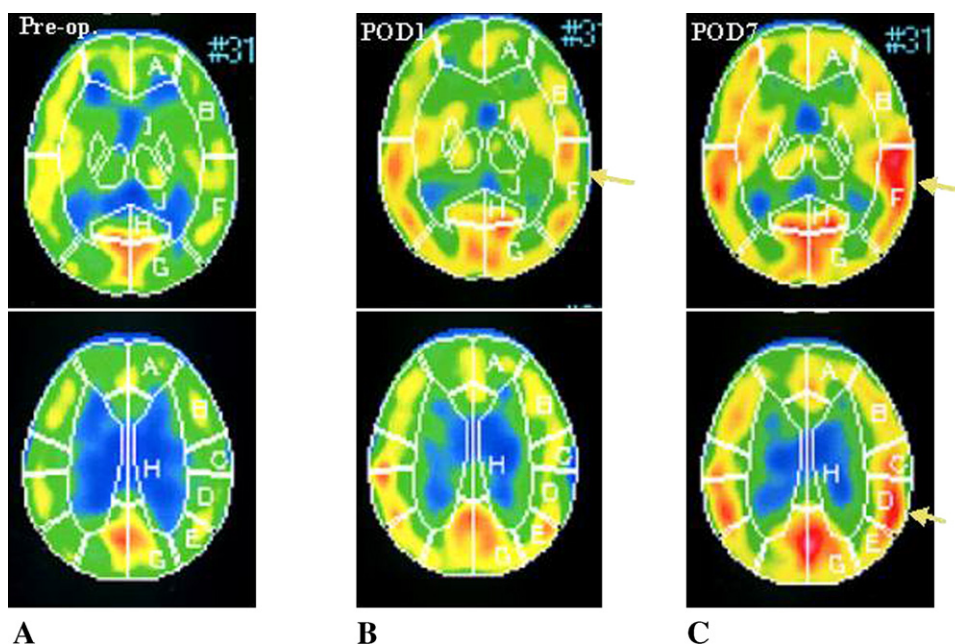


Fig. 4. Case 3. ^{123}I -IMP-SPECT scans before surgery (A) and 1 (B) and 7 days (C) after surgery. Mild increase in CBF was detected on the side of anastomosis 1 day after surgery (arrow in B). The focal intense increase in CBF at the site of anastomosis (arrows in C) was evident 7 days after surgery, in accordance with the manifestation of aphasia and sensory disturbance on the right hand.

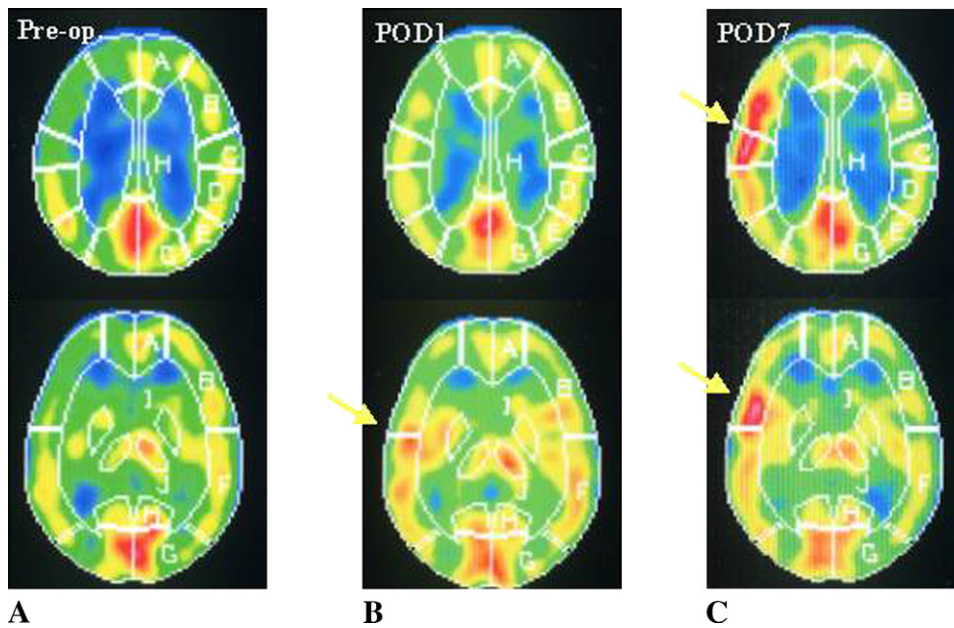


Fig. 5. Case 6. ¹²³I-IMP-SPECT scans before surgery (A) and 1 (B) and 7 days (C) after surgery. Mild increase in CBF was detected at the site of anastomosis 1 day after surgery (arrow in B). The focal intense increase in CBF at the site of anastomosis (arrows in C) was evident 7 days after surgery, in accordance with the manifestation of dysarthria and sensory disturbance on the left hand.

discharged without neurologic deficit, and she did not show neurologic deterioration during the follow-up period.

4.4. Case 6

A 26-year-old woman who has had transient weakness at the left upper extremity since August 2005 was introduced to our service. Stage III moyamoya disease was identified, and SPECT showed her bilateral CBF and cerebrovascular reserve capacities were markedly affected. Therefore, bilateral bypass surgery was planned. STA-

MCA anastomosis with EDMS was performed on the right side in March 2005. After exploration of the parietal branch of the right STA, frontotemporoparietal craniotomy was performed. The recipient artery at the M4 segment of the anterior parietal branch of the MCA was explored and anastomosis was performed between the stump of the STA (1.0 mm in diameter) and the M4 segment (0.8 mm in diameter). Then EDMS and dural pedicle insertion were performed. She showed no neurologic deficit immediately after surgery.

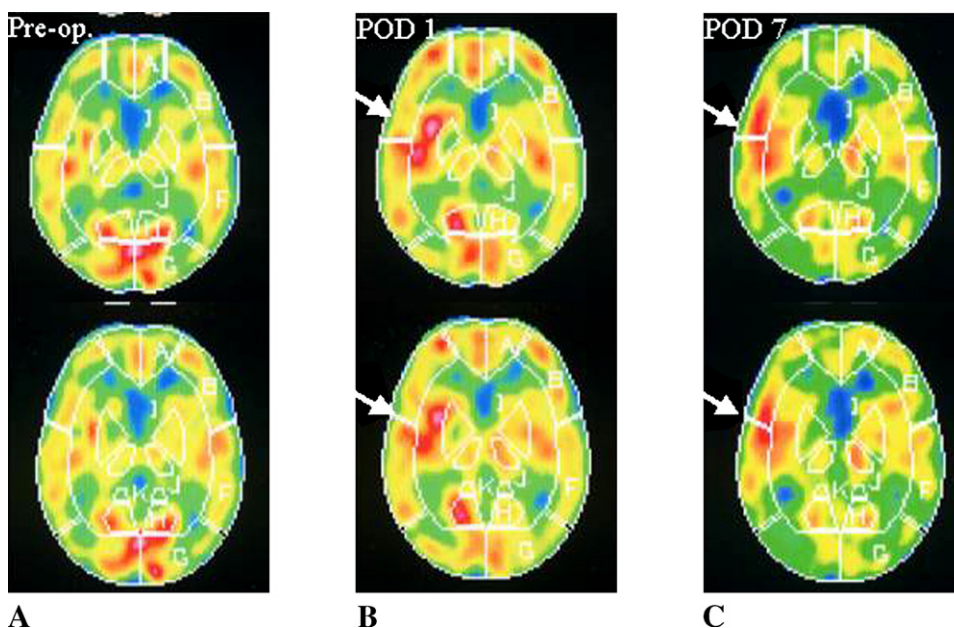


Fig. 6. Case 8. ¹²³I-IMP-SPECT scans before surgery (A) and 1 (B) and 7 days (C) after surgery. Significant increase in CBF was detected on the side of anastomosis 1 day after surgery (arrows in B). The increase in CBF was sustained (arrows in C) 7 days after surgery.

^{123}I -IMP-SPECT 1 day after surgery showed a slight increase in CBF on the right side (Fig. 5B, arrow) compared with the preoperative findings (Fig. 5A). Postoperative diffusion-weighted MRI showed no evidence of ischemic change, and MRA demonstrated the apparently patent STA-MCA bypass as higher intensity signal than the opposite side STA. One day later, she had fluctuating dysarthria, left facial palsy, and numbness in the left upper limb. ^{123}I -IMP-SPECT showed focal intense increase in CBF at the site of anastomosis 7 days after surgery (Fig. 5C, arrows). Intensive blood pressure control and the use of free radical scavenger relieved her symptoms, which completely disappeared 13 days after surgery. She was discharged without neurologic deficit 13 days after surgery.

We performed second-stage surgery on the left side 1 month later. She was discharged uneventfully after successful STA-MCA anastomosis and EDMS, which resulted in disappearance of her ischemic attack as well as the significant improvement of CBF on the bilateral cerebral hemisphere. She did not have neurologic deterioration during the follow-up period.

4.5. Case 8

A 42-year-old woman with transient dysarthria and weakness at the left upper extremity since November 2004 was introduced to our service. Cerebral angiogram revealed

stage II (right)/III (left) moyamoya disease, and SPECT showed her bilateral CBF and cerebrovascular reserve capacities were markedly affected. Bilateral bypass surgery was planned, and STA-MCA anastomosis with EDMS was performed on the right side in June 2005. After exploration of the frontal branch of the right STA, frontotemporoparietal craniotomy was performed. The recipient artery at the M4 segment of the anterior parietal branch of the MCA was explored and anastomosis was performed between the stump of the STA (1.0 mm in diameter) and the M4 segment (1.0 mm in diameter). Then, EDMS and dural pedicle insertion were performed. She showed no neurologic deficit immediately after surgery.

^{123}I -IMP-SPECT 1 day after surgery showed a significant increase in CBF on the right (Fig. 6B, arrows) compared with the preoperative findings (Fig. 6A). One day later, she had progressive headache, and postoperative FLAIR by MRI showed subarachnoid hemorrhage around the site of anastomosis, extending to the ipsilateral sylvian cistern and the basal cistern (Fig. 7A), which was not evident 1 day after surgery by CT scan (data not shown). Diffusion-weighted MRI showed no evidence of ischemic change, and MRA demonstrated the apparently patent STA-MCA bypass as a higher intensity signal than the opposite side STA (Fig. 7B). Significant visualization of the branches of MCA around the site of the anastomosis was also evident

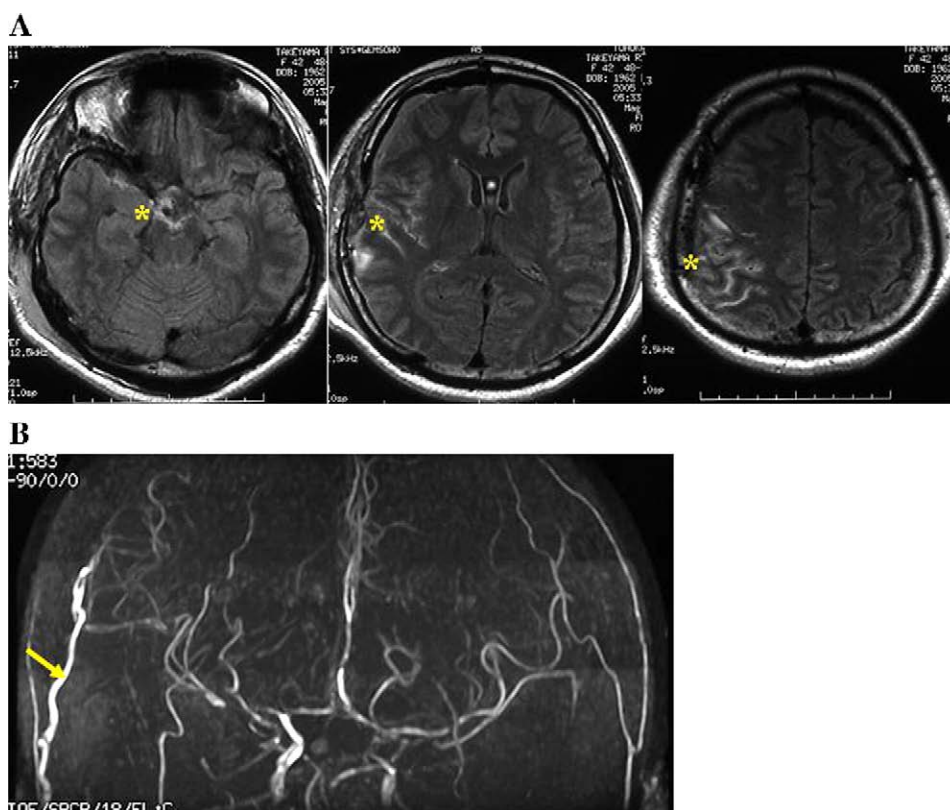


Fig. 7. Case 8. FLAIR by MRI 2 days after surgery demonstrating subarachnoid hemorrhage around the site of anastomosis, extending to the ipsilateral sylvian cistern and the basal cistern (asterisks in A). Postoperative MRA showing the apparently patent bypass as a higher intensity signal than the opposite side STA (arrow in B). Significant visualization of the branches of MCA around the site of anastomosis was also evident compared with the preoperative state.

compared with the preoperative state (Fig. 7B). Intensive blood pressure control and the use of free radical scavenger relieved her symptoms, and the subarachnoid hemorrhage disappeared 10 days after surgery as shown by MRI. She was discharged without neurologic deficit 25 days after surgery.

We performed the second-stage surgery on the left side 4 months later. She was discharged uneventfully after successful STA-MCA anastomosis and EDMS, which resulted in disappearance of her ischemic attack as well as the significant improvement of CBF on the bilateral cerebral hemisphere. She did not experience neurologic deterioration during the follow-up period.

5. Discussion

Postoperative cerebral hyperperfusion syndrome has been considered to be less common in patients with moyamoya disease [6,8,16] because of the relatively low flow revascularization obtained by surgery for moyamoya disease. Furthermore, it was undetermined how rapid increase in CBF affects the chronic ischemic brain in moyamoya disease because comprehensive CBF study during the acute stage has not been done after revascularization for moyamoya disease, except for case reports [4,13]. The present study demonstrated for the first time that STA-MCA anastomosis in patients with adult-onset moyamoya disease can result in temporary neurologic deterioration due to transient focal intense increase in CBF at the site of anastomosis at a substantial rate (13/34, 38.2%) and that intensive blood pressure control can relieve this pathology. Clinical presentation due to focal hyperperfusion in the present series involved not only “hyperperfusion syndrome” (2/34, 5.9%) but also transient focal neurologic deficit mimicking ischemic attack (11/34, 32.4%). Despite the relatively high incidence of the temporary neurologic deterioration due to hyperperfusion (38.2%), no patients had permanent neurologic deficit or delayed neurologic deterioration during the follow-up period. Based on our findings, it was suggested that STA-MCA anastomosis is considered to be a safe and effective treatment of moyamoya disease as long as the deleterious effects of cerebral hyperperfusion during the acute stage are counteracted by intensive blood pressure control. Routine CBF measurement is recommended for accurate diagnosis of postoperative hyperperfusion in moyamoya disease because its treatment is contradictory to that for ischemia. Because SPECT is not available in all the institutions or all of the time, perfusion CT or PWI by MRI can be the alternative modality for the diagnosis of postoperative hyperperfusion. In fact, we recently conducted PWI in patients with moyamoya disease postoperatively, and our preliminary results indicate that PWI is also useful for the diagnosis of hyperperfusion state (unpublished data). Besides the CBF study, the characteristic finding of MRA that demonstrated STA-MCA bypass as a higher intensity

signal than the opposite side STA as shown in all cases with hyperperfusion may support the diagnosis of a hyperperfusion state. In addition to this finding, significant visualization of the branches of the MCA around the site of anastomosis was also evident in some cases compared with the preoperative state. Reversibility of these findings after the recovery of transient neurologic deterioration in all 13 cases further supported the idea that these characteristic findings of MRA reflect a hyperperfusion state. However, some of the patients without postoperative symptomatic hyperperfusion also presented a similar MRA finding of the STA, and further evaluation is needed to verify the specificity and the mechanism of these findings in future studies. Alternatively, we do not completely rule out the possibility that surgical manipulation of the STA might affect, at least in part, the MRA finding of STA.

On one hand, 2 patients (cases 5 and 8) manifested the cerebral hyperperfusion syndrome compatible to that seen after carotid endarterectomy or STA-MCA anastomosis for atherosclerotic cerebral occlusive disease, which is characterized by unilateral headache, facial and ocular pain, seizures, and focal symptoms secondary to cerebral edema or intracerebral hemorrhage [15,18,19]. Because our procedure includes single anastomosis at the distal M4 with a diameter less than 1 mm, it is conceivable that patients with moyamoya disease are more vulnerable to cerebral hyperperfusion after STA-MCA anastomosis. On the other hand, the clinical manifestations due to hyperperfusion in the other 11 patients were distinct from the cerebral hyperperfusion syndrome. The clinical presentation of the 11 cases was characterized by fluctuating aphasia, numbness in the contralateral side of the face and upper limb, facial palsy, and dysarthria, in accordance with the anatomical location of the site of anastomosis. Headache was associated with these focal neurologic signs only in limited cases, and seizure was seen only in 2 cases. Furthermore, case 1 showed delayed increase in localized CBF 6 days after surgery and subsequently presented focal neurologic deficit the next day, and such temporal profile seems to be unusual after carotid endarterectomy or STA-MCA anastomosis for atherosclerotic cerebral occlusive disease. Taken together, the clinical presentation mimicking ischemic attack seen in 11 patients is likely to be the characteristic pattern of focal hyperperfusion in patients with moyamoya disease [3,4,13]. In another similar case, a 39-year-old patient with moyamoya disease had transient aphasia 2 days after left STA-MCA anastomosis [4]. Technetium 99m hexamethyl propylene amine oxime SPECT detected focal hyperperfusion at the left frontal operculum during the course of aphasia [4].

The underlying mechanism of such specific manifestations of hyperperfusion in patients with moyamoya disease remains undetermined. Certain specific biological conditions such as the overexpression of proteins including angiogenic factors and extracellular matrix proteins, which not only contribute to angiogenesis but also affect vascular

permeability in the chronic ischemic cortex, may be involved in these intrinsic responses to vascular reconstruction against the chronic ischemic brain in moyamoya disease. It is conceivable that increased vascular permeability by such mechanism resulted in subarachnoid hemorrhage after revascularization for moyamoya disease in our 2 cases (cases 5 and 8), although the exact mechanism is unclear. Because ROS has been implicated in cerebral ischemia/reperfusion injury [1,2], differences in ROS production after vascular reconstruction, vulnerability to ROS, and the expression of antioxidant enzymes in the chronic ischemic cortex may also participate in this pathology. In fact, antioxidant agents are reported to prevent hyperperfusion syndrome after carotid endarterectomy in patients with atherosclerotic occlusive disease and markedly affect cerebrovascular reserve capacity [12]. Therefore, we treated our patients with edaravone, a novel free radical scavenger, to ameliorate the unfavorable effects of hyperperfusion on the affected brain. Long-term follow-up of the neurologic function including cognitive functions and histologic changes in the affected brain is needed, because exposure to sublethal levels of ROS can affect organelles, and thus lead to delayed neuronal damage by apoptosis [2]. In fact, postoperative cerebral hyperperfusion is reported to be associated with impairment of cognitive function in patients undergoing carotid endarterectomy [14]. In our series, no patients had delayed neurologic deterioration or delayed radiologic changes of the affected cortex including changes in signal intensity on MRI and marked regionally specific cortical atrophy [13].

Identification of the predictors for cerebral hyperperfusion in patients with moyamoya disease is clinically important. Preoperative cerebrovascular reserve capacity [10,11,23], severity of ischemia during surgery, and anatomical vascular structures around the site of the anastomosis may affect postoperative cerebral hyperperfusion. In our series, most of the patients showed preoperative cerebrovascular reserve capacity of less than 0% (steal phenomenon), which may contribute to the high incidence of symptomatic hyperperfusion postoperatively. Regarding intraoperative ischemic insult during anastomosis, which may facilitate postischemic hyperperfusion, most of the cases were subjected to temporary occlusion at distal M4 within 30 minutes in our series. Patient age may also affect postoperative cerebral hyperperfusion. It is totally unclear how rapid increase in CBF affects the ischemic brain in childhood moyamoya disease, although a substantial number of children with moyamoya disease, as much as 59.3% of patients with STA-MCA anastomosis, were reported to suffer transient neurologic deterioration due to an unknown mechanism [21]. The limited number of pediatric cases evaluated by SPECT did not allow us to evaluate the effect of patient age, and this issue remains to be elucidated in future study.

In conclusion, surgical revascularization including STA-MCA anastomosis is a safe and effective treatment of

moyamoya disease, although temporary neurologic deterioration due to hyperperfusion could occur at a substantial rate. Routine CBF measurement is recommended for accurate diagnosis of postoperative hyperperfusion in moyamoya disease because its treatment is contradictory to that for ischemia.

References

- [1] Chan PH. Role of oxidants in ischemic brain damage. *Stroke* 1996;27:1124-9.
- [2] Fujimura M, Tominaga T, Chan PH. Neuroprotective effect of antioxidant in cerebral ischemia: role of neuronal apoptosis. *Neurocrit Care* 2005;2:59-66.
- [3] Fujimura M, Shimizu H, Tominaga T. Transient focal neurological deficit due to hyperperfusion after superficial temporal artery-middle cerebral artery anastomosis in patients with moyamoya disease. *Surg Cereb Stroke (Jpn)* 2006;34:37-41.
- [4] Furuya K, Kawahara N, Morita A, Momose T, Aoki S, Kirino T. Focal hyperperfusion after superficial temporal artery-middle cerebral artery anastomosis in a patient with moyamoya disease. Case report. *J Neurosurg* 2004;100:128-32.
- [5] Heros RC, Scott RM, Ackerman RH, Conner ES. Temporary neurological deterioration after extracranial-intracranial bypass. *Neurosurgery* 1984;15:178-85.
- [6] Houkin K, Ishikawa T, Yoshimoto T, Abe H. Direct and indirect revascularization for moyamoya disease: surgical techniques and peri-operative complications. *Clin Neurol Neurosurg* 1997;99(Suppl 2):S142-5.
- [7] Houkin K. Direct bypass surgery. In: Loftus CM, editor. *Moyamoya disease*. Rolling Meadows, Illinois: AANS Press; 2001. p. 157-65.
- [8] Houkin K, Nonaka T, Baba T. Peri-operative complications in surgical treatment for moyamoya disease. Report by the Research Committee on Spontaneous Occlusion of the Circle of Willis (Moyamoya Disease) 2004. p. 47-50.
- [9] Ishikawa T, Houkin K, Kamiyama H, Abe H. Effects of surgical revascularization on outcome of patients with pediatric moyamoya disease. *Stroke* 1997;28:1170-3.
- [10] Komoribayashi N, Ogasawara K, Kobayashi M, Saitoh H, Terasaki K, Inoue T, Ogawa A. Cerebral hyperperfusion after carotid endarterectomy is associated with preoperative hemodynamic impairment and intraoperative cerebral ischemia. *J Cereb Blood Flow Metab* 2006;26:878-84.
- [11] Ogasawara K, Yukawa H, Kobayashi M, Mikami C, Konno H, Terasaki K, et al. Prediction and monitoring of cerebral hyperperfusion after carotid endarterectomy by using single-photon emission computerized tomography scanning. *J Neurosurg* 2003;99:504-10.
- [12] Ogasawara K, Inoue T, Kobayashi M, et al. Pretreatment with the free radical scavenger edaravone prevents cerebral hyperperfusion after carotid endarterectomy. *Neurosurgery* 2004;55:1060-7.
- [13] Ogasawara K, Komoribayashi N, Kobayashi M, Fukuda T, Inoue T, Yamada K, Ogawa A. Neural damage caused by cerebral hyperperfusion after arterial bypass surgery in a patient with moyamoya disease: case report. *Neurosurgery* 2005;56:E1380.
- [14] Ogasawara K, Yamadate K, Kobayashi M, Endo H, Fukuda T, Yoshida K, et al. Postoperative cerebral hyperperfusion associated with impaired cognitive function in patients undergoing carotid endarterectomy. *J Neurosurg* 2005;102:38-44.
- [15] Piepgras DG, Morgan MK, Sundt Jr TM, Yanagihara T, Mussman LM. Intracerebral hemorrhage after carotid endarterectomy. *J Neurosurg* 1988;68:532-6.
- [16] Sakamoto T, Kawaguchi M, Kurehara K, Kitaguchi K, Furuya H, Karasawa J. Risk factors for neurologic deterioration after revascu-

- larization surgery in patients with moyamoya disease. *Anesth Analg* 1997;85:1060-5.
- [17] Shirane R, Yoshida Y, Takahashi T, Yoshimoto T. Assessment of encephalo-galeo-myo-synangiosis with dural pedicle insertion in childhood moyamoya disease: characteristics of cerebral blood flow and oxygen metabolism. *Clin Neurol Neurosurg* 1997;99 (Suppl 2):S79-S85.
- [18] Solomon RA, Loftus CM, Quest DO, Correll JW. Incidence and etiology of intracerebral hemorrhage following carotid endarterectomy. *J Neurosurg* 1986;64:29-34.
- [19] Sundt Jr TM, Sharbrough FW, Piepgras DG, Kearns TP, Messick JM, O'Fallon WM. Correlation of cerebral blood flow and electroencephalographic changes during carotid endarterectomy: with results of surgery and hemodynamics of cerebral ischemia. *Mayo Clin Proc* 1981;56:533-43.
- [20] Suzuki J, Takaku A. Cerebrovascular 'moyamoya' disease. Disease showing abnormal net-like vessels in base of brain. *Arch Neurol* 1969; 20:288-99.
- [21] Taki W, Tanaka M, Miyamoto S, Nagata I, Kikuchi H. Postoperative transient neurological deficit in children with moyamoya disease. Annual Report 1994 by the Research Committee on Spontaneous Occlusion of the Circle of Willis (Moyamoya Disease) 1995. p. 88-93.
- [22] Yoshida YK, Shirane R, Yoshimoto T. Non-anastomotic bypass surgery for childhood moyamoya disease using dural pedicle insertion over the brain surface combined with encephalogalectomyosynangiosis. *Surg Neurol* 1999;51:404-11.
- [23] Yoshimoto T, Houkin K, Kuroda S, Abe H, Kashiwaba T. Low cerebral blood flow and perfusion reserve induce hyperperfusion after surgical revascularization: case reports and analysis of cerebral hemodynamics. *Surg Neurol* 1997;48:132-8.