

Vascular

## Sudden cortical blindness in an adult with moyamoya disease

Dal-Soo Kim, MD, Seok-Gu Kang, MD\*, Do-Sung Yoo, MD, Pil-Woo Huh, MD,  
Kyoung-Suok Cho, MD, Moon-Chan Kim, MD

*Department of Neurosurgery, The Catholic University of Korea College of Medicine, Uijeongbu St. Mary's Hospital,  
Uijeongbu, Gyeonggi 480-130, Republic of Korea*

Received 5 September 2005; accepted 20 March 2006

### Abstract

**Background:** We report a case of an adult with MMD who presented initially with left visual field defect that had suddenly progressed to bilateral cortical blindness 1 year and 9 months later.

**Case Description:** A 33-year-old male presented with visual blurring and mild right hemiparesis that developed suddenly. He was regarded as having MMD based on an imaging study. An inverted encephalodurogaleosynangiosis using the left occipital artery and inverted encephaloduroarterioga-leosynangiosis with the parietal branch of the superficial temporal artery were done. The postoperative course was uneventful and without any complication. Several months later, he visited again because of sudden bilateral blindness preceded by repeated transient blindness in both eyes for 4 days. The right posterior temporal artery, which was well visualized at the time of the first postoperative follow-up angiography, was no longer seen on repeated 4-vessel angiography. Biochemical analysis including prothrombin and thrombin time, activated partial thromboplastin time, fibrinogen, d-dimer, plasminogen, antithrombin, platelet, protein C and S, lupus anticoagulant, and cardiolipin antibodies; VDRL was within the reference range.

**Conclusion:** The authors suggest abnormal thromboembolism as a presumed mechanism of the pathogenesis of MMD in this patient.

© 2007 Elsevier Inc. All rights reserved.

**Keywords:** Adult moyamoya disease; Cortical blindness; Sudden progression; Thromboembolism

### 1. Introduction

Moyamoya disease is a progressive occlusive cerebrovascular disease characterized by stenosis or occlusion at the distal internal carotid arteries and the proximal anterior cerebral and/or the middle cerebral artery and the compensatory development of abnormal moyamoya vessels at the base of the brain. It has been indicated from previous studies concerning the progression of MMD that the disease tends to be progressive and dynamic in childhood, whereas it becomes stable in adulthood [6,11,17].

However, our case indicates that MMD can be suddenly progressive even in adulthood, of which the incidence is considerably low compared with pediatric MMD.

*Abbreviations:* CT, computed tomography; FLAIR, fluid attenuated inversion recovery; MMD, moyamoya disease; MRI, magnetic resonance imaging; SPECT, single photon emission computerized tomography.

\* Corresponding author. Tel.: +82 31 820 3638; fax: +82 31 847 2369.

*E-mail address:* [seokgu9@kornet.net](mailto:seokgu9@kornet.net) (S.-G. Kang).

### 2. Case report

A 33-year-old male with visual blurring and mild right hemiparesis that developed suddenly on April 20, 2003, was referred to our hospital. This patient visited other hospitals with the above-mentioned chief complaints, where brain MRI taken on April 30, 2003, revealed a small localized area of bright signal in the white matter of the right frontal lobe adjacent to the frontal horn of the lateral ventricle and a large cortical bright signal involving the left occipital lobe in a FLAIR image and T2-weighted image, which were suggestive of cerebral infarct (Fig. 1).

Four-vessel angiography demonstrated Suzuki and Takaku's angiographic stage III and stage IV in the right and the left side, respectively, and the posterior circulation showed severe steno-occlusive changes of bilateral posterior cerebral arteries in their quadrigeminal segments with no opacification of cortical branches (Fig. 2).

Neurologic examination showed right homonymous hemianopsia and mild right hemiparesis (G4+/G4–). Brain

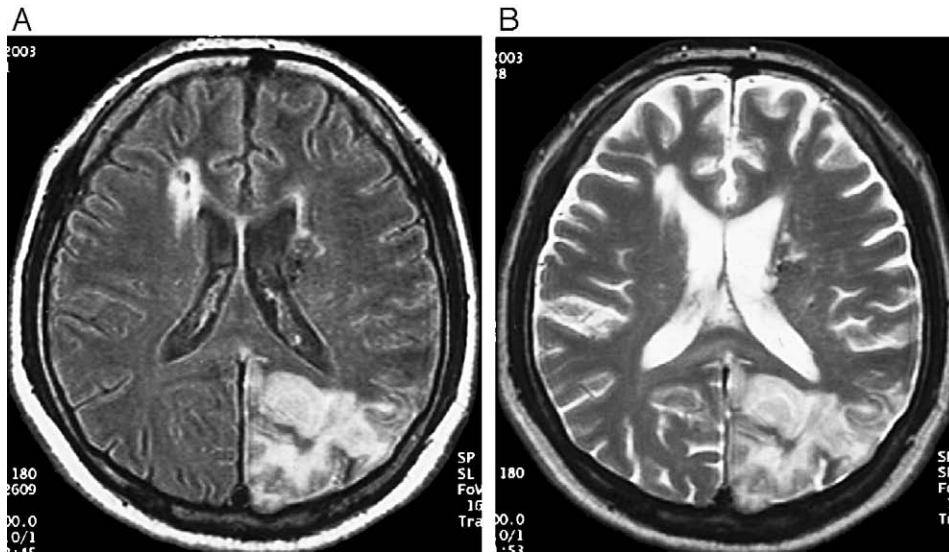


Fig. 1. Preoperative axial FLAIR (A) and T2-weighted image (B) of MRI scans showing a small infarct at the right frontal white matter and a cortical large infarct at the left occipital lobe.

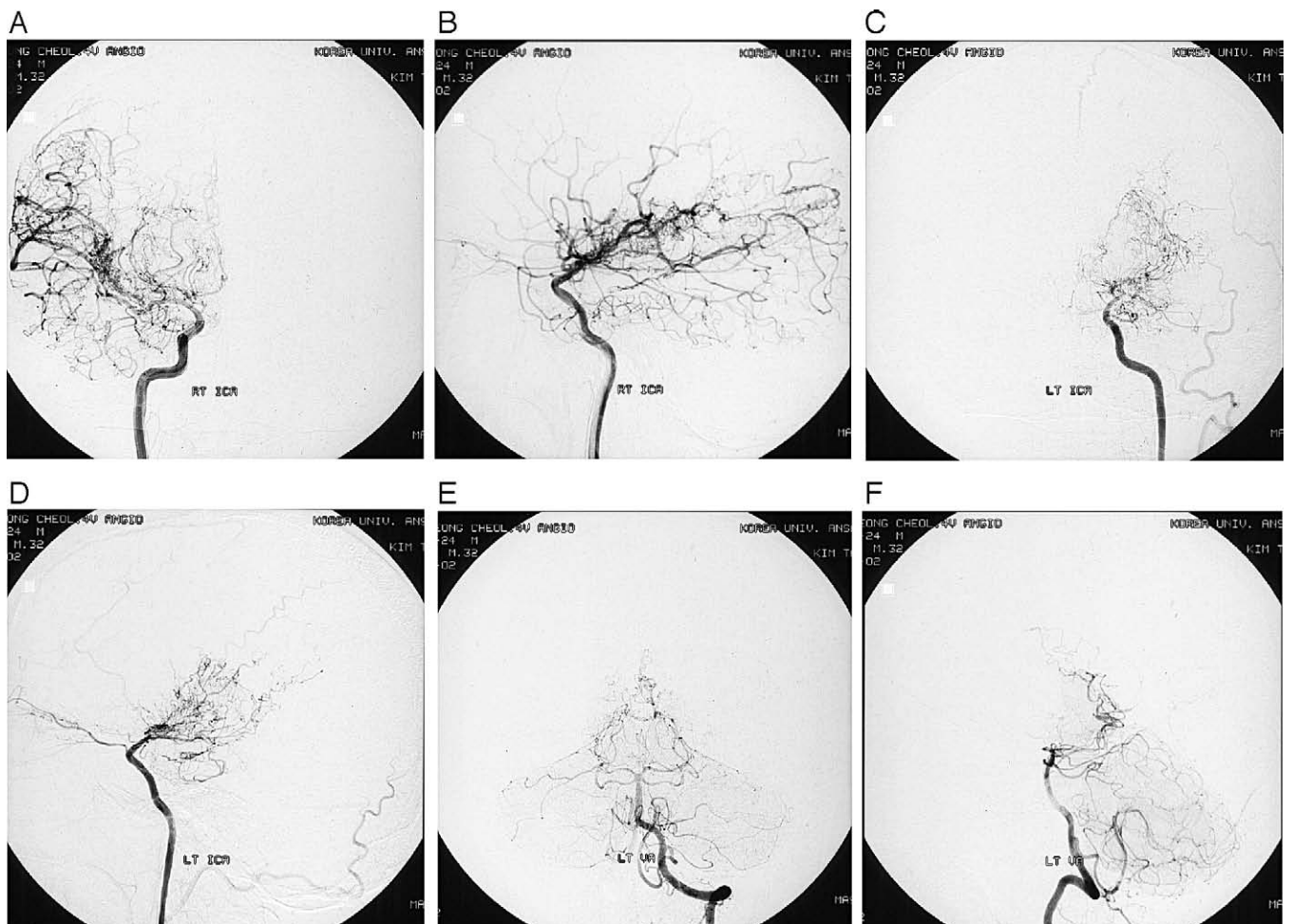


Fig. 2. Four-vessel angiogram showing Suzuki and Takaku's angiographic stage III on the right side (A and B), stage IV on the left side (C and D), and poor visualization of distal branches of both posterior cerebral arteries (E and F).

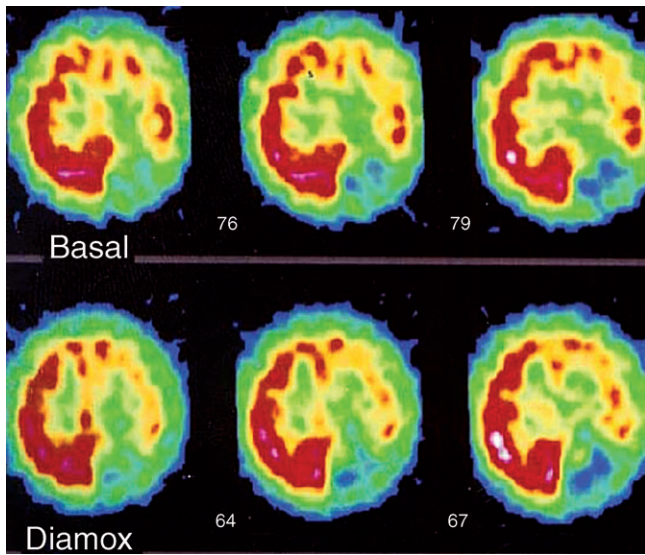


Fig. 3. <sup>99m</sup>Tc-HMPAO brain SPECT showing a perfusion defect at the left occipital lobe and a decreased perfusion at the left temporoparietal region.

SPECT using <sup>99m</sup>Tc-HMPAO revealed perfusion defect in the left occipital lobe and decreased perfusion in the left temporoparietal region (Fig. 3).

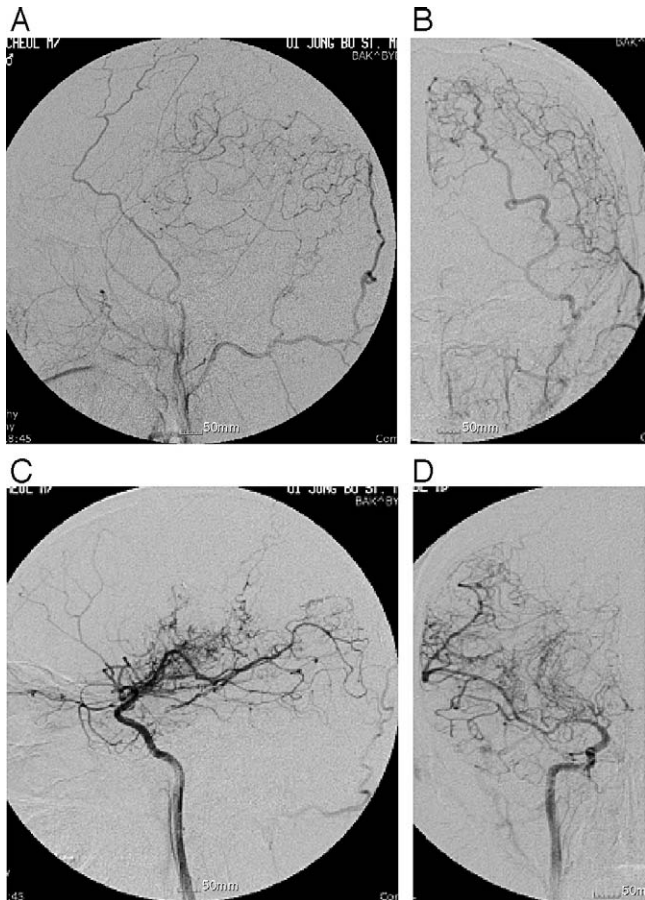


Fig. 4. Follow-up angiogram showing excellent revascularization at the left occipital and temporoparietal region (A and B) and good patency of the right posterior temporal artery (C and D).

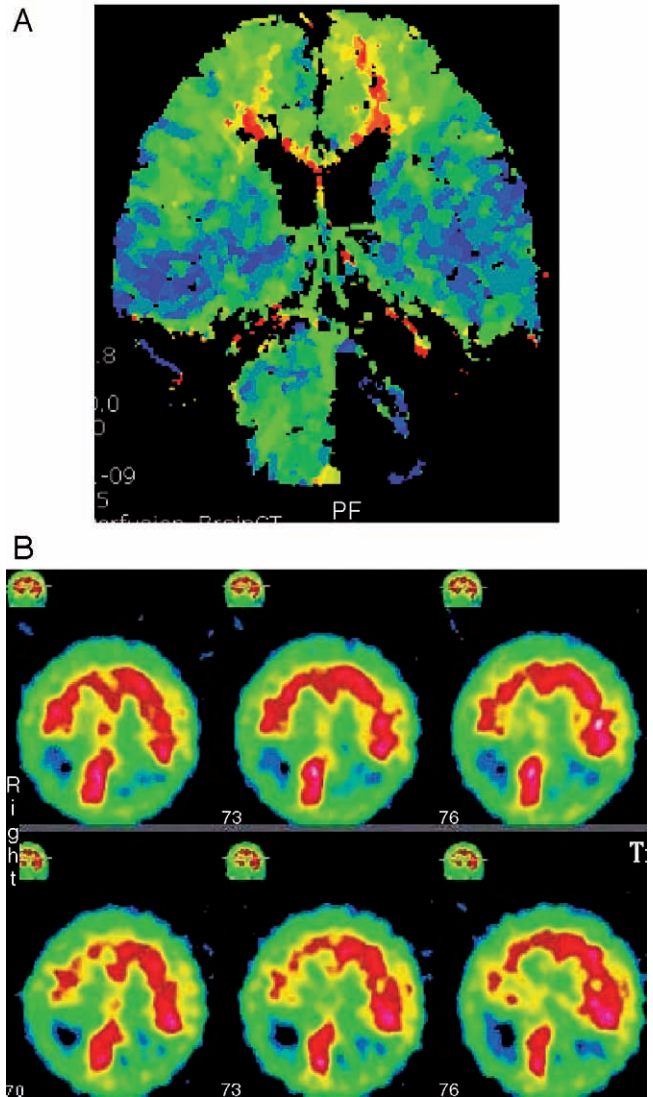


Fig. 5. Brain perfusion CT (A) and <sup>99m</sup>Tc-HMPAO brain SPECT (B) showing newly developed perfusion defect at the right posterior temporo-occipital region in addition to preexistent perfusion defect at the left occipital lobe.

An inverted encephalodurogaleosynangiosis using the left occipital artery and inverted encephaloduroarteriogaleosynangiosis with the parietal branch of the superficial temporal artery were done on May 14, 2003, and June 17, 2003, respectively.

The postoperative course was uneventful and without any complication. Follow-up angiography, which was done on February 4, 2004, revealed excellent revascularization on the left occipital and temporoparietal region and good patency of the right posterior temporal artery (Fig. 4).

On February 13, 2004, the patient with suddenly developed bilateral blindness preceded by repeated transient blindness in both eyes for 4 days was taken by his spouse to our outpatient clinic. Brain perfusion CT taken in February 13 revealed another perfusion defect involving the right posterior temporo-occipital area, which was consistent with

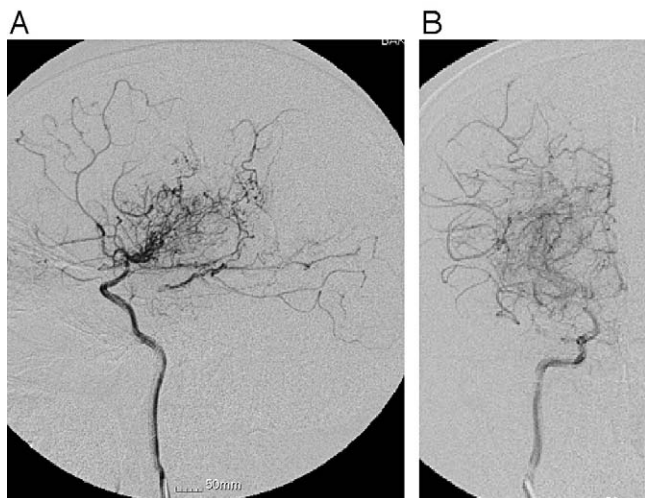


Fig. 6. Repeated 4-vessel angiogram (A and B) showing nonvisualization of the right posterior temporal artery that was clearly seen on the postoperative first follow-up angiogram.

the finding using  $^{99m}\text{Tc}$ -HMPAO brain SPECT (Fig. 5). The right posterior temporal artery that was well visualized at the time of the first postoperative follow-up angiography on February 4, 2004, was no longer seen on the repeated 4-vessel angiography taken on February 16, 2004 (Fig. 6). Since then, he had been on clopidogrel (75 mg) and acetylsalicylic acid (200 mg) for the following 4 weeks under the assumption of MMD-related thromboembolism.

However, biochemical analysis including prothrombin and thrombin time, activated partial thromboplastin time, fibrinogen, d-dimer, plasminogen, antithrombin, platelet, protein C and S, lupus anticoagulant, cardiolipin antibodies, and VDRL was within the reference range.

### 3. Discussion

Unlike pediatric MMD, it is very rare to verify clinical and/or angiographic progression in adult MMD. Furthermore, adult MMD, which presented with cortical blindness due to visual field defect, is extremely rare. Only 2 cases were reported in the literature: one case is a 30-year-old woman who initially presented with a transient visual field defect that progressed to blindness 1 month later [5], and the other, a 31-year-old pregnant woman who presented with sudden blindness on the right side [19].

The authors suggested that an unstable hemodynamic state or fewer external carotid artery collaterals in the posterior circulation in the first case and hypercoagulability due to pregnancy in the second case are the mechanisms that caused blindness in these moyamoya patients. The clinical signs of MMD are usually presumed to be caused by the chronic hemodynamic compromise known to occur in steno-occlusive cerebrovascular disease.

The most frequently used treatment modalities for MMD are direct and/or indirect cerebral revascularization procedures, which are known to reverse chronic hemodynamic

insufficiency by improving cerebral blood flow on the affected vascular territories [8,9,13,14].

However, even with sufficient neovascularization, transient ischemic attack or stroke, mental retardation, and psychomotor disturbance may develop [8,10]. Therefore, the clinical progress of MMD under these conditions underlines the possibilities of other pathologies causing arterial ischemic stroke.

According to recent articles [1-4,7,12,15,16,18], it is attempting to speculate that some hemostatic abnormalities may contribute to the pathogenesis of pediatric MMD.

Bonduel et al [2] described that prothrombotic disorders were associated with MMD in up to 40% of pediatric patients [8].

Our case also suggested that the possibility of abnormal thromboembolism is most likely to be related with blindness due to sudden nonvisualization of the posterior temporal artery on the right side, which was very prominent at the postoperative follow-up angiography taken 12 days before in spite of laboratory findings within the reference range.

### 4. Conclusion

Our case was thought to be a very rare adult MMD, which presented with suddenly progressed blindness due to infarction of the occipital lobe.

Although most patients with MMD present with cerebral infarction or hemorrhage of an anterior circulation, a posterior circulation symptom or visual impairment could be an initial manifestation of the MMD. Although it is mainly pediatric MMD patients who progress rapidly clinically and/or radiologically, adult patients can suddenly deteriorate even in the posterior circulation.

Furthermore, it is strongly suggested that other mechanisms, such as thromboembolism, should be elucidated in addition to the hemodynamic compromise to explain the clinical or radiological progression in MMD.

### References

- [1] Andeejani AM, Salih MA, Kolawole T, Gader AM, Malabarey TO, al Damegh S, al Boukai A. Moyamoya syndrome with unusual angiographic findings and protein C deficiency: review of the literature. *J Neurol Sci* 1998;159:11-6.
- [2] Bonduel M, Hepner M, Sciuccati G, Torres AF, Tenenbaum S. Prothrombotic disorders in children with moyamoya syndrome. *Stroke* 2001;32:1786-92.
- [3] Booth F, Yanofsky R, Ross IB, Lawrence P, Oen K. Primary antiphospholipid syndrome with moyamoya-like vascular changes. *Pediatr Neurosurg* 1999;31:45-8.
- [4] Charuvanij A, Laothamatas J, Torcharus K, Sirivimonmas S. Moyamoya disease and protein S deficiency: a case report. *Pediatr Neurol* 1997;17:171-3.
- [5] Chu MK, Lee IH, Kim DI, Kim SM. Moyamoya disease initially presenting visual field defect. *Yonsei Med J* 2001;42:566-70.
- [6] Ezura M, Yoshimoto T, Fujiwara S, Takahashi A, Shirane R, Mizoi K. Clinical and angiographic follow-up of childhood-onset moyamoya disease. *Childs Nerv Syst* 1995;11:591-4.

- [7] Fujiwara S, Miyazono M, Tsuda H, Fukui M. Intraventricular hemorrhage and cerebral ischemic attacks in the presence of lupus anticoagulant mimicking moyamoya disease. *J Neurosurg Sci* 1993; 37:161-4.
- [8] Horn P, Bueltmann E, Buch CV, Schmiedek P. Arterio-embolic ischemic stroke in children with moyamoya disease. *Childs Nerv Syst* 2005;21:104-7.
- [9] Houkin K, Kuroda S, Nakayama N. Cerebral revascularization for moyamoya disease in children. *Neurosurg Clin N Am* 2001;12: 575-84.
- [10] Imaizumi C, Imaizumi T, Osawa M, Fukuyama Y, Takeshita M. Serial intelligence test scores in pediatric moyamoya disease. *Neuropediatrics* 1999;30:294-9.
- [11] Ishii K, Isono M, Kobayashi H, Kamida T. Temporal profile of angiographical stages of moyamoya disease. *Neurol Res* 2003;25: 405-10.
- [12] Lanthier S, Carmant L, David M, Larbrisseau A, de veber G. Stroke in children: the coexistence of multiple risk factors predicts poor outcome. *Neurology* 2000;54:371-8.
- [13] Matsushima T, Fujiwara S, Nagata S, Fujii K, Fukui M, Kitamura K, Hasuo K. Surgical treatment for paediatric patients with moyamoya disease by indirect revascularization procedures. *Acta Neurochir* 1989;98:135-40.
- [14] Matsushima T, Inoue T, Katsuta T, Natori Y, Suzuki S, Ikezaki K, Fukui M. An indirect revascularization method in the surgical treatment of moyamoya disease—various kinds of indirect procedures and a multiple combined indirect procedure. *Neurol Med Chir* 1998; 38:297-302.
- [15] McCurdy D, Sanematsu L, Sandborg C, Nugent D. Anticardiolipin antibodies (ACL) in children with cerebrovascular accidents. *Thromb Haemost* 1993;69:1225.
- [16] Schoning M, Klein R, Krageloh-Mann I, Falck M, Bien S, Berg PA, Michaelis R. Antiphospholipid antibodies in cerebrovascular ischemia and stroke in childhood. *Neuropediatrics* 1994;25:8-14.
- [17] Suzuki J, Takaku A. Cerebrovascular ‘moyamoya’ disease. *Arch Neurol* 1969;20:288-99.
- [18] Tsuda H, Hattori S, Tanabe S, Nishioka S, Matsushima T, Ikezaki K, Fukui M, Kinoshita S, Hamasaki N. Thrombophilia found in patients with moyamoya disease. *Clin Neurol Neurosurg* 1997;99:S229-33.
- [19] Ushimura S, Mochizuki K, Ohashi M, Hosokawa H. Sudden blindness in the fourth month of pregnancy led to diagnosis of moyamoya disease. *Ophthalmologica* 1993;207:169-73.