

ADJUNCTIVE RHEOLYTIC THROMBECTOMY FOR CENTRAL VENOUS SINUS THROMBOSIS: TECHNICAL CASE REPORT

Jacobo Kirsch, M.D.

Department of Neuroradiology,
The Cleveland Clinic Foundation,
Cleveland, Ohio

Peter A. Rasmussen, M.D.

Department of Neurosurgery,
The Cleveland Clinic Foundation,
Cleveland, Ohio

Thomas J. Masaryk, M.D.

Departments of Neuroradiology and
Neurosurgery,
The Cleveland Clinic Foundation,
Cleveland, Ohio

John Perl II, M.D.

Department of Interventional Radiology,
Abbott Northwestern Hospital,
Minneapolis, Minnesota

David Fiorella, M.D.

Departments of Neuroradiology and
Neurosurgery,
The Cleveland Clinic Foundation,
Cleveland, Ohio

Reprint requests:

David Fiorella, M.D.,
Department of Neurosurgery,
The Cleveland Clinic Foundation,
9500 Euclid Avenue, S80,
Cleveland, OH 44195.
Email: fioreld@ccf.org

Received, March 10, 2005.

Accepted, October 18, 2006.

OBJECTIVE: Patients with dural sinus thrombosis occasionally present with a malignant clinical course marked by parenchymal hemorrhage accompanied by either a severe neurological deficit or a persistent deterioration on therapeutic levels of antithrombotic medications. This scenario precludes traditional revascularization strategies with direct fibrinolytic infusion because of the risk of exacerbating the preexisting cerebral hemorrhage. In the current series, we describe our experience using the AngioJet (Possis Medical, Minneapolis, MN), a rheolytic mechanical thrombectomy device, in conjunction with systemic heparinization to achieve rapid sinus revascularization without fibrinolytic therapy.

METHODS: A retrospective review of a prospectively maintained database identified four patients ranging in age from 28 to 67 years (three women, one man) with cerebral venous thrombosis and rapidly deteriorating levels of consciousness who underwent transfemoral intravenous rheolytic thrombectomy using the AngioJet XML and/or Xpedior catheters (Possis Medical). The imaging features, treatment specifications, and disease outcome were reviewed.

RESULTS: All four patients underwent successful mechanical thrombectomy as indicated by restoration of blood flow through the affected sinuses. Three of the four patients demonstrated normalization of angiographic transit time after thrombectomy. In these three patients, rapid neurological improvement ensued. The fourth patient died during the periprocedural period. No procedural complications were encountered.

CONCLUSION: Systemic heparinization with adjunctive rheolytic thrombectomy (without fibrinolytic therapy) is a safe and effective treatment strategy for selected patients with dural venous sinus thrombosis.

KEY WORDS: Prognosis, Thrombectomy, Treatment, Venous sinus thrombosis

Neurosurgery 60:E577–E578, 2007

DOI: 10.1227/01.NEU.0000255339.26027.68

www.neurosurgery-online.com

Cerebral venous thrombosis (CVT) is an uncommon condition that is often challenging to diagnose because of its variable clinical presentations and frequently subtle imaging findings (1, 8, 15). If left untreated, this condition may result in uncontrolled cerebral venous hypertension, impaired cerebral perfusion, venous infarction with edema, cerebral hemorrhage, and death (1, 8, 15).

If patients are neurologically stable, anticoagulation is the treatment of choice (1, 3, 8). However, if patients demonstrate progressive neurological deficits despite heparinization, more aggressive treatment measures are required. In the absence of intracranial hemor-

rhage, these patients may be treated with a direct microcatheter infusion of fibrinolytic agents into the clot via a transfemoral transvenous approach. However, existing data suggest that the risk-to-benefit profile of this approach is unfavorable in the setting of intracranial hemorrhage (5). In addition, in patients presenting with a precipitous neurological deterioration, the time required for a fibrinolytic infusion alone to restore adequate venous outflow (24–48 h) is often unacceptable (5). In these two categories of patients, systemic heparinization with adjuvant rheolytic thrombectomy represents a potentially superior strategy to achieve sinus recanalization. In

the current case series, we report our experience using the AngioJet Rheolytic Thrombectomy System (Possis Medical, Minneapolis, MN) to restore venous sinus patency.

PATIENTS AND METHODS

This series represents a retrospective review of four consecutive patients treated for CVT by mechanical thrombectomy. All patients and/or their families provided informed consent and were monitored before and after their treatment in the neurological intensive care unit (NICU). All patients received concomitant intravenous (IV) heparin to achieve therapeutic anticoagulation (activated partial thromboplastin time, 50–70 s).

All patients underwent cerebral angiography and central venography with mechanical thrombectomy using the AngioJet Rheolytic Thrombectomy System. We used modified Thrombolysis in Myocardial Infarction (mTIMI) grades to quantify flow through the dural venous system.

The AngioJet is a coaxial lumen guidewire-directed catheter with a 5-French outer diameter. Thrombectomy is accomplished with the introduction of a pressurized saline jet stream through the directed orifices in the catheter distal tip. The jets generate a localized low-pressure zone via the Bernoulli effect, which mechanically fractionates the thrombus. The saline and thrombus are then suctioned back into the exhaust lumen of the catheter and out of the body for disposal minimizing the risk for pulmonary embolism.

RESULTS

Between November 2001 and July 2002, four patients (one man, three women; age range, 28–67 yr; mean age, 41 yr) presenting to our institution with symptomatic dural venous sinus thrombosis (Table 1) underwent treatment with transvenous rheolytic thrombectomy. In three cases, sinus thrombosis was complicated by parenchymal hemorrhage. All patients were fully heparinized on admission. Intervention was initiated because of progression of symptoms on heparin ($n = 1$) or a malignant neurological presentation ($n = 3$). No fibrinolytic agents were used during endovascular intervention.

In all patients, recanalization of the occluded sinus or sinuses was achieved using the AngioJet rheolytic mechanical thrombectomy device. Using mTIMI grades to quantify flow through the dural venous system, we measured all four patients as mTIMI 0 (no perfusion) in the affected sinuses (Table 2) before the procedure. The treated sinuses in all patients were restored to mTIMI 2 (partial reperfusion) by the end of the procedure. Three of the four patients showed marked qualitative improvement in angiographic transit times after thrombectomy. These three patients improved after therapy and eventually returned to their prethrombosis baseline. One patient (Patient 3) continued to deteriorate after the procedure and subsequently died. There were no new cerebral hemorrhages or progressions of existing cerebral hemorrhages after the procedures were performed. No procedural complications were encountered.

ILLUSTRATIVE CASES

Patient 1

A 38-year-old woman presented to an outside hospital with a 2-day history of worsening headache accompanied by vomiting, seizures, and, ultimately, aphasia and an inability to walk. At presentation, computed tomographic scans, magnetic resonance imaging (MRI) scans, and intracranial angiography were initially interpreted as negative. A magnetic resonance venogram (MRV) was then performed, which demonstrated CVT of the superior sagittal sinus (SSS) and bilateral transverse sinuses. At this time, the patient was transferred to our institution for further work-up and treatment. Upon arrival, she was stuporous with left hemiplegia. In addition to dural sinus thrombosis, noninvasive imaging also demonstrated bilateral pulmonary emboli and deep femoral vein thrombosis.

She was admitted on a heparin infusion and taken to the angiography suite the next morning for diagnostic and therapeutic cerebral angiography, central venography, and mechanical thrombectomy. Angiography was performed after selective catheterization of both common carotid arteries. The bilateral angiographic transit time was markedly prolonged. Multiple tortuous cortical venous collaterals were identified draining from the frontal and anterior parietal regions into the cavernous sinus and retrograde through the superior ophthalmic veins. A deep and prolonged parenchymal blush was observed, consistent with venous hypertension. A sinus venogram was then performed

TABLE 1. Patient presentation^a

Patient no.	Age (yr)/sex	Interval between presentation and treatment (d)	Presentation	GCS at presentation	Hemorrhage	Indication for intervention	Deficit at follow-up	Possible associated condition
1	38/F	4	HA, SZ, mild aphasia, left hemiplegia, right hemiparesis	13	Yes	Severe neurological deficit	None	Oral contraceptives, Factor V leiden
2	28/F	8	HA, SZ, anomic aphasia	14	Yes	Deterioration on antithrombotic therapy	None	Oral contraceptives
3	30/M	0	LOC	3T	Yes	Severe neurological deficit	Dead	Ulcerative colitis
4	67/F	1	Coma	7	No	Severe neurological deficit	None	Diabetic hyperosmolar coma

^a GCS, Glasgow Coma Scale; HA, headache; SZ, seizure; LOC, loss of consciousness.

TABLE 2. Distribution of thrombosed sinuses^a

Patient no.	Thrombosed sinuses
1	SSS
2	L-TSS
	L-IJ
3	SSS
	B-TSS
	B-IJ
	ICVs
	SS
4	SSS
	L-TSS

^a SSS, superior sagittal sinus; L, left; TSS, transverse sigmoid sinus; IJ, internal jugular vein; B, bilateral; ICVs, internal cerebral veins; SS, straight sinus.

before the thrombectomy that demonstrated a multiseptated occlusion in the anterior half of the SSS with a widely patent posterior half (Fig. 1A). The transverse sinuses were patent bilaterally at this point, in conflict with the preliminary MRV suggestion. After preprocedure images were obtained, an AngioJet XMI catheter was advanced to the level of the coronal suture until resistance was felt. The thrombectomy mechanism was activated and pulled through the thrombosed segment. Post-thrombectomy angiography demonstrated an improved angiographic transit time with disappearance of the aberrant cortical venous collateral drainage into the cavernous sinus. Central venography demonstrated evacuation of thrombus from the SSS with improved contrast transit throughout the venous sinuses (Fig. 1B). A simultaneous pulmonary angiogram was performed at the time of the intervention, which demonstrated bilateral pulmonary emboli. The patient tolerated the procedure well and was taken to the NICU on a continued heparin infusion.

She was extubated on postprocedure Day 3 and was oriented and following commands. Her motor function continued to improve and she was discharged home on postprocedure Day 9 after conversion to oral Coumadin (DuPont Pharmaceuticals, Wilmington, DE). Laboratory evaluations demonstrated the patient to be heterozygous for Factor V leiden. In addition, at the time of the event, the patient was taking oral contraceptives. At the time of the 6-month follow-up examination, the patient had made a complete neurological recovery without recurrence of symptoms.

Patient 2

A 28-year-old woman presented with a 2-day history of headache, which progressed to confusion and speech arrest. She was taken to an outside hospital, where she developed a tonicoclonic seizure. A computed tomographic scan demonstrated a small acute parenchymal hemorrhage in the posterior left temporal lobe and marked edema within the left temporo-occipital lobe. She was then transferred to our institution for further management. Upon arrival, she was confused and somnolent, obeying commands intermittently. An MRI scan and MRV were performed, confirming the diagnosis of thrombosis of the left transverse sinus, left sigmoid sinus, and proximal left internal jugular vein, with venous infarction involving the left temporal and parietal lobes, as well as associated hemorrhage involving the medial left temporal lobe.

The patient was admitted to the NICU and placed on IV heparin. On her sixth day of hospitalization, and while being converted to

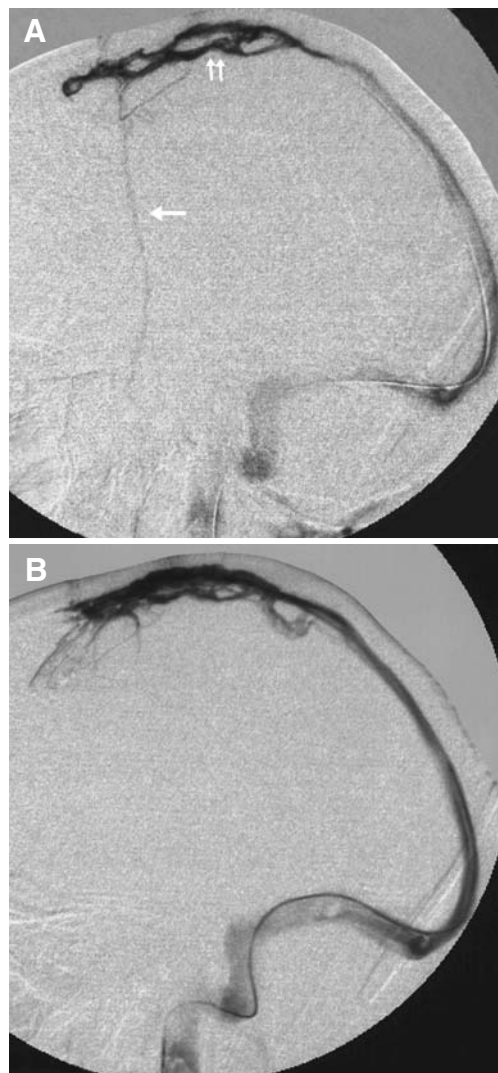


FIGURE 1. A, central venogram performed through a microcatheter positioned within the anterior third of the SSS demonstrating near complete sinus occlusion with a tiny amount of contrast streaming around a large lucent filling defect (double arrows) within the anterior aspect of the sinus. There is also retrograde cortical venous drainage over the frontal lobes (arrow). B, after rheolytic thrombectomy, the thrombus within the anterior sinus was almost completely evacuated. The anterior sinus filled with contrast, which rapidly flowed antegrade into the transverse-sigmoid system. No cortical venous reflux was observed after thrombectomy. Right common carotid angiography performed after thrombectomy also demonstrated a marked improvement in the angiographic transit time.

Coumadin, she developed a sudden onset of severe headache. Computed tomographic scans, MRI scans, and MRV were performed and demonstrated an increase in the volume of the left temporal lobe hematoma and the surrounding vasogenic edema (Fig. 2, A and B). The patient was taken to the angiography suite for digital subtraction angiography and mechanical thrombectomy.

Digital subtraction angiography demonstrated a prolonged parenchymal phase and angiographic transit time. Venous drainage

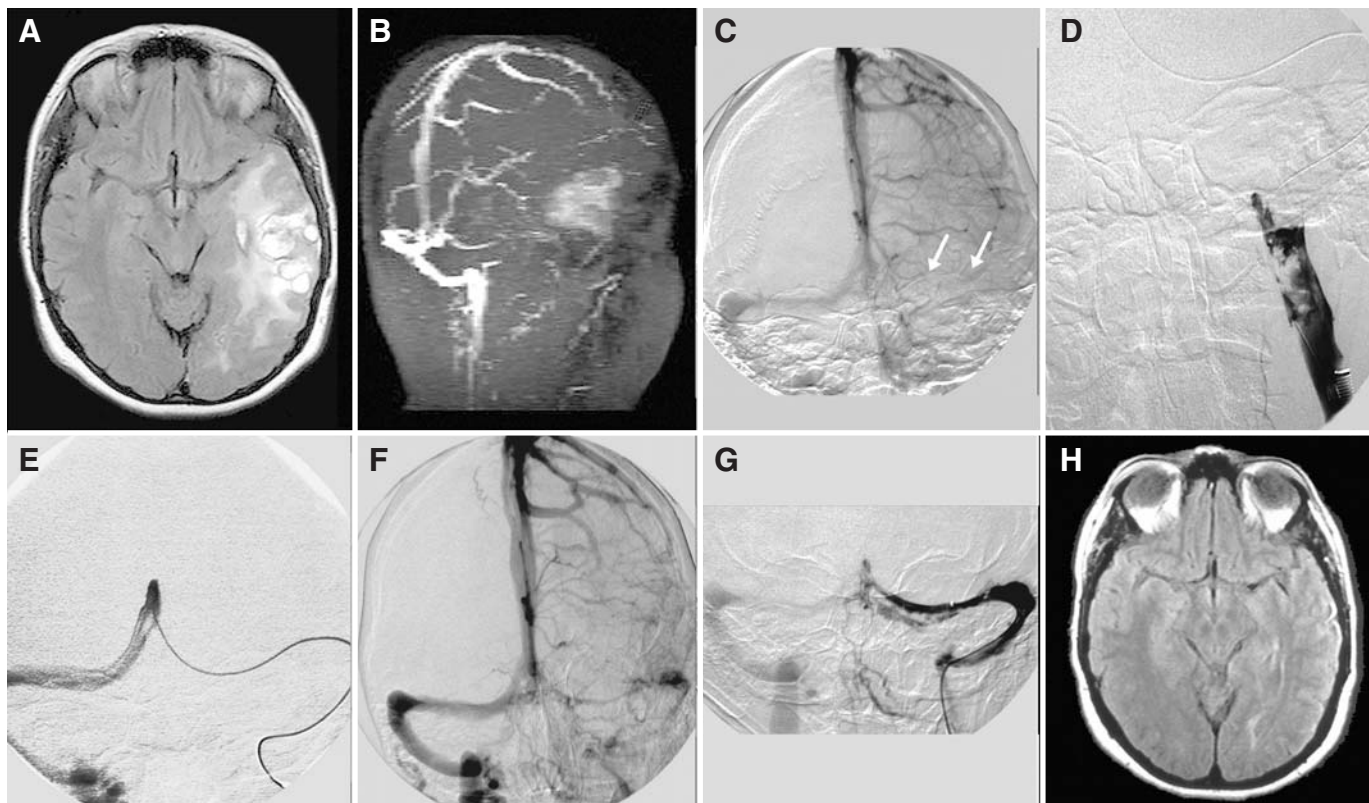


FIGURE 2. A, axial fluid attenuation inversion recovery MRI scan demonstrating hemorrhage and edema distributed throughout the left temporal lobe. B, reconstructed maximal intensity projection of the two-dimensional MRV source data depicting complete occlusion of the left transverse sigmoid system. Hyperintensity within the region of the left temporal lobe represents "shine-through" from the large T1-weighted hyperintense hematoma. C, venous phase of an angiogram performed from a catheter positioned within the left internal carotid artery demonstrating complete occlusion of the left transverse-sigmoid system (arrows). Prolonged and intense cortical venous opacification is evident over the left cerebral hemisphere. D, venogram performed through an 8-French guiding sheath positioned within the left internal jugular vein demonstrating a large, irregular thrombus extending into the jugular bulb and distal jugular vein. E, venogram performed through a

microcatheter positioned within the torcula demonstrating venous drainage only through the right transverse-sigmoid system. F, cerebral angiography performed through a catheter positioned within the left internal carotid artery after successful rheolytic thrombectomy depicting restored patency of the left transverse sigmoid system. With the restoration of venous outflow, the angiographic transit time returned to normal. Fewer large cortical veins persist into the late venous phase when compared with the prethrombectomy angiogram (C). G, central venogram from a microcatheter positioned within the left mid-transverse sinus confirming sinus patency with a residual filling defect within the inferior aspect of the distal transverse sinus and torcula. H, axial fluid attenuation inversion recovery image from a 3-month follow-up MRI scan demonstrating complete resolution of hemorrhage and edema within the left temporal lobe.

was exclusively through the SSS and right transverse-sigmoid system (Fig. 2C). Central venography performed before the thrombectomy, demonstrated occlusion of the left transverse-sigmoid system and jugular vein (Fig. 2, D and E). An AngioJet XMI catheter was advanced to the level of the torcula, the thrombectomy mechanism was activated, and the catheter was pulled through the thrombosed segments of the transverse-sigmoid system to the internal jugular vein, resulting in partial recanalization. The XMI thrombectomy catheter was exchanged for an AngioJet Xpedior thrombectomy catheter which was used to complete the thrombectomy of the jugular bulb and sigmoid sinus.

Post-thrombectomy angiography demonstrated an improvement in transit time and patency of the transverse-sigmoid systems bilaterally (Fig. 2F). Central venography confirmed partial recanalization of the left transverse-sigmoid with antegrade flow through to the jugular vein (Fig. 2G). The patient tolerated the procedure well and was taken to the NICU for recovery and maintained on a heparin infusion.

She was converted to oral Coumadin therapy and discharged from the hospital 6 days after the procedure was performed. At the time of her discharge, she was neurologically intact, with the exception of subtle cognitive impairment manifest as occasional difficulty with calculations and word finding. At the time of the 1-month follow-up examination, she had returned to her neurological baseline and was free of seizures. Follow-up MRI scans obtained at 3 months after the procedure demonstrated resolution of right temporal lobe edema and hemorrhage with minimal encephalomalacia (Fig. 2H)

DISCUSSION

Treatment of Sinus Thrombosis

Anticoagulation with heparin is the treatment of choice for the vast majority of patients with central venous sinus throm-

bosis (Fig. 3). In a small, randomized trial comparing IV heparin therapy with placebo, the beneficial effects of heparin were so profound that the study was terminated early. Heparin not only improved the odds of achieving a full neurological recovery, but also reduced the risk of death (8). A second trial evaluating the efficacy of low molecular weight heparin demonstrated a trend toward improved outcome and reduced parenchymal hemorrhage. However, neither end point reached statistical significance (3). Frey et al. (5) reported the successful restoration of flow in nine out of 12 patients after direct intrathrombus infusion of tissue plasminogen activator (tPA) in combination with IV heparin. However, in the three patients in whom flow was not restored, two demonstrated worsening of parenchymal hemorrhage. Frey et al. (5) concluded that direct tPA infusion may be unsafe in patients with overt parenchymal hemorrhage on imaging. Thus, in patients presenting with treatable headache alone or patients with stable focal neurological symptoms and hemorrhage, IV heparin represents the best available first-line therapy.

Patients with progressive neurological symptoms despite adequate anticoagulation, those who present with a precipitous neurological deterioration, and those who present with refractory headache without hemorrhage do not fit into the above treatment algorithm. In this relatively uncommon subset of CVT patients, a more aggressive strategy of endovascular intervention is warranted to restore sinus patency. In the absence of hemorrhage, these patients are generally treated with transfemoral direct intra-thrombus tPA infusion therapy. However, if the presentation of these patients is complicated by hemorrhage or if the neurological decline is precipitous, tPA infusion therapy becomes a less favorable option because of the risk of exacerbating the underlying hemorrhage as well as the prolonged duration of therapy (24–48 h) that is often required to restore sinus patency.

The Role of the AngioJet in Central Venous Sinus Thrombosis

Recently, there have been several case reports in the literature in which a combina-

tion of the AngioJet rheolytic thrombectomy catheter with direct microcatheter thrombolysis has been used for the treatment of dural sinus thrombosis, resulting in an accelerated recanalization of the occluded sinuses and cerebral veins (2, 4, 10, 12). The mechanical evacuation of thrombus from the sinuses not only decreases the overall clot burden that must be lysed, but also restores venous flow, overcoming the pro-coagulant environment perpetuated by venous stasis. Despite the practical benefits of this therapeutic strategy, the concomitant usage of fibrinolytic agents raises serious questions regarding the safety of this strategy in patients presenting with parenchymal hemorrhage. In one report of two cases, the operators observed an increase in parenchymal hemorrhage and intraventricular hemorrhage despite successful rheolytic thrombectomy achieved with adjunctive intra-arterial tPA and heparin (2).

In the current series, three of the four patients treated with systemic heparinization and adjuvant mechanical rheolytic thrombectomy had excellent angiographic and clinical outcomes. In these patients, the restoration of flow within the dural venous sinuses produced an immediate improvement in angiographic transit time, despite the presence of some residual

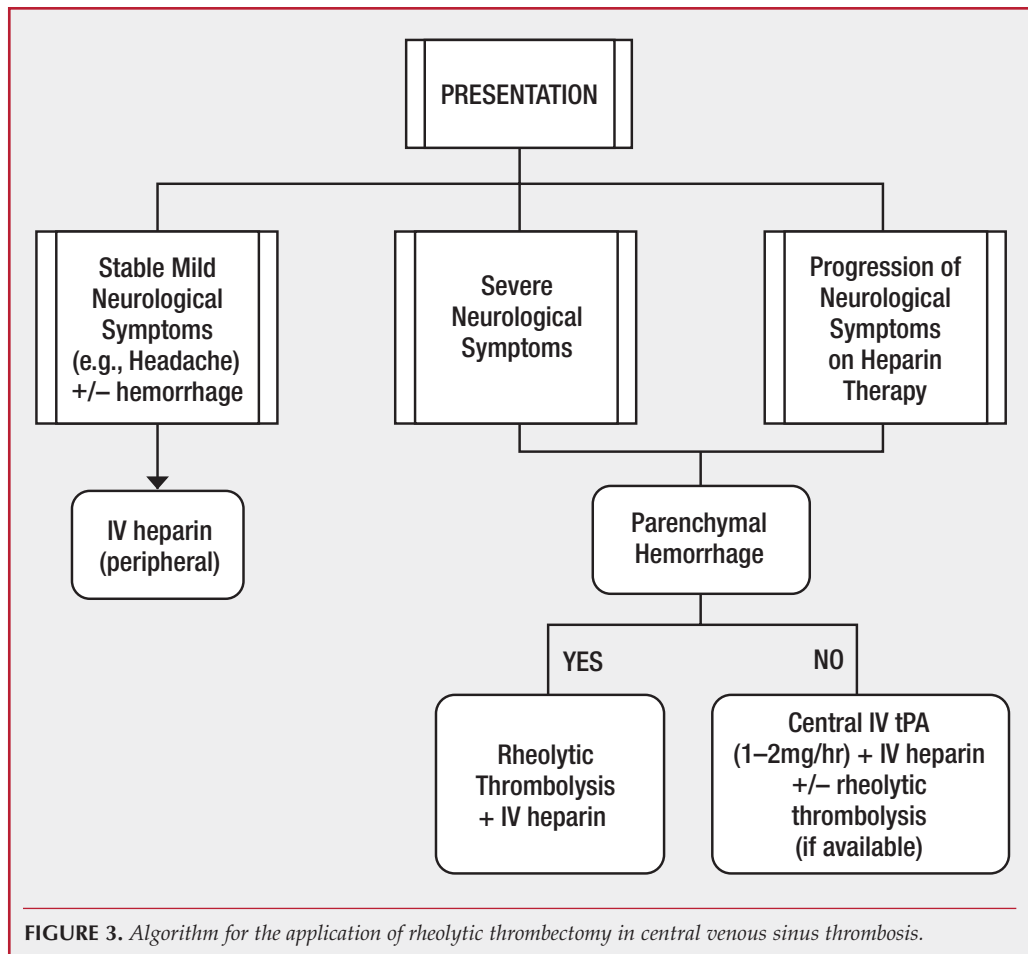


FIGURE 3. Algorithm for the application of rheolytic thrombectomy in central venous sinus thrombosis.

nonocclusive thrombus within the treated sinuses and cortical veins. The flow restoration and concomitant heparinization function not only prevent recurrent thrombosis, but also promote an environment that allows the inherent physiological fibrinolytic mechanisms to restore full patency to the cortical veins and venous sinuses.

The patient who failed to improve (Patient 3) had a malignant neurological presentation with thrombosis of all of the dural venous sinuses as well as the deep venous systems (Table 1). In this patient, a large volume of thrombus was distributed within the cortical veins and within the deep system and was, thereby, inaccessible to the AngioJet. Despite rheolytic evacuation of a large volume of thrombus from the dural sinuses, the angiographic transit time failed to significantly improve. In such patients who demonstrate no improvement in angiographic transit time after rheolytic thrombectomy and are clinically deteriorating on IV heparin therapy, the risks of a tPA infusion may outweigh the benefits.

Technical Considerations

The AngioJet device uses high-velocity saline jets to create a Bernoulli effect to remove the thrombus. It has been demonstrated to be minimally traumatic to vascular endothelia. Additionally, the venous sinuses are surrounded by resistant dura mater, which makes the procedure safer. On the other hand, limitations of the use of the catheter include its size and rigidity, which make it difficult to negotiate within the intracranial circulation.

Several studies have demonstrated procedural success with the rheolytic thrombectomy catheter in patients presenting with acute myocardial infarction for thrombus-containing coronary lesions, extensive deep venous thrombosis, acute limb-threatening ischemia, and thrombosed grafts in hemodialysis patients (6, 7, 9, 11, 13, 14). Disadvantages of the AngioJet system include the cost of the equipment and the risk of hemolysis and fluid overload (6).

CONCLUSIONS

The current series demonstrates that revascularization of occluded dural venous sinuses with AngioJet rheolytic thrombectomy and IV heparin therapy is an effective treatment for central venous sinus thrombosis in selected patients. The adjunctive application of the AngioJet decreases the overall clot burden and restores flow, thereby establishing an environment that promotes physiological fibrinolytic activity and the reestablishment of cerebral venous patency. This strategy is particularly useful in neurologically unstable CVT patients presenting with intracranial hemorrhage, a scenario in which other endovascular treatments have an adverse risk profile and take longer to work.

REFERENCES

1. Bousser MG: Cerebral venous thrombosis: Nothing, heparin, or local thrombolysis? *Stroke* 30:481-483, 1999.

2. Chow K, Gobin YP, Saver J, Kidwell C, Dong P, Viñuela F: Endovascular treatment of dural sinus thrombosis with rheolytic thrombectomy and intra-arterial thrombolysis. *Stroke* 31:1420-1425, 2000.
3. deBrujin SF, Stam J: Randomized, placebo-controlled trial of anticoagulant treatment with low-molecular-weight heparin for cerebral sinus thrombosis. *Stroke* 30:484-488, 1999.
4. Dowd CF, Malek AM, Phatouros CC, Hemphill JC 3rd: Application of a rheolytic thrombectomy device in the treatment of dural sinus thrombosis: A new technique. *AJNR Am J Neuroradiol* 20:568-570, 1999.
5. Frey JL, Muro GJ, McDougall CG, Dean BL, Jahnke HK: Cerebral venous thrombosis: Combined intrathrombus rTPA and intravenous heparin. *Stroke* 30:489-494, 1999.
6. Kasirajan K, Gray B, Ouriel K: Percutaneous AngioJet thrombectomy in the management of extensive deep venous thrombosis. *J Vasc Interv Radiol* 12:179-185, 2001.
7. Kasirajan K, Gray B, Beavers FP, Clair DG, Greenberg R, Mascha E, Ouriel K: Rheolytic thrombectomy in the management of acute and subacute limb-threatening ischemia. *J Vasc Interv Radiol* 12:413-421, 2001.
8. Kimber J: Cerebral venous sinus thrombosis. *QJM* 95:137-142, 2002.
9. Kuntz RE, Baim DS, Cohen DJ, Popma JJ, Carrozza JP, Sharma S, McCormick DJ, Schmidt, DA, Lansky AJ, Ho KK, Dandreo KJ, Setum CM, Ramee SR: A trial comparing rheolytic thrombectomy with intracoronary urokinase for coronary and vein graft thrombus (The Vein Graft AngioJet Study [VeGAS 2]). *Am J Cardiol* 89:326-330, 2002.
10. Opatowsky MJ, Morris PP, Regan JD, Mewborn JD, Wilson JA: Rapid thrombectomy of superior sagittal sinus and transverse sinus thrombosis with a rheolytic catheter device. *AJNR Am J Neuroradiol* 20:414-417, 1999.
11. Rinfret S, Katsiyannis PT, Ho KK, Cohen DJ, Baim DS, Carrozza JP, Laham RJ: Effectiveness of rheolytic coronary thrombectomy with the AngioJet catheter. *Am J Cardiol* 90:470-476, 2002.
12. Scarrow AM, Williams RL, Jungreis CA, Yonas H, Scarrow MR: Removal of a thrombus from the sigmoid and transverse sinuses with a rheolytic thrombectomy catheter. *AJNR Am J Neuroradiol* 20:1467-1469, 1999.
13. Singh M, Tiede DJ, Mathew V, Garratt KN, Lennon RJ, Holmes DR Jr, Rihal CS: Rheolytic thrombectomy with AngioJet in thrombus-containing lesions. *Catheter Cardiovasc Interv* 56:1-7, 2002.
14. Topaz O, Perin EC, Jesse RL, Mohanty PK, Carr M Jr, Rosenschein U: Power thrombectomy in acute ischemic coronary syndromes. *Angiology* 54:457-468, 2003.
15. Zhang Z, Long J, LI W: Cerebral venous sinus thrombosis: A clinical study of 23 cases. *Chinese Med J (Engl)* 113:1043-1045, 2000.

Acknowledgments

This study was previously presented as a poster at the 2003 Joint Annual Meeting of the AANS/CNS Section on Cerebrovascular Surgery and the American Society of Interventional and Therapeutic Neuroradiology.

COMMENTS

The authors used mechanical thrombectomy/thrombolysis catheters to achieve impressive recanalization of thrombosed dural sinuses in four patients. A positive clinical outcome was obtained in three of the four patients.

Dural sinus thrombosis occurs most commonly in young women and is frequently associated with pregnancy, the postpartum period, and the use of oral contraceptives. However, numerous other predisposing factors exist. Genetic coagulation factor abnormalities, such as Factor V leiden, protein C, protein S, and antithrombin 3, must be excluded. The diagnosis of dural sinus thrombosis continues to be missed regularly. An excellent, large case series was previously reported in *Neurosurgery* (10), and I recommend that the interested reader review it. When diagnosing a patient, one should always remember to examine the missed areas on cranial computed tomographic or magnetic resonance imaging scans, including the orbits, the dural and air sinuses, and the foramen magnum (the edges of the film).

In the English-language literature, I found 18 cases of mechanical thrombectomy for dural sinus thrombosis (1, 3, 4, 6, 7, 9, 10). There are several reported cases in which mechanical thrombectomy was performed by inserting the catheter directly into the sinus via a cranial burr hole (2). The female-to-male ratio is more than 3:1; the average age at onset is approximately 38 years. Clinical presentation varied, but there were common symptoms and signs of seizures, including headache, focal neurological deficits, and, in some cases, decreased or deteriorating levels of consciousness. Thrombosis of the superior sagittal sinus was always present, as was thrombosis of other sinuses, most commonly one or both transverse sinuses, the sigmoid sinus, and the straight sinus. Remarkably good outcomes were achieved; 14 of the patients reported in the literature had good outcomes, two had moderate disability, one had severe disability, and there was one death.

The authors present a reasonable algorithm for the treatment of patients with dural sinus thrombosis. The standard treatment is anticoagulation, the use of which was supported by a Cochrane review (11). Direct infusion of thrombolytic agents or mechanical dissolution of the thrombi are generally used in the subset of patients who are deteriorating despite anticoagulation; the former is used if there is no intracranial hemorrhage. Another Cochrane review of thrombolytic drugs for dural sinus thrombosis found no Level 1 evidence to support the use of these drugs and suggested performing a randomized trial, which would be a difficult undertaking for such a rare disease (5). Devices are improving and changing, and new drugs, such as the platelet G2b/3a receptor inhibitors, are being developed (8). Series of patients should continue to be reported as they will provide the best evidence for treatment of these cases.

R. Loch Macdonald
Chicago, Illinois

1. Baker MD, Opatowsky MJ, Wilson JA, Glazier SS, Morris PP: Rheolytic catheter and thrombolysis of dural venous sinus thrombosis: A case series. *Neurosurgery* 48:487-494, 2001.
2. Chaharvi A, Steinmetz MP, Masaryk TJ, Rasmussen PA: A transcranial approach for direct mechanical thrombectomy of dural sinus thrombosis. Report of two cases. *J Neurosurg* 101:347-351, 2004.
3. Chaloupka JC, Mangla S, Huddle DC: Use of mechanical thrombolysis via microballoon percutaneous transluminal angioplasty for the treatment of acute dural sinus thrombosis: Case presentation and technical report. *Neurosurgery* 45:650-657, 1999.
4. Chow K, Gobin YP, Saver J, Kidwell C, Dong P, Viñuela F: Endovascular treatment of dural sinus thrombosis with rheolytic thrombectomy and intra-arterial thrombolysis. *Stroke* 31:1420-1425, 2000.
5. Ciccone A, Canhao P, Falcao F, Ferro JM, Sterzi R: Thrombolysis for cerebral vein and dural sinus thrombosis. *Cochrane Database Syst Rev* CD003693, 2004.
6. Dowd CF, Malek AM, Phatouros CC, Hemphill JC 3rd: Application of a rheolytic thrombectomy device in the treatment of dural sinus thrombosis: A new technique. *AJNR Am J Neuroradiol* 20:568-570, 1999.
7. Opatowsky MJ, Morris PP, Regan JD, Mewborne JD, Wilson JA: Rapid thrombectomy of superior sagittal sinus and transverse sinus thrombosis with a rheolytic catheter device. *AJNR Am J Neuroradiol* 20:414-417, 1999.
8. Qureshi AI, Luft AR, Sharma M, Guterman LR, Hopkins LN: Prevention and treatment of thromboembolic and ischemic complications associated with endovascular procedures: Part 1—Pathophysiological and pharmacological features. *Neurosurgery* 46:1344-1359, 2000.
9. Scarrow AM, Williams RL, Jungreis CA, Yonas H, Scarrow MR: Removal of a thrombus from the sigmoid and transverse sinuses with a rheolytic thrombectomy catheter. *AJNR Am J Neuroradiol* 20:1467-1469, 1999.
10. Soleau SW, Schmidt R, Stevens S, Osborn A, MacDonald JD: Extensive experience with dural sinus thrombosis. *Neurosurgery* 52:534-544, 2003.
11. Stam J, De Bruijn SF, DeVeber G: Anticoagulation for cerebral sinus thrombosis. *Cochrane Database Syst Rev* CD002005, 2002.

Central venous sinus thrombosis (CVST) is a rare condition that can present with venous hypertension, venous infarction, parenchymal hemorrhage, severe neurological deficits, and a malignant course. Anticoagulation with heparin is the standard treatment for most patients with CVST, even those with hemorrhage and mild focal neurological deficits. Fibrinolytic agents, such as tissue plasminogen activator, can be infused directly into the thrombus; however, these agents must be administered slowly and are contraindicated with parenchymal hemorrhage. Rheolytic mechanical thrombectomy with the AngioJet (Possis Medical, Minneapolis, MN) is an alternative to fibrinolytics in some cases of progressive deterioration with hemorrhage or precipitous deterioration. The AngioJet avoids fibrinolytics, lowers clot volume, and can restore blood flow in the occluded sinus. The favorable clinical results observed by the authors in three of their four patients demonstrates its efficacy; however, the less favorable case indicates that there is more to treating CVST than simply re-establishing venous flow. The device itself is large, stiff, and not easily maneuvered; however, it remains a useful tool in the management of this difficult disease.

Michael T. Lawton
San Francisco, California

Kirsch et al. describe their experience using the AngioJet device for mechanical thrombectomy for central venous sinus thrombosis in four patients. There is no question that the outcome can be quite disastrous when this syndrome behaves in a malignant fashion. With the advent of intravenous thrombolytics delivered systemically and endovascularly, the hemorrhagic conversion rate seems to be quite problematic. This device obviates the need for additional thrombolytics but uses systemic heparinization. Unfortunately, this device is rigid and stiff, which is a technical problem that can be resolved. I think this device has significant utility in this regard; the authors' experience indicates that it is very effective when used to treat CVST. One of the most compelling reasons to use this device is that it obviates the need for urokinase or 2B3A inhibitors, which carry a significant hemorrhagic complication rate for venous infarction.

Robert H. Rosenwasser
Philadelphia, Pennsylvania

In a landmark, randomized placebo-controlled study published in *The Lancet* in 1991, Einhaupl et al. (5) demonstrated that heparin therapy was greatly superior to placebo for the treatment of CVST. Despite the inclusion of just 20 patients, the statistical benefit was so profound that the trial was stopped early. A retrospective review of that data, focusing on heparin therapy in patients with intracerebral hemorrhage, also demonstrated a clear statistical benefit (5). More recently, de Bruijn et al. (3), using fractionated heparin as a bridge to warfarin therapy, were not able to statistically establish a benefit for low-molecular weight heparin (nadroparin) but did demonstrate that intracerebral hemorrhage should not be an exclusion factor. At most centers that treat CVST, unfractionated heparin remains the first line of treatment in patients with symptomatic CVST, even when hemorrhage occurs. However, the question remains of how to treat those patients in whom heparin therapy fails.

Kirsch et al. present a series of four patients with CVST who have experienced either precipitous decline while on heparin therapy or severe neurological deficit unresponsive to heparin therapy and who underwent systemic heparinization and intrasinus rheolytic therapy. Excellent results were achieved in three of the four patients; one patient who presented with a Glasgow Coma Scale score of 3 died.

Three of the four patients experienced intracerebral hemorrhage. The use of a rheolytic catheter for sinus thrombosis was initially reported by Dowd et al. (4) in 1999. However, most authors have used the technique in conjunction with thrombolytics (1, 2, 4). Kirsh et al. argue that their technique with heparin alone is safer and should be the standard of care. It is likely that there will never be a large enough number of patients with CVST in whom heparin therapy fails and interventional techniques are required to perform a randomized trial to determine the safety and efficacy of rheolysis with or without thrombolytics. It is easy to find successful cases of rheolysis and thrombolytics (1, 2, 4). However, if Grade 2 Thrombolysis in Myocardial Infarction flow is established with rheolysis, it is useful to know that heparin alone can be efficacious.

Finally, in the second case presented, the patient developed a severe headache. It is reported that noninvasive imaging demonstrated an increase in the volume of the left temporal lobe hematoma and the surrounding vasogenic edema. The patient was taken to the angiography suite for digital subtraction angiography and mechanical thrombectomy. In most neurosurgical environments, this situation portends going to the operating room. *Figure 2A* demonstrates left uncal herniation secondary to the hematoma and surrounding edema. Remarkably, however, this patient had a good outcome. In the setting of sinus thrombosis, the venous edema clearly surpassed the hemorrhage. By achieving a Grade 2 thrombolysis in myocardial infarction flow, the authors prevented further herniation. In a conscious patient with a headache, this is a more feasible and, most likely, superior strategy than the operative removal of the hematoma. However, in a patient with herniation, operative evacuation and postoperative heparin therapy within 24 hours, with or without rheolysis, may prove to be life saving.

Robert D. Ecker
Okinawa, Japan
L. Nelson Hopkins
Buffalo, New York

-
1. Chow K, Gobin YP, Saver J, Kidwell C, Dong P, Viñuela F: Endovascular treatment of dural sinus thrombosis with rheolytic thrombectomy and intra-arterial thrombolysis. *Stroke* 31:1420–1425, 2000.
 2. Curtin KR, Shaibani A, Resnick SA, Russell EJ, Simuni T: Rheolytic catheter thrombectomy, balloon angioplasty, and direct recombinant tissue plasminogen activator thrombolysis of dural sinus thrombosis with preexisting hemorrhagic infarctions. *AJNR Am J Neuroradiol* 25:1807–1811, 2004.
 3. de Bruijn SF, Stam J: Randomized, placebo-controlled trial of anticoagulant treatment with low-molecular-weight heparin for cerebral sinus thrombosis. *Stroke* 30:484–488, 1999.
 4. Dowd CF, Malek AM, Phatouros CC, Hemphill JC 3rd: Application of a rheolytic thrombectomy device in the treatment of dural sinus thrombosis: A new technique. *AJNR Am J Neuroradiol* 20:568–570, 1999.

5. Einhaupl KM, Villringer A, Meister W, Mehraein S, Garner C, Pellkofer M, Haberl RL, Pfister HW, Schmiedek P: Heparin treatment in sinus venous thrombosis. *Lancet* 338:597–600, 1991.

The authors describe the use of mechanical thrombectomy using the AngioJet Rheolytic Thrombectomy System in four patients with dural venous sinus thrombosis who presented with either severe neurological deficits (n = 3) or deterioration (n = 1) despite anticoagulation. The authors were able to achieve partial reperfusion in all patients with no procedural complications. The results were excellent, with three out of four patients showing marked improvement; the fourth patient continued to deteriorate and subsequently died.

The authors then describe the role of this device in the treatment of CVST as follows: 1) for stable patients with no intraparenchymal hemorrhage, heparin should be administered; 2) for progressive patients with no intraparenchymal hemorrhage, antithrombotic therapy should be administered; and 3) for progressive patients with intraparenchymal hemorrhage, mechanical thrombolysis with AngioJet therapy should be administered.

The results reported by Kirsch et al. are comparable to those of the International Study on Cerebral Vein and Dural Sinus Thrombosis (1), in which 79% of 624 patients recovered and 8% died after various treatments, including anticoagulation in 83% of patients. Given the excellent results of this small study, one could ask the following questions: 1) wouldn't patients with major venous sinus thrombosis, even if they were doing reasonably well, be better off with restoration of sinus flow?, 2) wouldn't heparin be more effective and safer if venous hypertension were removed from the equation?, and 3) wouldn't the rapid restoration of flow be superior to antithrombotics and also have lower periprocedural hemorrhage risks?

If the device is used within a dural sinus, its safety seems to be high. Based on the outcomes described in this report, this technology could conceivably be applied as the first-line treatment in patients who demonstrate progressive neurological deficits despite heparinization or those presenting with a precipitous neurological deterioration. Conversely, despite how promising the results seem, the small size of this series prevents a meaningful statistical analysis and comparison with anticoagulation therapy alone. The authors should consider a future randomized trial with a larger cohort.

Rose Du
Arthur L. Day
Boston, Massachusetts

-
1. Ferro JM, Canhao P, Stam J, Boussier MG, Barinagarrementeria F; ISCVT Investigators: Prognosis of cerebral vein and dural sinus thrombosis: Results of the International Study on Cerebral Vein and Dural Sinus Thrombosis (ISCVT). *Stroke* 35:664–670, 2004.