

## HYPERBARIC OXYGEN IN THE TREATMENT OF A RADIOSURGICAL COMPLICATION: TECHNICAL CASE REPORT

### Michael Lynn, M.D.

Department of Neurosurgery,  
University of Florida,  
Gainesville, Florida

### William A. Friedman, M.D.

Department of Neurosurgery,  
University of Florida,  
Gainesville, Florida

### Reprint requests:

William A. Friedman, M.D.,  
P.O. Box 100265, MBI,  
Department of Neurosurgery,  
University of Florida,  
Gainesville, FL 32610.  
Email: friedman@neurosurgery.ufl.edu

Received, August 14, 2006.

Accepted, November 10, 2006.

**OBJECTIVE:** Hyperbaric oxygenation is a rarely used method of treatment for steroid-refractory radiation-induced edema after stereotactic radiosurgery. We present its successful implementation for a radiosurgical complication after the treatment of a deep, large arteriovenous malformation. We also review the literature on hyperbaric oxygenation for radiation-induced complications.

**CLINICAL PRESENTATION:** A 25-year-old man underwent radiosurgical treatment for a large arteriovenous malformation. Three years later, substantially smaller remaining nidus was retreated. Five months after that treatment, the patient developed edema around the nidus and hemiparesis. This problem was refractory to high-dose steroids.

**INTERVENTION:** The patient underwent a course of 25 hyperbaric oxygenation treatments. Within 1 month, the edema and hemiparesis had improved, allowing steroids to be tapered. A follow-up examination 1 year later revealed complete thrombosis of the arteriovenous malformation and minimal neurological deficit.

**CONCLUSION:** This technical case report adds to the few studies in the literature suggesting that hyperbaric oxygenation therapy, in conjunction with a slow steroid taper, is a reasonable addition to the treatment armamentarium for radiation-induced cerebral edema associated with clinically evident neurological deficits.

**KEY WORDS:** Arteriovenous malformation, Hyperbaric oxygen, Radiosurgery

*Neurosurgery* 60:E579, 2007

DOI: 10.1227/01.NEU.0000255343.41206.6F

www.neurosurgery-online.com

Surgical excision, endovascular embolization, stereotactic radiosurgery, or a combination of all three modalities are well-established treatment options for cerebral arteriovenous malformations (AVMs) (14). The morbidity of open surgical techniques is higher for deep AVMs located in eloquent brain. Radiosurgery may be a particularly attractive option for such lesions (6).

Causes of postradiosurgery deficits have been well documented. After stereotactic radiosurgery, patients are at continued risk for hemorrhage and a small percentage experience radiation-induced brain injury (16). This case report reviews the radiosurgical treatment of a young patient with a large, deep AVM complicated by symptomatic radiation-induced edema. Resolution of his symptoms followed the introduction of an infrequently used treatment method, hyperbaric oxygen. A review of the literature follows.

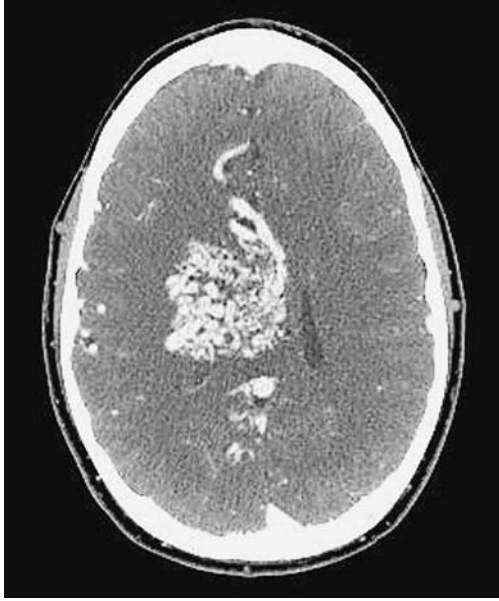### CASE REPORT

This 25-year-old man was referred to the Department of Neurosurgery at the University of Florida, Gainesville, Florida

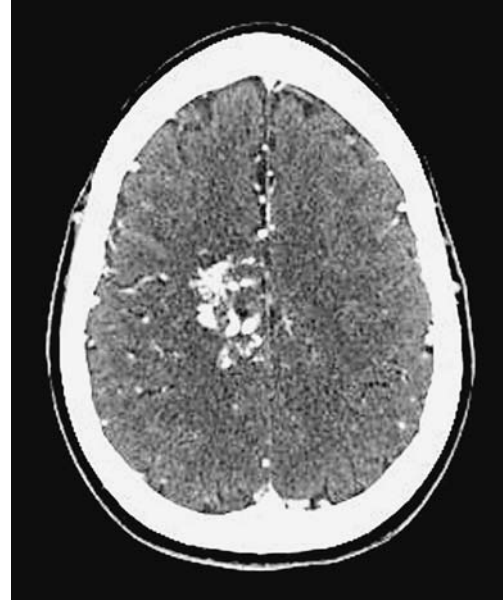for evaluation of an AVM. He presented with intermittent bilateral hand tremors, frequent "sinus headaches," and trouble with his memory. The patient did not have a significant medical history, and the results of his neurological examination were entirely normal. Computed tomographic (CT) scans (Fig. 1) and angiography (Fig. 2, A and B) revealed a Spetzler-Martin Grade IV AVM (17). The nidus was 4 cm in maximal diameter and was centered in the deep right hemisphere with partial drainage to the right internal cerebral vein.

The patient underwent stereotactic radiosurgery using the University of Florida radiosurgical system (13). He received a 1500 cGy dose to the 70% isodose line using eight isocenters. The 12-Gy volume treated was 56.5 cm<sup>3</sup> and the treatment volume was 41.8 cm<sup>3</sup>. Magnetic resonance imaging (MRI) scans of the brain revealed an approximate 50% reduction in the size of the AVM at the 1-year follow-up examination; further reduction was observed after 2 years.

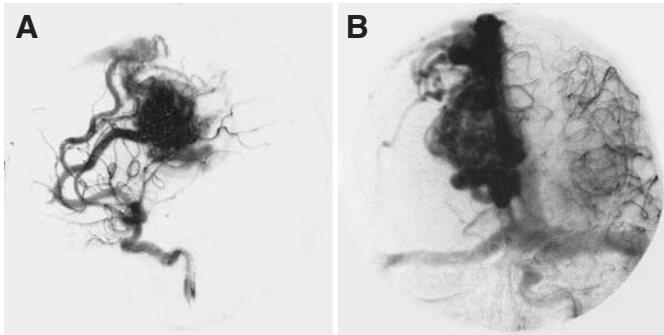
An MRI scan performed during the 3-year follow-up evaluation showed residual AVM. The patient underwent radiosurgical retreatment (5, 7) 39 months after his first treatment



**FIGURE 1.** Stereotactic contrast enhanced axial CT scan performed for treatment planning before the patient's first radiosurgical treatment.



**FIGURE 3.** Stereotactic contrast-enhanced axial CT scan performed for treatment planning before the patient's second radiosurgical treatment. The nidus is significantly smaller than at the time of the first treatment.



**FIGURE 2.** Diagnostic lateral (A) and anteroposterior (B) angiograms obtained before radiosurgery showing a large AVM nidus.

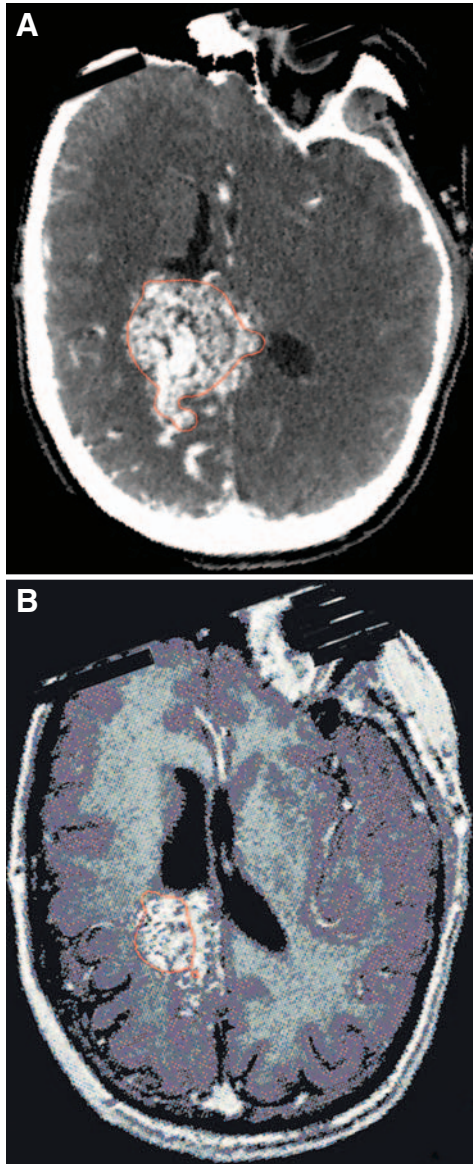
(Fig. 3). He received a 1750 cGy dose to the 70% isodose line using six isocenters. The 12-Gy volume treated was 18.2 cm<sup>3</sup> and the treatment volume was 9.6 cm<sup>3</sup> (Fig. 4). Five months later, the patient presented with new-onset seizures and left hemiparesis. Although a CT scan demonstrated further reduction in AVM nidal volume, it also showed a considerable amount of new surrounding edema, consistent with radiation-induced changes (Fig. 5). He began steroid treatment (4 mg of Decadron [Merck & Co., Inc., Whitehouse Station, NJ] orally every 6 h) but his left hemiparesis persisted. One month later, he commenced a series of 25 consecutive hyperbaric oxygenation (HBO) dives with concurrent steroid treatment. After completion of his HBO, a Decadron taper was completed. Results of an MRI scan demonstrated complete resolution of any surrounding edema and thrombosis of the AVM 1 year after the radiosurgical treatment. His hemiparesis had nearly resolved.

Angiographic confirmation of complete AVM cure was obtained (Fig. 6).

## DISCUSSION

Radiosurgical treatment of AVMs is not without risks, including hemorrhage and radiation damage to the surrounding parenchyma. Several publications have correlated the 12-Gy treatment volume to radiographic evidence of radiation-associated changes. For a large 12-Gy treatment volume of 56.5 cm<sup>3</sup>, Flickinger et al. (2) observed a 42.4% rate of imaging changes, whereas 10% of treated patients were found to experience neurological deficits. The patient's second treatment targeted a 12-Gy volume of 18.2 cm<sup>3</sup>, which yielded identical observed rates of imaging changes as well as observed rates of neurological deficits. Symptomatic radiographic changes can be predicted based on AVM location and 12-Gy treatment volumes (3, 4). Friedman et al. (8) also reported that larger 12-Gy volumes increased the risk of transient neurological changes. Previous hemorrhage had a protective effect in a report published by Karlsson et al. (10).

A search of the literature confirms that there is very little experience with the use of HBO for radiation-associated cerebral edema. HBO is used in the treatment of decompression sickness (the bends) in deep-sea divers, in radiation-induced bone and soft tissue necrosis, to enhance survival of full-thickness skin flaps, and to reduce the adverse effects of acute ischemic stroke (15). In damaged tissues, HBO will raise pO<sub>2</sub> and possibly potentiate cellular repair mechanisms and promote angiogenesis. It is of utmost importance to note that at least 1 hour of HBO is required at adequate pressures (two



**FIGURE 4.** Stereotactic treatment planning 70% isodose line (red outline) images. A, CT scan performed for initial treatment (41.8 cm<sup>3</sup>). B, MRI scan performed for retreatment (9.6 cm<sup>3</sup>).

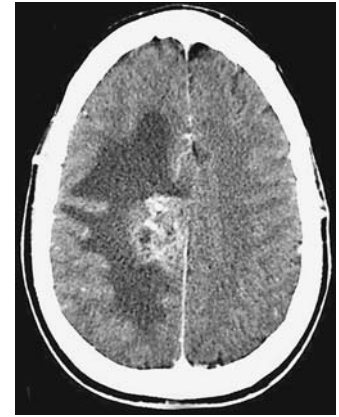absolute atmospheres) to saturate venous blood as measured in the right atrium and that an additional 30 minutes are required for saturation of peripheral soft tissues (20).

Leber et al. (12) reported two patients who experienced post-operative imaging signs of radionecrosis after gamma knife radiosurgery for AVMs. They received 40 cycles of 1-hour HBO treatments without adjuvant steroids. In one patient, there was complete resolution of the imaging changes; the second patient showed significant improvement. Kohshi et al. (11) published a case of the resolution of radiation necrosis after two stereotactic radiosurgery treatments for a solitary metastatic renal cell

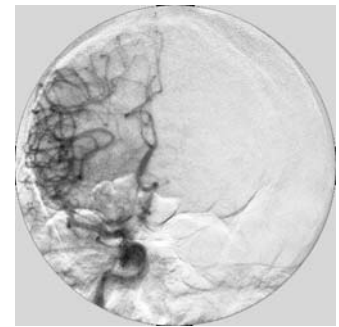
carcinoma to the cerebellum. The patient was initially treated with steroids, which did not improve his symptoms. He was then treated with HBO and experienced full improvement. Takenaka et al. (18) reported successful HBO treatment after resection of necrotic tissue in a patient with multiple cerebral cavernous malformations. Finally, Chuba et al. (1) described HBO therapy in a series of 10 children, eight of whom had biopsy-confirmed necrosis after radiotherapy or radiosurgery. Nine of the children treated had histological diagnoses of brain tumors, and one was treated for necrosis and edema causing motor weakness after radiosurgery for an AVM. This patient initially improved with HBO but required reoperation for edema with mass effect.

In the setting of symptomatic radiation-induced cerebral edema, treatment options have included administration of steroids, anticoagulation (9), and surgical resection of necrotic tissue. To our knowledge, this technical case report adds to the limited literature suggesting that HBO therapy, in conjunction with a slow steroid taper, is a reasonable addition to the treatment armamentarium for radiation-induced cerebral edema associated with clinically evident neurological deficits. The sparse literature supporting the use of HBO in radiosurgical complications mostly report the treatment of radiation-induced brain necrosis, not edema alone. However, the persistence of neurological deficit even after steroid treatment, not radiographic evidence of edema or necrosis alone, led to the clinical application of HBO treatment. After failing steroid treatment, whether radiation-induced edema or radiation-induced necrosis is the basis of the persistent symptomatology, we support the use of HBO.

Although HBO treatment facilities are not widespread, according to the Undersea and Hyperbaric Medical Society's Directory of Hyperbaric Treatment Chambers published in 2005, there are at least 510 facilities in the United States. The cost of an individual treatment session is approximately US \$300 to \$400 for 90 minutes (19).



**FIGURE 5.** Contrast-enhanced axial CT scan obtained 5 months after the second radiosurgical treatment showing edema around the residual AVM.



**FIGURE 6.** Angiogram obtained 1 year after the completion of the patient's HBO treatments showing complete obliteration of the AVM nidus.



## REFERENCES

- Chuba PJ, Aronin P, Bhambhani K, Eichenhorn M, Zamarano L, Cianci P, Muhlbauser M, Porter AT, Fontanesi J: Hyperbaric oxygen therapy for radiation-induced brain injury in children. *Cancer* 80:2005–2012, 1997.
- Flickinger JC, Kondziolka D, Maitz AH, Lunsford LD: Analysis of neurological sequelae from radiosurgery of arteriovenous malformations: How location affects outcome. *Int J Radiat Oncol Biol Phys* 40:273–278, 1998.
- Flickinger JC, Kondziolka D, Pollock BE, Maitz AH, Lunsford LD: Complications from arteriovenous malformation radiosurgery: Multivariate analysis and risk modeling. *Int J Radiat Oncol Biol Phys* 38:485–490, 1997.
- Flickinger JC, Kondziolka D, Lunsford LD, Pollock BE, Yamamoto M, Gorman DA, Schomberg PJ, Sneed P, Larson D, Smith V, McDermott MW, Miyawaki L, Chilton J, Morantz RA, Young B, Jokura H, Liscak R: A multi-institutional analysis of complication outcomes after arteriovenous malformation radiosurgery. *Int J Radiat Oncol Biol Phys* 44:67–74, 1999.
- Foote KD, Friedman WA, Ellis TL, Bova FJ, Buatti JM, Meeks SL: Salvage retreatment after failure of radiosurgery in patients with arteriovenous malformations. *J Neurosurg* 98:337–341, 2003.
- Friedman WA: Radiosurgery versus surgery for arteriovenous malformations: The case for radiosurgery. *Clin Neurosurg* 45:18–20, 1999.
- Friedman WA, Bova FJ: Linear accelerator radiosurgery for arteriovenous malformations. *J Neurosurg* 77:832–841, 1992.
- Friedman WA, Bova FJ, Bollampally S, Bradshaw P: Analysis of factors predictive of success or complications in arteriovenous malformation radiosurgery. *Neurosurgery* 52:296–308, 2003.
- Glantz MJ, Burger PC, Friedman AH, Radtke RA, Massey EW, Schold SC Jr: Treatment of radiation-induced nervous system injury with heparin and warfarin. *Neurology* 44:2020–2027, 1994.
- Karlsson B, Lax J, Soderman M: Factors influencing the risk for complications following Gamma Knife radiosurgery of cerebral arteriovenous malformations. *Radiother Oncol* 43:275–280, 1997.
- Kohshi K, Imada H, Nomoto S, Yamaguchi R, Abe H, Yamamoto H: Successful treatment of radiation-induced brain necrosis by hyperbaric oxygen therapy. *J Neurol Sci* 209:115–117, 2003.
- Leber KA, Eder HG, Kovac H, Anegg U, Pendl G: Treatment of cerebral radionecrosis by hyperbaric oxygen therapy. *Stereotact Funct Neurosurg* 70 [Suppl 1]:229–236, 1998.
- Meeks SL, Bova FJ, Friedman WA, Buatti JM, Mendenhall WM: Linac scalp radiosurgery at the University of Florida. *Med Dosim* 23:177–185, 1998.
- Morgan MK: Classification and decision making in treatment and perioperative management, including surgical and radiosurgical decision making, in Winn HR (ed): *Youmans Neurological Surgery*. Philadelphia, WB Saunders Co., 2003, ed 5, pp 2185–2204.
- Nighoghossian N, Trouillas P, Adeleine P, Salord F: Hyperbaric oxygen in the treatment of acute ischemic stroke: A double-blind pilot study. *Stroke* 26:1369–1372, 1995.
- Pollock BE: Occlusive hyperemia: A radiosurgical phenomenon? *Neurosurgery* 47:1178–1184, 2000.
- Spetzler RF, Martin NA: A proposed grading system for arteriovenous malformations. *J Neurosurg* 65:476–483, 1986.
- Takenaka N, Imanishi T, Sasaki H, Shimazaki K, Sugiura H, Kitagawa Y, Sekiyama S, Yamamoto M, Kazuno T: Delayed radiation necrosis with extensive brain edema after gamma knife radiosurgery for multiple cerebral cavernous malformations—Case report. *Neurol Med Chir (Tokyo)* 43:391–395, 2003.
- Tibbles PM, Edelsberg JS: Hyperbaric oxygen therapy. *N Engl J Med* 334:1642–1648, 1996.
- Wells CH, Goodpasture JE, Horrigan DJ, Hart GB: Tissue gas measurements during hyperbaric oxygen exposure, in Smith G (ed): *Proceedings of the Sixth International Congress on Hyperbaric Medicine*. Aberdeen, Aberdeen University Press, 1979, pp 118–124.

## COMMENTS

Lynn and Friedman review the case of a patient who underwent a second course of radiosurgery for a large arteriovenous malformation (AVM) that failed to obliterate after the first course of radiosurgery. Five months after the second treatment, the patient developed radiation edema refractory to steroid therapy. The patient received 25 courses of hyperbaric oxygen (HBO) therapy and showed both radiographic and symptomatic improvement. Overall, with the aid of HBO, the patient had an excellent outcome with obliteration of a complicated AVM. I think the use of HBO after radiosurgery is underutilized. It is important for neurosurgeons to consider this option for patients who are experiencing systematic radiation edema or radiation necrosis and who are failing high-dose steroid therapy. I have had several patients experience significant improvement after HBO therapy, including one patient with radiation necrosis to the thoracic spine after spinal radiosurgery. It may be possible that using HBO therapy in the early course of radiation necrosis could reduce the overall complications for patients.

Steven D. Chang  
Stanford, California

In this brief report, the authors describe a patient with a large volume AVM who developed adverse radiation effects after a second radiosurgical procedure was performed. Obliteration was achieved for this large AVM, which was located in an area of critical brain function. The risk of such adverse radiation effects seems clearly related to the volume and dose delivered. It is less clear whether or not flow and other angioarchitecture features influence the risk. It is also likely that perhaps 4% of patients may be more sensitive to radiation than others, although we do not currently have a way to detect such patients in advance. We begin with steroids at a dose that may possibly be higher than the ubiquitous neurosurgical dose of 16 mg of dexamethasone per day. Some patients respond to a higher dose; however, 2 weeks of steroid usage is a reasonable trial, after which we switch to Vitamin E 400IU twice per day and trental 400 mg twice per day. If there is incomplete benefit, a trial of HBO may be considered. Although HBO access is generally feasible in most environments, the cost for HBO is enormous and is often not reimbursed by insurance agencies. This report provides additional credence to the concept that HBO should be considered in selected steroid refractory cases. For patients who can tolerate it, HBO has a low risk in experienced centers.

L. Dade Lunsford  
Pittsburgh, Pennsylvania

This case report documents the nearly complete resolution of a radiation-related hemiparesis after repeat radiosurgery of a large AVM. It was informative in providing specific information on the duration (25 sessions lasting 90 minutes each) and cost (approximately US \$7500–10,000) of HBO therapy. The authors were correct to pursue further treatment for this patient's steroid refractory deficit because the long-term consequences of high-dose corticosteroid treatment are substantial. Although we have also found surgical resection of the obliterated nidus to be an effective method for treating this problem, HBO therapy offers a less invasive alternative that is likely to be less expensive than surgical removal.

Bruce E. Pollock  
Rochester, Minnesota