

Ischemic stroke complicating pediatric cardiovascular disease

Adam Kirton* and Gabrielle deVeber

SUMMARY

Background After a year of unsuccessful treatment for hypertension, a young boy underwent a stenting procedure for aortic hypoplasia and awoke with hemiparesis and language deficits.

Investigations Neuroimaging, echocardiography, craniocervical vascular imaging and prothrombotic testing.

Diagnosis Procedure-related acute arterial ischemic stroke and malignant cerebral edema with herniation.

Management Anticoagulation with heparin, seizure prophylaxis and neuroprotective care, including external cooling for hyperthermia. Medical management of increased intracranial pressure and hemicraniectomy at 48 h for malignant cerebral edema. Treatment of deep vein thrombosis with inferior vena cava filter was also required. Long term treatments included extensive rehabilitation, aspirin, antiepileptics, antidyskinetics, antidepressants, antihypertensives and cosmetic skull reconstruction.

KEYWORDS arterial ischemic stroke, cardiac catheterization, hemicraniectomy, pediatric stroke

CME

Vanderbilt Continuing Medical Education online

This article offers the opportunity to earn one Category 1 credit toward the AMA Physician's Recognition Award.

THE CASE

A heart murmur was detected in a healthy, active 11-year-old left-handed boy. Echocardiography demonstrated mild hypoplasia of the transverse aortic arch (pressure gradient 33–38 mmHg). The boy had no cardiac symptoms, hypertension or ventricular hypertrophy. One year later he developed hypertension and was started on low dose atenolol. This treatment failed over the following year and, with increasing pressure gradients, intervention was deemed necessary. Catheterization of the femoral vein and artery with heparin infusion were performed, with placement to both the descending aorta and the aortic arch via a trans-septal route. Tubular hypoplasia, from the left carotid artery to distal to the left subclavian, was confirmed. Two stents were placed in the arch, one just proximal to the origin of the left carotid artery. An excellent reduction in the pressure gradient was achieved without complication. The right carotid artery was not cannulated. The patient was maintained on heparin throughout the procedure, with prolonged partial thromboplastin time post-procedure.

Upon awaking from the procedure, a left hemiparesis was appreciated. Emergent neurological consultation documented a drowsy, irritable boy with dysarthria, expressive dysphasia and left hemianopsia. A moderate left sided hemiparesis affecting face and arm was seen and the left toe was upgoing. No other cranial nerve or sensory deficits were appreciated.

A CT scan completed 45 min later demonstrated subtle hypodensities in the right basal ganglia and cerebral cortex, suggestive of early ischemia in the middle cerebral artery territory (Figure 1A). The patient was last seen well over 3 h earlier so intravenous thrombolytic therapy was excluded. Intra-arterial thrombolysis was not

A Kirton is a Clinical Research Fellow of the American Academy of Neurology Foundation and Alberta Heritage Foundation for Medical Research, and a Pediatric Neurologist and Research Fellow in the SickKids Children's Stroke Program. G deVeber is Director of the SickKids Children's Stroke Program at the Hospital for Sick Children, and Associate Professor of Pediatrics, and Population Health Scientist at the University of Toronto, Toronto, ON, Canada.

Correspondence

*Children's Stroke Program, Division of Neurology, Hospital for Sick Children, 555 University Avenue, Toronto, ON M5G 1X8, Canada
adam.kirton@sickkids.ca

Received 7 July 2006 Accepted 18 October 2006

www.nature.com/clinicalpractice
doi:10.1038/npcardio0825

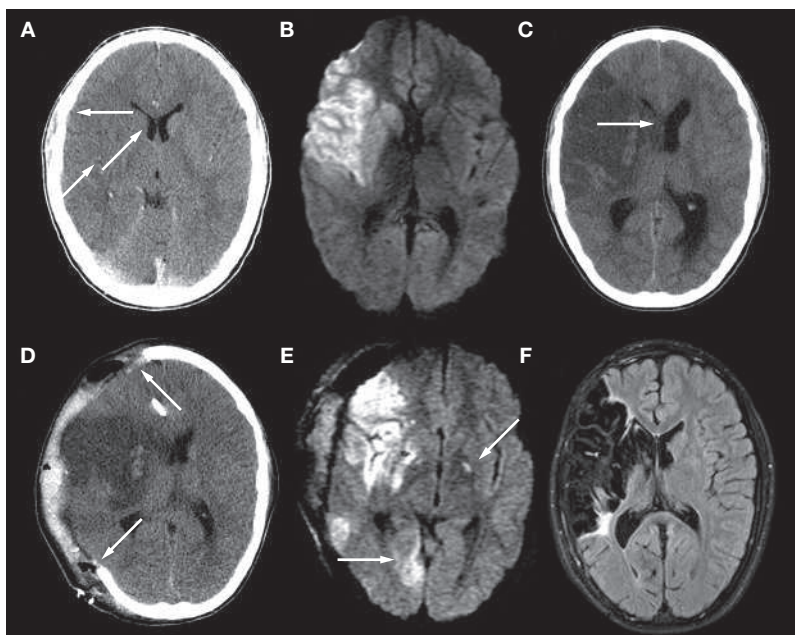


Figure 1 Evolution of ischemic stroke complicating cardiac catheterization in a boy with aortic hypoplasia. (A) A CT head scan done 90 min from onset of symptoms demonstrates subtle loss of signal in the caudate and lentiform nuclei and loss of cortical grey–white differentiation. (B) Diffusion-weighted MRI 60 min later confirms infarction in the right middle cerebral artery territory. (C) A head CT at 36 h showing marked cerebral edema with midline shift (arrow) requiring (D) decompressive craniotomy. (E) Repeat diffusion-weighted MRI at 72 h shows new infarcts including the left globus pallidus and right occipital lobes (arrows). (F) Fluid-Attenuated Inversion Recovery MRI 3 years later shows encephalomalacia and gliosis of the infarcted areas.

pursued for reasons that included well evolved infarction on CT, difficulty in reaccessing the right carotid within 6 h, and the complete lack of evidence for this therapy in children. MRI 1 h after the CT scan confirmed arterial ischemic stroke (AIS) involving a large portion of the middle cerebral artery territory (Figure 1B). Vascular imaging could not be completed because of patient motion.

Anticoagulation with unfractionated heparin infusion (20 units/kg/h, no bolus) was initiated. Neuroprotective care included maintenance of normal to mildly elevated glucose levels, blood pressure and normothermia, which required antibiotics and external cooling. Prophylactic anticonvulsants were given. At around 40 h the patient developed worsening headaches and vomiting. Examination demonstrated papilloedema and a dilated, unreactive right pupil. Evolving malignant cerebral edema was diagnosed on the basis of CT evidence obtained 24 h earlier (Figure 1C). Before emergent hemi-craniectomy was performed, the patient received

mannitol and 3% saline, and protamine for reversal of anticoagulation (Figure 1D). Repeat MRI on day 5 demonstrated evolution of the previous infarction, as well as the development of new areas of infarction (Figure 1E). These included a right occipital lobe AIS, likely to be secondary to compression of the posterior cerebral artery during the herniation episode. Another infarct in the left globus pallidus suggested ongoing thromboembolism from a proximal source; however, echocardiography and magnetic resonance angiography of the arch and neck vessels was normal.

The young man remained in hospital for another month, incurring multiple complications including pneumonia and deep vein thrombosis that required placement of an inferior vena cava filter. He was discharged to the rehabilitation facility where he improved over the next 6 months. The bone flap was replaced with mild cosmetic deformity. He was maintained on both low molecular weight heparin (enoxaparin, 1 mg/kg/day) and aspirin (3–5 mg/kg/day). No other risk factors for stroke were identified, and prothrombotic testing was negative. His language improved markedly and was close to normal at hospital discharge. While his weakness improved to a moderate disability, a severe dystonic posturing of the left extremities developed at 6 months, progressing into a major disability resistant to multiple treatments. Depression was diagnosed and he continues on antidepressant medication. The final extent of brain damage can be demonstrated by MRI (Figure 1F).

DISCUSSION OF DIAGNOSIS

Stroke has emerged as an important cause of brain injury in children. An incidence of 2–8 cases per 100,000 children per year is comparable to pediatric brain malignancy.¹ AIS is defined as an acute neurological deficit with neuroimaging confirmation of infarction in an arterial territory. Pediatric AIS has a varied clinical presentation and complex differential diagnosis, but the acute onset of a focal neurological deficit in proximity to a cardiovascular procedure should be considered as AIS until proven otherwise. A high index of suspicion is required from physicians, as infants often do not demonstrate focal neurological deficits. Stroke diagnosis is confirmed by neuroimaging, and the availability of diffusion-weighted MRI and noninvasive vascular imaging has greatly improved its recognition. Outcomes are generally poor

following a stroke: morbidities of hemiparesis, cognitive and language delays, and epilepsy occur in the majority of patients, and there is substantial mortality.² Excellent general reviews of pediatric stroke are available for further reading.¹

Many risk factors have been suggested for childhood AIS, including acute and chronic diseases, infection or inflammation, prothrombotic states, congenital syndromes and vascular disorders.³ While many children harbor multiple risk factors, another 20–30% are idiopathic. An extensive investigational approach is, therefore, required. In the context of the presented case, the role of cardiac disease in pediatric stroke is discussed in more detail.

Cardiac diseases are among the most consistently identified risk factors for childhood AIS, being associated with 10–30% of cases.^{3,4} Population-based data of over 1,000 children with AIS found cardiac disease in 28%,⁵ the majority of whom had complex congenital heart disease (CHD). Over 40% of strokes, however, occurred in association with cardiac surgery or catheterization. Case–control data from over 5,500 children undergoing cardiac procedures indicate an incidence of vaso-occlusive stroke of approximately 1 in 200, with reoperation procedures carrying the highest risk.⁶

The pathophysiology of cardiac related strokes is often unclear. Thromboemboli can occur secondary to structural and flow abnormalities arising from areas of poor wall motion, sites of endothelial injury, catheters or bypass machinery. Certain structural arrangements, such as single ventricle physiology, increase this risk, as do procedures such as the Fontan procedure^{4,7} or balloon atrial septostomy in transposition of the great arteries.⁸ Strokes can also occur in the preoperative period and in these cases are often clinically silent.⁹ Stroke may complicate as many as 1 in 200–400 interventional procedures.^{4,10} Population-based data indicate that approximately 20% of strokes in children with CHD occur in relation to catheterization.⁵ Endothelial injury and thromboembolism is often presumed, although our patient did not have the right carotid artery cannulated and vascular imaging was normal.

Although CHD lesions are most common, cardiomyopathy, valvular disease, endocarditis, arrhythmia and ventricular dysfunction should also be considered as AIS risks. The need for extracorporeal membrane oxygenation further increases stroke risk.¹¹ Right-to-left shunting

carries a risk of paradoxical AIS secondary to venous thrombosis. Patent foramen ovale is common in children, although the actual stroke risk it imparts is currently under debate.

TREATMENT AND MANAGEMENT

Therapeutic approaches to stroke in children are evolving but lack empirical evidence.¹² Acute thrombolytic therapy was strongly considered because of our patient's age, proximity to catheterization, and significant deficit. While the successful use of thrombolytics in children has been described anecdotally,¹² the complete lack of evidence warrants great consideration before this therapy is undertaken, and safety studies are required.

Consensus-based guidelines support the use of anticoagulation in acute childhood stroke.¹³ This approach is supported by differences in pediatric stroke risk factors and mechanisms, but lacks evidence from randomized clinical trials. Other acute neuroprotective strategies to minimize secondary brain injury include attention to normalization of blood pressure, blood sugar and body temperature, as well as aggressive treatment of seizures and infection.¹²

Recurrence rates for pediatric stroke are substantial, estimated at 10–25%, and may be increased with concomitant cardiac disease.¹⁴ Evidence for secondary stroke prevention in children with cardiac disease is lacking, though guidelines agree that aspirin can provide some protection.^{13,15} Aspirin could also be primarily protective in certain circumstances, such as in patients with functional single ventricles undergoing Fontan procedures.⁷ High risk populations, such as children with CHD, will be the target of upcoming secondary prevention trials.

Although recommendations on the timing of emergent decompressive craniectomy in children with stroke are limited by minimal experience, the effectiveness shown here suggests this option should be seriously considered in cases of malignant cerebral edema.

CONCLUSION

This case illustrates the crucial need for improved recognition and study of AIS in pediatric cardiovascular patients. Further study will allow cardiovascular interventionalists and pediatric neurologists to better understand mechanisms, provide risk estimates, and develop preventive strategies to reduce the poor outcomes suffered by most children.

Competing interests

The authors declared they have no competing interests.

References

- 1 Lynch JK (2004) Cerebrovascular disorders in children. *Curr Neurol Neurosci Rep* **4**: 129–138
- 2 deVeber G *et al.* (2000) Neurologic outcome in survivors of childhood arterial ischemic stroke and sinovenous thrombosis. *J Child Neurol* **15**: 316–324
- 3 Ganesan V *et al.* (2003) Investigation of risk factors in children with arterial ischemic stroke. *Ann Neurol* **53**: 167–173
- 4 Kirkham FJ (1998) Recognition and prevention of neurological complications in pediatric cardiac surgery. *Pediatr Cardiol* **19**: 331–345
- 5 Canadian Paediatric Ischemic Stroke Study Group (2006) Arterial ischemic stroke in Canadian children [abstract]. *Ann Neurol* **60**: S148
- 6 Domi T *et al.* (2002) Frequency and predictors of vasoocclusive strokes associated with congenital heart disease. *Ann Neurol* **52 (Suppl)**: S129–S133
- 7 Barker PC *et al.* (2005) Risk factors for cerebrovascular events following fontan palliation in patients with a functional single ventricle. *Am J Cardiol* **96**: 587–591
- 8 McQuillen PS *et al.* (2006) Balloon atrial septostomy is associated with preoperative stroke in neonates with transposition of the great arteries. *Circulation* **113**: 280–285
- 9 Miller SP *et al.* (2004) Preoperative brain injury in newborns with transposition of the great arteries. *Ann Thorac Surg* **77**: 1698–1706
- 10 Menache CC *et al.* (2002) Current incidence of acute neurologic complications after open-heart operations in children. *Ann Thorac Surg* **73**: 1752–1758
- 11 Wu YW *et al.* (2005) Perinatal arterial stroke: understanding mechanisms and outcomes. *Semin Neurol* **25**: 424–434
- 12 Kirton A and deVeber G (2006) Therapeutic approaches and advances in pediatric stroke. *NeuroRx* **3**: 133–142
- 13 Monagle P *et al.* (2004) Antithrombotic therapy in children: The Seventh ACCP Conference on Antithrombotic and Thrombolytic Therapy. *Chest* **126 (Suppl)**: S645–S687
- 14 Chabrier S *et al.* (2000) Stroke in childhood: outcome and recurrence risk by mechanism in 59 patients. *J Child Neurol* **15**: 290–294
- 15 Paediatric Stroke Working Group (online November 2004) Stroke in childhood: clinical guidelines for diagnosis, management and rehabilitation. [<http://www.rcplondon.ac.uk/pubs/books/childstroke/>] (accessed July 2005)