

Carbamazepine-Induced Eosinophilic Colitis

Veli-Jukka Anttila and Matti Valtonen

Third Department of Medicine, University of Helsinki, Helsinki, Finland

Summary: Severe watery diarrhea and eosinophilic colitis induced by carbamazepine (CBZ) has not been described previously. We report the first known case of CBZ-induced watery diarrhea and eosinophilic colitis in a 57-year-old man receiving CBZ for secondarily general-

ized tonic-clonic seizures that developed after a cerebral infarction. **Key Words:** Epilepsy—Carbamazepine—Drug-induced abnormalities—Eosinophilia—Colitis—Diarrhea.

The most common side effects of carbamazepine (CBZ), currently the most frequently prescribed drug for epilepsy, involve the nervous system. Gastrointestinal side effects are nausea, vomiting, obstipation, and diarrhea, which are usually mild and temporary (Pellock, 1987). We could not find a previous report in the English literature of CBZ-induced severe watery diarrhea and eosinophilic colitis (Anttila and Valtonen, 1990).

CASE REPORT

A 57-year-old man experienced a mild right cerebral infarction in October 1985. A secondarily generalized tonic-clonic epileptic seizure starting in the left hand occurred in October 1986 and recurred in October 1987. The most likely cause of the seizures was the old infarct in the right motor cortex. After the second seizure, carbamazepine (Neurotol Slow, Farnos-Yhtymä, Turku, Finland) at 400 mg twice daily was prescribed to prevent seizures. The serum CBZ level was 31.5 mmol/L (therapeutic level of 20–40 mmol/L). Eight weeks after starting CBZ, the patient visited a health center because of diarrhea, which had lasted for 3 weeks. No other family members or neighbors had diarrhea. The patient had no recent antibiotic treatment nor recent travel abroad. The family history was negative for inflammatory bowel disease, celiac disease, and colonic polyposis. Stool cultures were negative and there were no

parasites. The diarrhea continued and he was referred to Helsinki University Central Hospital on December 11, 1987.

On admission the patient was dry. Pulse rate was 80 beats/min. Abdominal examination showed no hepatosplenomegaly, abdominal tenderness, or masses and there was no evidence of perianal disease. Rectal examination was normal. There were no other significant clinical signs.

After admission, the patient had ten watery loose stools per day. Stool osmolality was not measured. Laboratory data were erythrocyte sedimentation rate (ESR) of 14 mm/h, hemoglobin (Hb) of 181 g/L, white blood cell count of $13.8 \times 10^9/L$ with 68% neutrophils, 25% lymphocytes, and 1% eosinophils, serum creatinine of 156 mmol/L (normal of <115 mmol/L), alanine aminotransferase (ALT) of 375 U/L (normal of 40 U/L), aspartate aminotransferase (AST) of 119 U/L (normal of <40 U/L), and γ -glutamyl transferase of 529 U/L (normal of 6–46 U/L). Urine sediment was normal. Repeated stool examinations were negative for known viral, bacterial, and parasitic enteric pathogens. Serum antibody titers to tested bacterial, viral, and parasitic enteric pathogens were also negative.

Gastroscopy showed some erosion in the ventricle and duodenum. Antral mucosa was microscopically normal. Histological examination of biopsy samples taken from the bulb of the duodenum revealed a nonspecific mild inflammatory reaction. In the colonoscopy, the findings were macroscopically normal. Histological examination of four biopsy samples taken on the whole length of the colon, however, revealed an intense inflammatory mononuclear cell infiltrate within the lamina pro-

Received May 1990; revision accepted September 1990.

Address correspondence and reprint requests to Dr. M. Valtonen at Helsinki University Central Hospital, Third Department of Medicine, 00290 Helsinki, Finland.

pria, which was composed primarily of eosinophils (Fig. 1). The counting of five different high-power fields (HPFs) of each sample revealed average counts of 25–40 eosinophils (mean of 34) per HPF (normal of 8 eosinophils per HPF). There was no subepithelial collagen thickening.

After 1 week, CBZ was stopped. Thereafter, the diarrhea also stopped within a few days. Transaminase levels started to decrease and the serum creatinine level became normal. During a lactose intolerance test, blood sugar levels did not rise, but the patient remained symptomless during the test. The vitamin A absorption test was normal.

Twelve days after stopping CBZ, it was restarted at the same dose. Immediately after the first tablets, the patient started watery diarrhea. The patient refused the second CBZ dose. At that time, it was thought that the diarrhea might be due to other components of the tablets. Therefore, another carbamazepine preparation (Tegretol, Ciba-Geigy, Helsinki, Finland) was started at a smaller dose of 200 mg twice daily. Two days thereafter, the patient was discharged without diarrhea.

At an outpatient visit 2 weeks later, the patient reported that the diarrhea had started immediately after returning home, with several watery loose stools per day. CBZ was stopped and the diarrhea

ceased within 2 weeks. There was no further diarrhea and all laboratory values remained normal. The patient died on April 15, 1988 of acute myocardial infarction at the Helsinki University Central Hospital. No autopsy was performed.

DISCUSSION

Gastrointestinal side effects such as nausea, vomiting, abdominal pain, and diarrhea have been described in the 0–9% of patients with CBZ treatment (Pellock, 1987). Usually, side effects have been mild and temporary and there has been no need to stop treatment. Our patient is the first report of a severe watery diarrhea induced by CBZ. CBZ treatment was started three times in our patient and every time a severe watery diarrhea occurred.

CBZ has been reported to induce eosinophilic inflammations such as lung eosinophilia (Lee et al., 1981; Lewis et al., 1982), eosinophilic cholangitis (Larrey et al., 1987), and erythema multiforme (Meisel and North, 1984). In these cases, patients have also had eosinophilia in peripheral blood. Eosinophils are normally present in small numbers in the lamina propria of the gut mucosa (Blackshaw and Levison, 1986; Moore et al., 1986). However, the intense eosinophilic infiltrate in multiple colon biopsies of our patient is without doubt an abnormal

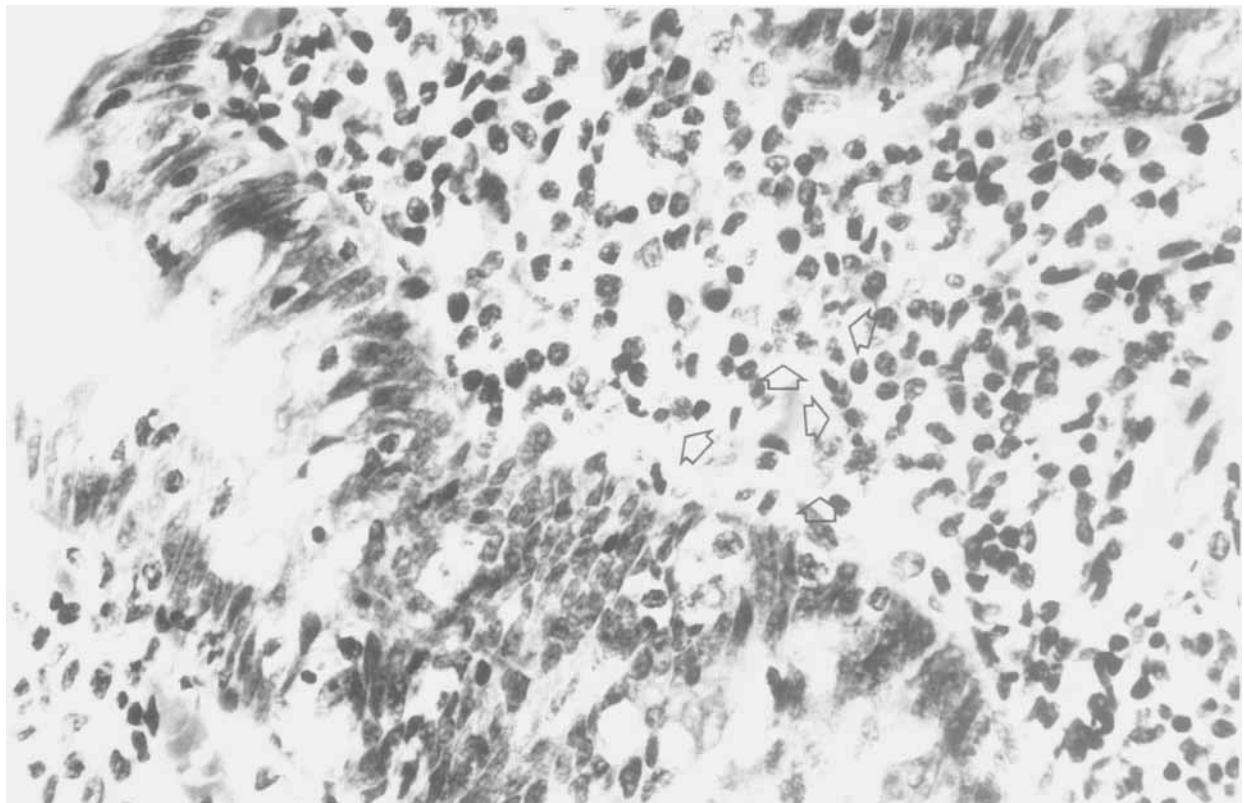


FIG. 1. Microscopic examination ($\times 400$) of the biopsy sample of the colon demonstrating numerous eosinophils (arrows).

finding (Tedesco et al., 1981). Eosinophilic infiltration of the gastrointestinal tract is seen in the systemic hypereosinophilic syndromes, parasitic diseases, inflammatory bowel diseases, and allergic disorders. Most cases are idiopathic. Eosinophilic gastroenteritis usually affects the stomach and small intestine but isolated colonic involvement appears to be quite rare (Moore et al., 1986). In idiopathic gastroenteritis, there are usually other allergic-type reactions and the patients also have eosinophils in peripheral blood (Blackshaw and Levison, 1986). The number of eosinophils in peripheral blood of our patient, however, was normal. There were no infiltrates in his chest radiographs, and no signs of systemic illnesses or parasitic diseases. The repeated episodes of severe watery diarrhea after CBZ readministration strongly suggests CBZ as the cause of the colitis and diarrhea.

Other components of the CBZ tablets were also considered as a possible source of the inflammatory reaction. When changing from the long-acting, more quickly absorbed preparation produced by another manufacturer, the symptoms and signs recurred although somewhat slower than during the first CBZ readministration. These two preparations differ in composition in their lactose content, which is not present in one preparation (manufacturer's information). Therefore, it seems unlikely that these other components would be the reason for the diarrhea and the colitis. CBZ has been reported to induce liver function abnormalities in 5–10% of the patients treated with the drug (Pellock, 1987), as also happened with our patient. The most frequently reported liver function abnormalities have

been the rises in the serum liver enzymes. The changes have usually been mild and reversible, but deaths have also been reported (Horowitz et al., 1988). However, the rise in the serum liver enzyme levels has not been shown to correlate to severe watery diarrhea. The liver enzyme values of our patient do not explain his symptoms.

Our case report strongly suggests that carbamazepine can induce severe watery diarrhea and eosinophilic colitis.

REFERENCES

- Anttila V-J, Valtonen M. Karbamatsepiinin aiheuttama vesiripuli ja eosinofiilinen koliitti. *Duodecim* 1990;106:372–4.
- Blackshaw AJ, Levison DA. Eosinophilic infiltrates of the gastrointestinal tract. *J Clin Pathol* 1986;39:1–7.
- Horowitz S, Patwardhan R, Marcus E. Hepatotoxic reactions associated with carbamazepine therapy. *Epilepsia* 1988;29:149–54.
- Larrey D, Hadenque A, Pessayre D, Choudat L, Degott C, Benhamou J-P. Carbamazepine-induced acute cholangitis. *Dig Dis Sci* 1987;32:554–7.
- Lee TAK, Cochrane GM, Amlot P. Pulmonary eosinophilia and asthma associated with carbamazepine. *Br Med J* 1981;282:440.
- Lewis IJ, Rosenbloom L. Glandular lever-like syndrome, pulmonary eosinophilia and asthma associated with carbamazepine. *Postgrad Med J* 1982;58:100–1.
- Meisel S, North CQ. Carbamazepine-associated erythema multiforme with extreme eosinophilia. *Clin Pharmacol* 1984;3:15–9.
- Moore D, Lichtman S, Lentz J, Stringer D, Sherman P. Eosinophilic gastroenteritis presenting in an adolescent with isolated colonic involvement. *Gut* 1986;27:1219–22.
- Pellock JM. Carbamazepine side-effects in children and adults. *Epilepsia* 1987;28(suppl 3):S64–70.
- Tedesco FJ, Huckaby CB, Hamby-Allen M, Ewing GC. Eosinophilic ileocolitis: expanding spectrum of eosinophilic gastroenteritis. *Dig Dis Sci* 1981;26:943–8.