

Case report

Juvenile Behçet's disease: Highlighting neuropsychiatric manifestations and putative genetic mechanisms

J.N. Panicker^{a,*}, K.P. Vinayan^a, N.V. Ahsan Moosa^a, E.M. Elango^b, A. Anand Kumar^a

^a Department of Neurology, Amrita Institute of Medical Sciences, Kochi 682026, India

^b Department of Molecular Biology, Amrita Institute of Medical Sciences, Kochi, India

Received 12 October 2006; received in revised form 10 January 2007; accepted 12 January 2007

Abstract

Behçet's disease is a multisystem inflammatory disorder of unknown etiology. We report a 12-year-old boy who presented with features of raised intracranial tension and seizures and was found to have cerebral venous sinus thrombosis on evaluation. Behçet's disease was diagnosed based on occurrence of recurrent oral and genital ulcers in the past and characteristic skin lesions subsequently. He also showed significant personality changes including multiple attempts of deliberate self-harm. Pedigree analysis revealed that six family members spanning three generations had recurrent oral ulcers and three members satisfied the criteria for Behçet's disease. Clinical features varied amongst the family members and there was suggestion of genetic anticipation. The index case was carrying HLA-B37/B7 and the mother was carrying B37/B40. Our report sheds light on the genetics of Behçet's disease. Unusual features were early age of onset, cerebral venous sinus thrombosis, significant personality changes and strong family history with phenotypic heterogeneity.

© 2007 Published by Elsevier B.V.

Keywords: Juvenile Behçet's disease; Cerebral venous thrombosis; Personality disturbances; HLA; Genetic anticipation

1. Introduction

Behçet's disease is a multisystem inflammatory disorder of unknown etiology consisting of the triad of recurrent oral and genital ulcerations and hypopyon uveitis. It usually presents in adults and familial disease is uncommon [1,2]. We report a case of juvenile Behçet's disease presenting as cerebral venous sinus thrombosis, with strong family history and discuss the possible genetic basis of this disease.

2. Case report

A 12-year-old boy presented with headache and vomiting of 2-month duration and recurrent seizures for 2 days. This was not associated with visual blurring, double vision, weak-

ness, fever or skin lesions. General examination was normal. Neurological examination revealed a drowsy boy with bilateral papilloedema, without focal deficits or neck stiffness. Systemic examination was normal. He was evaluated on the lines of raised intracranial tension without localization. Magnetic resonance imaging (MRI) of brain parenchyma was normal and venography demonstrated reduced signals in the superior sagittal sinus (Fig. 1), suggestive of venous sinus thrombosis. Heparin and antiseizure medications were initiated. Etiology for cerebral venous sinus thrombosis was evaluated. Haemogram, erythrocyte sedimentation rate, biochemical parameters, vasculitis and thrombophilia work up and cerebrospinal fluid analysis were normal. He had been suffering from recurrent non-scarring oral ulcers from 6 years of age and had 6–8 eruptions per year involving tongue, buccal mucosa and lips. He had been recovering from one such episode at the onset of the presenting illness. He also had recurrent non-scarring genital ulcers and arthralgias. Pathergy test was negative. The month prior to the presenting illness had been characterized by changes in personality including aggressiveness, attention deficit and one attempt of

* Corresponding author. Tel.: +91 484 2801234x1315/2802055; fax: +91 484 2802020.

E-mail addresses: jaleshnpicker@aimshospital.org, jaleshp@hotmail.com (J.N. Panicker).

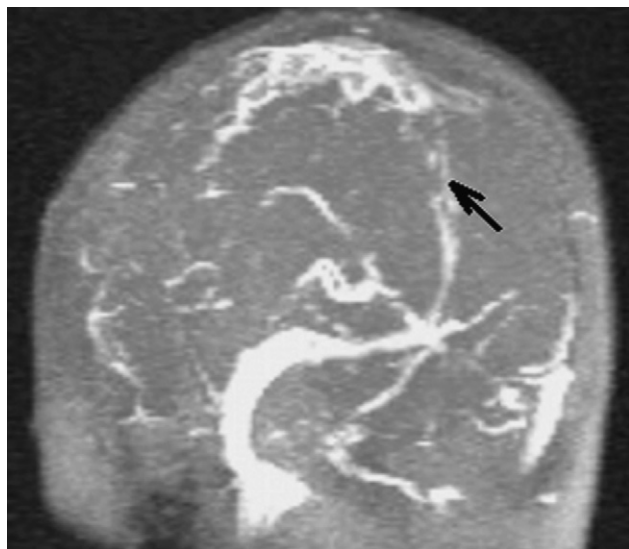


Fig. 1. Magnetic resonance venography, coronal view, showing reduced signals from superior sagittal sinus (arrow), suggestive of venous sinus thrombosis.

deliberate self-harm. Possibility of Behçet’s disease was considered. He recovered fully after a stormy course consisting of recurrent seizures, sepsis and impaired renal functions. After 3 months, he developed transient papulopustular lesions over the fingers and arm. Pathergy test was once again negative. There were no features of uveitis. Recurrent oral and genital ulcers and characteristic skin lesions fulfilled the International Study Group criteria for Behçet’s disease [3]. Pedigree analysis revealed that six members spanning three generations had recurrent oral ulcers (Fig. 2). Four members (II₇, III₅, III₆, III₇) had recurrent genital ulcers and two (II₇, III₆) had arthralgias. Two members had characteristic skin lesions (III₅, III₆) and Pathergy test was positive in one (II₇). Three members of the family satisfied the criteria for Behçet’s disease (II₇, III₅, III₆). Age of onset of oral ulcers was less with subsequent generations; age 40 in generation I, 30 in generation II and five in generation III including the index case, suggesting genetic anticipation. A genetic basis was investigated and the index case (III₆) was found to be carrying

HLA-B37/B7 and mother (II₇) was carrying HLA-B37/B40. At follow up, he developed severe depression and made three further attempts of deliberate self-harm. Symptoms improved with mood stabilizers and counseling.

3. Discussion

Recurrent oral ulcers, genital ulcers and characteristic skin lesions fulfill the International Study Group diagnostic criteria for Behçet’s disease. This case is unique because of the multitude of uncommon features. It also sheds light on the genetic basis of the disease. Juvenile Behçet’s disease, occurring below age 16, occurs in only 1.6–3% of patients and has not been reported from India [1]. Juvenile onset is associated with aggressive disease and higher incidence of neurological involvement and venous thrombosis [1]. Disease evolved gradually in our patient, with recurrent oral and genital ulcers antedating venous thrombosis and cutaneous disease by 6 years, and longitudinal follow up was required for fulfilling the diagnostic criteria of Behçet’s disease [3].

Central nervous system involvement occurs in 10–25% of patients and parenchymal manifestations include brainstem dysfunction, myelopathy and meningoencephalitis. Dural venous sinus thrombosis is the commonest nonparenchymal manifestation and heparin is the mainstay of treatment; role of corticosteroids is controversial and was avoided in our patient because of concomitant sepsis [4–6]. Neuropsychiatric disturbances in Behçet’s disease are uncommon. Depression, anxiety and euphoria have been described and patients show a specific pattern of cognitive deficits characterized by memory impairment and personality changes such as apathy, disinhibition and attention deficit. These disturbances are attributed to white matter and basal ganglia dysfunction, though may not initially be associated with MRI abnormalities [7]. Personality changes in our patient included disinhibition, aggressiveness, attention deficit, depression and repeated attempts of deliberate self-harm. Our patient did not have white matter lesions in MRI and personality changes may have been due to functional disturbances in subcortical frontal lobe circuits [7].

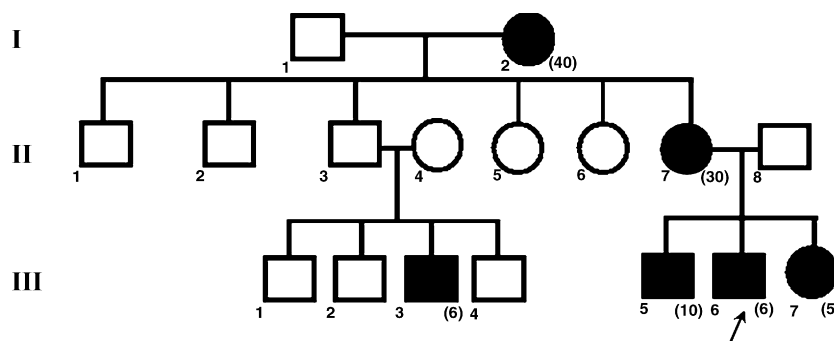


Fig. 2. Pedigree chart showing involvement in six members of the family spanning three generations. Three members of the family (II₇, III₅, III₆) satisfied the criteria for Behçet’s disease. Roman numerals indicate generation, number in bracket indicates age of illness onset, number without bracket indicates order in generation and arrow indicates index case.

Behçet's disease has a strong genetic basis, as evidenced by high prevalence in countries along the ancient "Silk Route" of the Far and Middle East and around the Mediterranean Sea [8]. Familial disease occurs in 10.8% of cases and inheritance pattern is controversial; it has not been reported from India [9]. This study highlights the marked phenotypic heterogeneity amongst affected family members. While six members spanning three generations had recurrent oral ulcers and four had recurrent genital ulcers, only three members met the International Study Group criteria for Behçet's disease. This may indicate partial penetrance [3].

Clinical features were heterogeneous amongst those with the disease (II₇, III₅, III₆): two members had characteristic skin lesions and only one had positive reaction in the Pathergy test. Genetic anticipation, characterized by earlier disease onset or more severe manifestations in successive generations, is known to occur in familial Behçet's disease [9]. Involvement of several members and occurrence of anticipation indicates that expansion of a trinucleotide repeat sequence may be occurring in the family of our patient, a postulation requiring further elucidation [9]. Age of onset in generation III (Fig. 2) was younger than that described in similar families in literature.

Association between Behçet's disease and HLA-B51 antigen is well documented, especially in patients from the Middle and Far East and those with more severe disease [1]. Recent studies have shown that HLA-B exonic sequence that encodes the HLA-B51 allele is the real pathogenic factor in Behçet's disease [10]. However, our patient was carrying HLA-B37/B7, while the mother was carrying HLA-B37/B40. HLA-B37 was common and could be a susceptibility factor in the family. The absence of HLA-B51 haplotype in the family indicates heterogeneity in the susceptibility for Behçet's disease. In addition to HLA haplotypes, other genetic factors may also contribute to disease susceptibility including MEFV gene mutations [11]. Whether genetic variability is related to the geographic distribution of the disease requires further studies in the Indian population. However, it would

be a challenge to establish the genetic basis of Behçet's disease in the absence of specific biochemical or immunological markers.

This case report highlights neuropsychiatric manifestations and the phenotypic variability of Behçet's disease. It also demonstrates familial disease and putative genetic mechanisms.

References

- [1] Azizleri G. Juvenile Behçet's syndrome. In: Ball GV, Bridges Jr SL, editors. *Vasculitis*. Oxford: Oxford University Press; 2002. p. 441–4.
- [2] Makni H, Kolski R, Kolski S, Bahloul Z, Jarraya A, Ayadi H. Familial Behçet's disease, clinical and immunological study about 26 cases. *Rev Rhum Engl Ed* 1996;63:537.
- [3] International Study Group for Behçet's Disease. Criteria for diagnosis of Behçet's disease. *Lancet* 1990;335:1078–80.
- [4] Ho CL, Deruytter MJ. Manifestations of neuro-Behçet's disease. Report of two cases and review of the literature. *Clin Neurol Neurosurg* 2005;107:310–4.
- [5] Kizilkilic O, Kocer N. Manifestations of neuro-Behçet's disease: report of two cases and review of the literature. *Clin Neurol Neurosurg* 2006;108:616–7.
- [6] Wechsler B, Vidailhet M, Piette JC, Bousser MG, Dell Isola B, Bletry O, et al. Cerebral venous thrombosis in Behçet's disease: clinical study and long-term follow-up of 25 cases. *Neurology* 1992;42:614–8.
- [7] Öktem-Tanör Ö, Baykan-Kurt B, Gürvit İH, Akman-Demir G, Serdaroglu P. Neuropsychological follow-up of 12 patients with neuro-Behçet disease. *J Neurol* 1999;246:113–9.
- [8] Haghighi AB, Pourmand R, Nikseresht A-R. Neuro-Behçet disease. A review. *The Neurologist* 2005;11:80–9.
- [9] Fresko I, Soy M, Hamuryudan V, Yurdakul S, Yavuz S, Tumer Z, et al. Genetic anticipation in Behçet's syndrome. *Ann Rheum Dis* 1998;57:45–8.
- [10] Sano K, Yabuki K, Imagawa Y, Shiina T, Mizuki N, Ohno S, et al. The absence of disease-specific polymorphisms within the HLA-B51 gene that is the susceptible locus for Behçet's disease. *Tissue Antigens* 2001;58:77–82.
- [11] Imirzalioglu N, Dursun A, Tastan B, Soysal Y, Yakicier MC. MEFV gene is a probable susceptibility gene for Behçet's disease. *Scand J Rheumatol* 2005;34:56–8.