

CASE STUDY

Recovery from hemiparesis and unilateral spatial neglect after neonatal stroke. Case report and rehabilitation of an infant

LARISSA BOLLEA, GIUSEPPE DI ROSA, ANTONIO GISONDI, PATRIZIA GUIDI, MAURIZIO PETRARCA, PAOLA GIANNARELLI, & ENRICO CASTELLI

Pediatric Rehabilitation Department, Children's Hospital Bambino Gesù, Passoscuro Fiumicino (Rome), Italy

(Received 30 May 2006; accepted 30 November 2006)

Abstract

Primary objective: To report rehabilitation of neglect in a child through task contexts.

Methods and procedures: A 7-month-old boy with hemiparesis and neglect following neonatal stroke was evaluated with standard assessments during the first year of intervention. The intervention included timely training of each upper limb's movement (reaching, grasping, lifting, rotating, releasing, etc.), balance training and Constraint-Induced Movement Therapy (CIMT). We promoted the storing of spatial representation through enriched environment by meaningful sensory inputs engaging spatial localization/orientation and eye movements.

Main outcomes: During intervention the child developed reaching and grasping and other new motor behaviours (holding, releasing, lifting, rotating, transferring, pulling, manipulating objects, gesturing, self-feeding, walking). In parallel he also exhibited a decrease of neglect.

Conclusion: Infants with stroke should be routinely checked for neglect. Especially those with hemiparesis and neglect challenge the rehabilitation team for the complexity of the treatment directly focused on addressing integration at more conscious levels of upper limb paresis and neglect.

Keywords: Neonatal stroke, hemiparesis, neglect, task context, early rehabilitation

Introduction

Neonatal stroke is defined as acute focal neurological deficit of >24 h duration occurring in the first 28 days of postnatal age [1]. Current studies on neonatal stroke focus mainly on prevalence, diagnosis and clinical outcomes [2]; however, limited information is available on the rehabilitation treatment of these children.

Generally, infants who suffer from neonatal stroke develop varying degrees of hemiparesis, which is usually characterized by reduced strength and speed of movement, impaired motor control and spasticity of the affected limb [3]. Unilateral spatial, or hemispatial, neglect is a multicomponent syndrome defined as failure to report, respond or orient to

stimuli on the contralesional side [4] that cannot be attributed to primary sensory and motor deficits [5]. Neglect is a frequent sequel to unilateral brain injury in adults and can also be diagnosed in children [6]. Nevertheless, there are few studies on neglect in children [6–17] and, even though research on adults emphasizes the importance of prompt rehabilitation intervention [18, 19], no studies report neglect rehabilitation in children.

Further, it has been demonstrated that task-specific, repetitive, training regimens can determine cortical changes and functional improvements [20], thus confirming the value of exercise and training. Effective outpatient therapies, such as Constraint-Induced Movement Therapy (CIMT), have been developed [21] as a result of these observations.

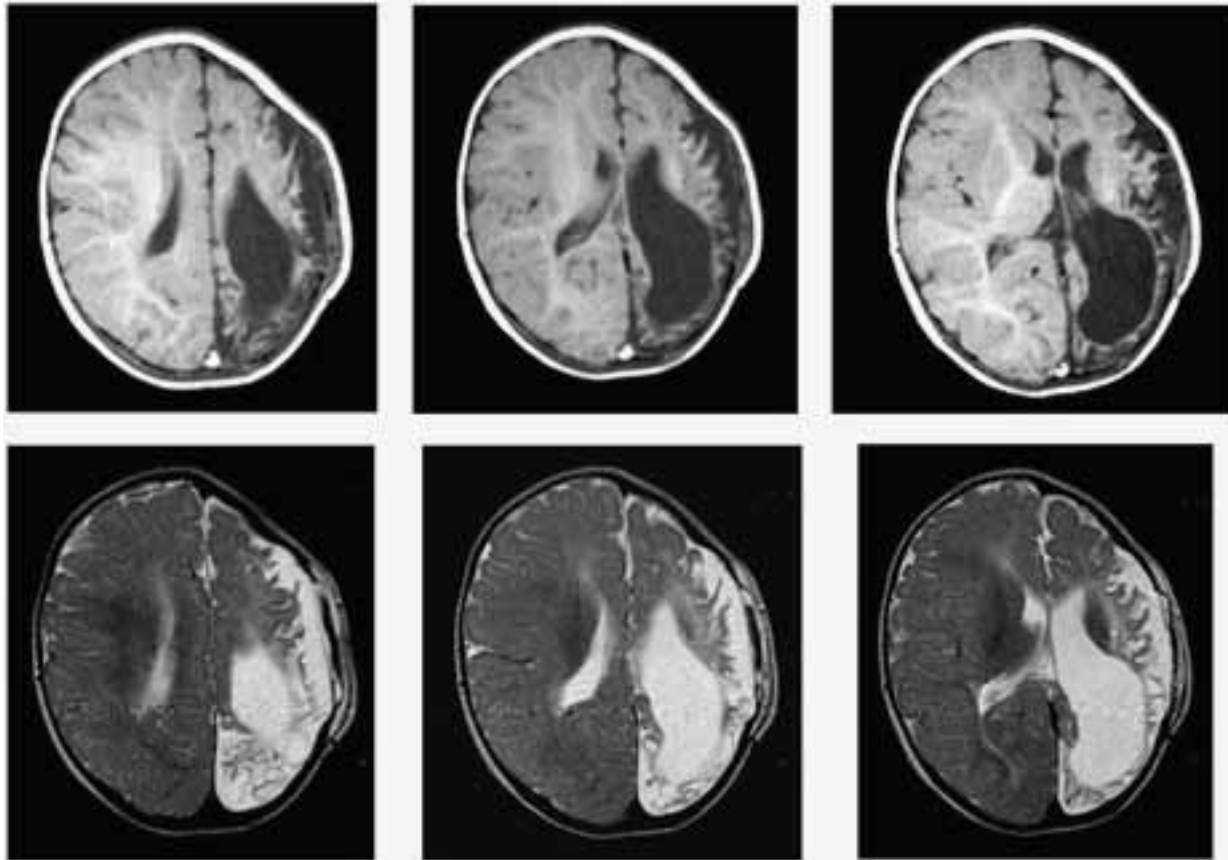


Figure 1. T1 and T2 MRI scans show left hemi-brain atrophy with large porencephaly involving temporo-parieto-occipital lobes and posterior region of frontal lobe.

In the last 10 years CIMT, based on the learned non-use theory, has demonstrated benefits for both adults and children with hemiparesis in terms of increased use of the affected upper limb in daily life activities [22, 23]. Nevertheless, few studies have described the task context of rehabilitation treatment in hemiparetic children [24, 25].

This case study presents a young child who suffered from hemiparesis and hemispatial neglect following early focal brain damage. We describe functional recovery during the first year of treatment including improvements in the quality of reaching and grasping movements and in basic activities and intentional movements. We also describe the rehabilitation procedures related to direct perception theoretical approach [26] chosen by us to maximize the high potential of plasticity in the child's developing brain.

Case report

Our patient was a 7-month-old boy with right hemiparesis and neglect following neonatal haemorrhagic stroke. His neonatal course

was characterized by a haemorrhage in the left hemisphere when he was 6 days old. Haemophilia A was diagnosed.

Head magnetic resonance imaging (MRI), performed at 5 months of age, showed signal abnormalities in temporo-parietal-occipital lobes and posterior region of the frontal lobe of the left hemisphere, associated with severe enlargement of subarachnoid space and of lateral ventricle (Figure 1). When the child was admitted to our Department at 7 months of age, he displayed hemiparesis and signs of right-sided spatial neglect, which correspond with Ferber and Karnath's [27] behavioural diagnostic criteria for neglect. He underwent a neuro-ophthalmological assessment to evaluate possible visual disorders. Fundus examination was normal. Flash visual evoked potentials (VEPs) recorded normal amplitudes and latencies of VEP components, prolonged duration and abnormal morphology of P2 component. Kinetic perimetry, performed at 7, 12 and 24 months of age using a double-arc perimeter developed by van Hof-van Duin [28] for use in infants and young children with normative data, revealed hemianopia. At 4 years of age, when reliability cooperation in visual

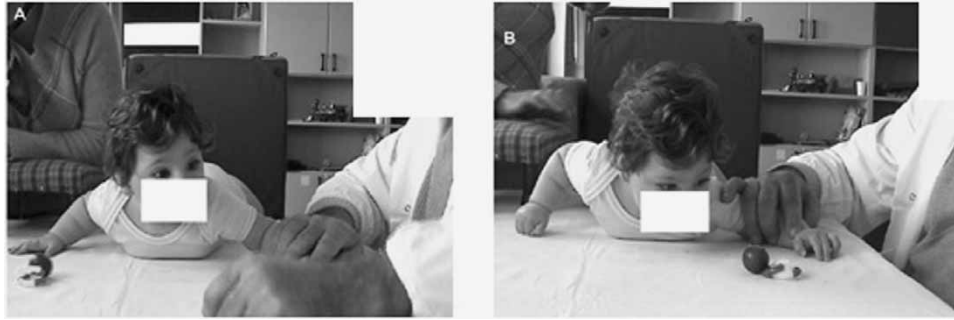


Figure 2. Assessment task for neglect at the baseline. (A) The moving object does not evoke the child's orientation towards the right side. (B) The child tracks the object in the left hemisphere.

field tests is present, hemianopia was confirmed by standard Goldmann apparatus.

Since he was 7 months old he has received a modified version of the CIMT protocol. It involves training of the affected upper limb for 2 hours a day with restraint of the intact upper limb for 4 hours a day. CIMT was administered for 1 year with two 2-month intervals during which training was carried out without constraining the intact upper limb. The protocol used is in accordance with recent studies advocating an adapted model of CIMT for small children [29, 30].

Baseline examination

The child spontaneously deviated his eyes and head towards the left side. We detected a deficit in right visual field scanning and tracking (Figure 2). Prolonged tactile stimulation permitted him to orient himself towards the right side and to activate his right arm. The patient's visual exploration of the object improved after hand contact (suggesting a dissociation between visual and tactile information); however, he did not generally see the hand manipulating the object. He held his right arm in a stereotypical position of shoulder adduction and internal rotation, with his elbow semi-flexed and his hand semi-opened. He performed reaching tasks using the left arm, executing arm trajectories in the left and sometimes in the right peripersonal hemispaces. Occasionally he used the right arm only when the left one was blocked. Right reaching/touching objects of different size (located one at a time first at the centre and then at 45° from the centre) was evident on the left and, less frequently, on the right hemispaces. Both hand-preshaping and shaping deficits were evident. In fact he could not conform his hand to the shape of the object before touching (preshaping deficit) and when touching (shaping deficit) it. However, he used to open spontaneously his fingers before hand/object contact and he was able to touch an object for a few seconds.

His right grip was also affected; he touched the object but did not grasp it. Grasping with his left unaffected hand was executed using a radial grip and a correct hand-preshaping and shaping, compatibly with his age.

Moreover, he did not look for objects that used to fall from his hand. He was also unable to perform transitions, crawling, rolling and to remain seated alone.

Baseline evaluation

Several tests were used to evaluate the child's performance before and during the first year of intervention. These outcome measures included: (i) Peabody Developmental Motor Scales (PDMS-2) [31], (ii) Pediatric Motor Activity Log (PMAL) [23], (iii) MacArthur Communicative Development Inventory (CDI) [32], (iv) Pediatric Evaluation of Disability Inventory (PEDI) [33], and (v) Gross Motor Function Measure (GMFM) [34]. Furthermore, Gaze Orientation Scale [35] and Two Object-Removal Preference Task [6] were employed to assess neglect.

The patient's results before the intervention are shown in Table I.

The PDMS-2 is a standardized assessment to quantify motor skills in children with motor impairment. The PDMS-2 Fine Motor Scale assesses reaching, grasping, manipulation, removing, releasing objects and visual-motor integration. The patient's scores, according to age equivalent in months, were 1 and 2 on the grasping and visual-motor integration subtests of the PDMS-2 Fine Motor Scale. Those scores were obtained by his ability of touching or scratching a toy and tracking it on his left side.

The PMAL is a scale developed specifically for Pediatric CIMT protocol. It consists of 2 subscales to assess 17 common daily tasks performed with the affected upper limb: (a) the Amount subscale (how often the child uses the upper limb) and (b) the How

Table I. The child's results on standard assessments during the first year of intervention.

Scale	Baseline	1 month	2 months	3 months	6 months	12 months
<i>PDMS-2 Fine Motor Scale</i> (Age equivalent in months score)						
Grasping	1	4	5	6	7	8
Visual-Motor Integration	2	4	5	5	7	8
<i>PMAL</i> (Mean score)						
How often	0.2				1.4	1.9
How well	0.2				1.4	2.0
<i>CDI</i> (Age equivalent in months score)	<8				<8	8
<i>PEDI</i> (Scaled score)						
Self-care	11.8				30.7	31.9
Mobility	11.4				33.4	52.2
Social function	3.1				14.7	31.6
<i>GMFM</i> (% score)						
Lying & rolling	43.1	58.8		74.5	92.2	98
Sitting	13.3	23.3		48.3	70	96.7
Crawling & kneeling	0	0		2.4	42.9	73.8
Standing	0	0		10.3	20.5	61.5
Walking, running & jumping	0	0		0	8.3	29.2
Total	11.3	16.4		27.1	46.8	71.8
<i>Gaze Orientation Scale</i> (Level)	3	2	2	2	1	1
<i>Two Object-Removal Preference Task</i> (Raw score)	0	0	2	3	5	7

Well subscale (how well the child uses the upper limb). The PMAL is a 6-point rating subscales (0 = no use, 5 = normal use). The patient's mean PMAL scores on both the Amount and the How Well subscales was 0.2, corresponding to no use of paretic upper limb according to parents' report.

The CDI is a standardized instrument to examine child's communication growth. We used the symbolic and communicative gestures subscale to report progress in this area. Initially the child did not use his paretic hand for gesturing.

The PEDI was used as an additional standardized assessment to measure function in daily life tasks in three domains: (i) self-care, (ii) mobility, and (iii) social function. The infant's PEDI scaled score in the self-care domain was 11.8 for eating pureed foods; it was 11.4 and 3.1 in mobility and social function domains for keeping a supported sitting position and orienting to sound, respectively.

The GMFM is a standardized observational tool designed to evaluate quantitative aspects of gross motor function. The infant's GMFM total score was 11.3 concerning the acquisition of reaching with his left arm crossing the midline in order to grasp a toy, and head stabilization.

The Gaze Orientation Scale assesses spontaneous gaze and head orientation for neglect; it is a 4-level rating scale (0 = no deviation, 3 = permanent deviation of gaze and head towards the ipsilesional hemispace). The patient presented at the Gaze Orientation Scale level 3, indicating practically permanent leftward deviation of gaze and head.

The neglect task administered was the Two Object-Removal Preference Task used by Trauner [6] to evaluate neglect in young children. In this task 20 small toys (cars, cows, boats, and dinosaurs), were arranged, on a corkboard (30 × 45 cm), in a fixed random array such that each toy was on both sides. The board was located in front of the child, seated on his mother's lap. The child's execution of the tasks was videotaped to measure retrospectively the objects touched or grasped. The number of objects touched or grasped in the right hemispace was rated. The child touched or grasped no objects on the right hemispace.

Intervention

Rehabilitation procedures: Selective contexts and training. Rehabilitation procedures included training of upper limb movements progressively more complex in relation to the child's acquisition of skills. Specifically, space localization and orientation, visual exploration and eye/head co-ordination were trained independently and within the upper limb movements training. Moreover, rehabilitation procedures comprised unilateral/bilateral activity and balancing.

Selective contexts (objects/visual or tactile background) were used during the whole treatment to evoke movements into play actions. Movements evoked by actions in selective structured contexts guided residual abilities in the recovery of spatial neural networks of eye, head, arm, hand and trunk actions in the child's right hemispace. The visual background consisted of a black and white



Figure 3. Note the visual background has a coloured toy on it. The context is set up on the right side. (A) The child gazes at the toy. (B) He tracks the toy that is moving away from the midline. (C) He holds his gaze on the toy at 90° from the midline.



Figure 4. Note the tactile background containing a coloured toy. The context is set up on the right side. (A) The child does not activate reaching/grasping in the right hemisphere. (B) He activates reaching/grasping when the toy is shifted near the midline. The background is used as a tactile guide to facilitate reaching/grasping. (C) He also activates reaching/grasping in right-sided sectors after experimenting with tactile guide near the midline.

checkerboard, measuring 100×100 cm, with high colour contrast and 5×5 cm squares (Figure 3). The tactile background was a wood or plastic board consisting of a showcase (space broken up into sections) containing objects located on a horizontal or vertical surfaces. Boards had from 9 to 17 holes located at a distance of 0.5–2 cm from each other, arranged in several horizontal rows and columns (Figure 4). The boards had three different sizes of holes: 7×5 , 9×7 , 18×10 cm. The organization of space on this tactile background helped the child in reaching and grasping an object with his hand, using visuo-tactile exploration. The objects, placed either on the checkerboard or inside the showcase, had a multisensory stimulation role (visual + auditory + tactile information: e.g., a squeezable coloured rubber animal in contact with the child's hand or face producing a sound).

Visual targets, placed at about 30° from the midline of the right hemisphere, were also utilized to involve localization and activation of reaching and grasping movements. These targets had different spatial properties (size, shape and orientation) and nonspatial ones (fragility, texture and weight); they

were fixed in various sectors of right hemisphere or mobile in different spatial directions.

Only objects with a diameter ≥ 3 cm in relation to the child's hand size were used to facilitate his hand opening and finger straightening. During the presentation of these objects we put the child in different positions (supine, on his side, prone, suspended and sitting) in order to enhance the adaptation of motor patterns.

A white board was placed in the left hemisphere to reduce its competitive advantage. Indeed, sensory events within the neglected hemisphere seem to lose their impact on awareness when competing events are taking place in the preserved hemisphere [36].

Training for recovery of active limb movements. Passive and active limb movements were supported by the selective contexts described above. The child was involved in playing activity in the right hemisphere, with passive movements provoking events on the affected side (e.g., moving a toy car from the neglected field, ringing a bell by physical guidance etc.). These experiences were

also carried out in different sectors of the intact left hemispace to facilitate recognition of the interplay. To this aim, passive movements of the upper limb evoked pleasurable events that were repeated with an unvarying cause-effect relationship. This training of passive movements was conducted for half an hour every day in the first month of treatment, then suspended for movement amelioration.

Training of active movements consisted of the use of appropriate toys or objects that have perceptual characteristics (visual, acoustic and tactile) and motivational attraction to evoke movements of the affected upper limb and thus organize functional abilities. To rehabilitate the motor-intentional impairment, the initial tasks aimed at evoking three movements in a repetitive, fixed sequence (reaching, grasping and releasing an object), by varying the interjoint co-ordination. These tasks were performed half an hour every day in the first month of intervention.

Training of simple actions. Subsequent tasks, starting at the second month of intervention for one hour daily, aimed at consolidating sequences of emerged actions. In the cookie removal task [37], the child had to take each cookie off the board, first using his right and then his left hand. The tactile board, separated by a midline, was placed in front of the child occupying both hemispaces. Long fingered cookies (3.5×9 cm) were fixed vertically in each hole of the board. A similar task consisted of removing, picking up, hollow geometric-shaped objects (cylinders and cubes), stacked on rigid, parallel, vertical pegs [37]. Geometric-shaped objects were constructed of solid plastic and wood, and measured from 3.5–5.5 cm in diameter-side (weight varying from 8–35 g). Pegs, fixed on a stable surface and distant 10 cm from one another, had various heights (7, 10, 15, 18 cm).

In another task the child had to move his right arm from peripersonal to personal space (e.g., by bringing a spoon to his mouth). Objects to be grasped were located at four angles from the midline (0° , 30° , 60° , 90°) and at two distances (10, 20 cm) from the initial hand location in the workplane.

Training of more complex actions. After 3 months of intervention, in relation to child's improvement on the scales, more complex tasks were used. Two objects were simultaneously put in both hemispaces; these objects were meaningful for the child and belonged to the same or to different categories (food, pacifier).

In the cylinders and cubes stacked up on the pegs task the child had to pick up and replace the objects, thus training pointing, grasping, lifting, replacing

and releasing. In one task he had to move his arm from peripersonal and extrapersonal to personal space and vice versa (e.g., bringing the spoon to his mouth and then offering it to his mother). His mother was at three distances (20, 30, 40 cm) from the initial hand location in the workplane. From this point on we always presented the child with new tasks to facilitate the acquisition of new complex sequences (e.g., pulling a toy train toward himself using the attached string). These tasks were conducted for half an hour, every day, until 12 months of treatment.

Training of bilateral activity. Specific tasks for bilateral manipulation were performed: opening a can (6 cm in diameter), catching and rolling a ball (>15 cm in diameter) on a black and white striped carpet, using geometrical brick toys (wood, foam rubber, etc). Geometrical brick toys were approximately the same size, measuring 4 cm in width and 6 cm in height. This training was performed from 3 to 12 months of treatment, daily, for half an hour.

Training of balance. We trained balance from the beginning of the treatment. The patient was seated on his mother's lap, and she induced perturbations on his bottom using her knees. A balance platform was used to train the patient, first creating slight perturbations when he was sitting (on a small seat, based on the length of the child's lower limbs) and then standing (during attempts to make reaching and grasping movements). Training for sitting balance was conducted for the first 3 months, followed by the one for standing balance until 12 months of treatment. Both of them lasted half an hour every day.

Outcomes

After one month of treatment. The child's visual performance and attention to the right hemispace were slightly improved (he passed from level 3 to 2 on the Gaze Orientation Scale and from age 2 to 4 months on the visual-motor integration subscale of the PDMS-2 Fine Motor Scale). He held his head in the correct position. The reaching task with the right affected arm succeeded, even when his other arm was not blocked, by using a tactile board (showcase). We observed attempts to grasp objects with the right hand. Objects of various sizes evoked whole hand prehension; medium and small objects were also grasped by finger prehension.

After two months of treatment. The child increased his visual scanning and tracking to the right side; he was able to track an object from left to right

(his score on the visual-motor integration subscale of the PDMS-2 Fine Motor Scale improved from age 4 to 5 months). Objects with acoustic and dynamic characteristics (e.g., a noisy rolling ball, a toy train running on a track) evoked visual tracking towards the right hemispace. The child's attention was attracted towards the right hemispace when his mother caressed and kissed him on the right side of his face. Instead, his attention was rarely attracted when he heard his mother's voice or when she was in his right hemispace. More often than before, he used to look at objects falling from the showcase. Gaze and reach-grasp association became more frequent. The child was able to roll from a prone to a supine position only on his left side and from a supine to a sitting position always leaning on his left. He could remain in a sitting position by himself. His right arm was activated more easily even without the tactile board, and he always managed to grasp objects. Object transferring and releasing emerged; he released objects, but only after several attempts with his right hand. Regarding the left unaffected hand grasping, lateral pincer grip and wrist orientation to the object developed consistently with the age; hand-preshaping and shaping were absolutely correct.

After three months of treatment. Visual performances and attention to the right hemispace were substantially unchanged. The patient could roll from a supine to a prone position on both sides and he assumed a prone position on his elbows; he started to crawl holding his right arm back. Right arm reaching movements towards a target located in all sectors of peripersonal space became purposeful. The child's right hand grasping behaviour was less impaired: preshaping and wrist orientation were usually congruent with the objects. However, sometimes he opened his fingers only after touching the object; finger closing always followed finger opening. Then he acquired the ability to rotate an object he was holding. In manipulation tasks he often passed objects from one hand to the other and vice versa. When the patient clapped his hands he was able to move both of them, but only one at a time and only if one hand was assisted by the other. He easily released the object. Left hand grasping evolved fairly with the child's age: precision grip emerged.

After six months of treatment. The child improved his orientation towards the right side (he passed from level 2 to 1 on the Gaze Orientation Scale and from age 5 to 7 months on the visual-motor integration subscale of the PDMS-2 Fine Motor Scale). He adopted bottom-shuffling to get a toy. He took steps when supported by someone holding his hand.

He began to lift and pull objects as well as perform some bilateral activities (e.g., holding a cup using both hands).

After twelve months of treatment. The patient showed spontaneous tracking and visual scanning towards the right side; however, he continued to prefer visual exploration on the left side. He could rise to a standing position using a solid object for support and could stand up without support and keep his balance. He walked alone with an asymmetric gait pattern; though his left arm preference remained. A large object permitted him to use his right arm for some bilateral activity (e.g., holding a ball). Furthermore, movements requiring the transfer and placement of objects facilitated his right hand function in bilateral tasks.

Results of outcome measures

The patient's results over the first year of intervention can be seen in Table I.

Upper limb function. The patient's PDMS-2 raw score on the Fine Motor Scale (grasping and visual-motor integration subtests) revealed some improvement from baseline to 12 months of treatment (Table I). Specifically he became able to reach and grasp toys, like moving them from one side to the other and vice versa, able to pull a string to get a toy, to track a rattle on both sides, and to transfer a cube from one hand to another.

The child's mean PMAL score demonstrated a moderate increase in the use of his arm-hand in different daily activities during the first year of treatment. At 12 months of treatment his upper limb achieved the possibility of self-initiated use in some occasions and a moderate quality of use. At the same time the CDI showed progressive moderate improvement of manual gestures.

Functional skills. The patient's PEDI scaled score in the self-care domain increased mostly from baseline to 6 months of treatment. The child began to eat chunk/diced food, to use both hands for feeding and to lift a glass using the affected hand. After 6 months slight improvements were noted. The PEDI scaled score in the mobility domain progressed linearly from baseline to 12 months of treatment. At 6 months the patient walked with support for short distances; after 12 months he walked alone also on uneven ground. The PEDI scaled score in the social function domain increased constantly from baseline to 12 months of treatment. The child understood simple phrases; he was

interested in other people and tried to communicate with them.

Gross motor skills. The patient's GMFM total score progressively increased during the first year of treatment. The GMFM score in the lying/rolling and sitting dimensions progressed from baseline to 12 months. In particular, the following abilities improved in the first 3 months: rolling from a supine to a prone position, initially only on the unaffected side, afterwards on both sides. The GMFM score for crawling/kneeling and standing dimensions progressed continuously from baseline to 12 months of treatment; the score for the walking/running/jumping dimension from 3–12 months of treatment.

Neglect assessment. The Two Object-Removal Preference Task revealed recovery during the first year of treatment. During this time, progressive improvement was also noted on the Gaze Orientation Scale. Neglect recovery proceeded over time but was not completely resolved after 12 months of treatment.

Discussion

Neglect can be isolated or associated with hemiparesis or primary sensory deficits and, in the latter case, it may be often masked by hemiparesis or primary sensory deficits [38]. Thus, neglect, even if severe, may be underestimated in children, especially in very young ones. In this disorder the motor impairment may include all aspects of motor act programming and its performance. In a perspective of rehabilitation, neglect can best be thought as a disorder characterized by perception/action dissociation involving perceptual and motor functions.

Spontaneous recovery from neglect is only partial; in fact our case confirms the findings of previous studies where neglect can significantly decline only after re-education aimed at the early identification of perceptual and motor impairments [18, 19]. Initially, in our child with left hemisphere lesions right reaching and grasping movements were both involved. Dissociation was also evident between action and location/perception of object on the right side. On the basis of this clinical condition we practised an asymmetric constraint training, reinforced by CIMT, in order to encourage maximally the potential of the child's brain plasticity, during a period of rapid development. As neglect can be also considered an unsettling of the spatial representations between right and left hemispheres responsible of motor programs [39], this kind of treatment

substantially aimed to activate the perception/action interaction and moreover to contrast the unbalanced competition between the two hemispaces in order to lessen motor and cognitive impairments. For this reason, our major effort consisted of setting up sensorimotor exercises enriching the environment (the child's training set) trying to prepare the child to action, according to Gibson theory [26] of direct perception. In fact, Gibson suggests that direct perception is the activity of pick up information (the invariants) from the environment, involving the exploratory activity of looking and searching around things. Eye, head, and body movements are part of this perceptual process. Therefore, the analysis of the visual information is relevant for action to permit visually-guided motor behaviour (e.g., reaching, grasping, manipulating objects, sitting, walking toward, coming in, stair-climbing etc).

We used enriched visual or tactile backgrounds (selective contexts) to evoke movements in our attempt to link the child's perception with eye, head and body movements. We emphasize the consequent storing of spatial representation, built up from collection of visual and proprioceptive information coupled with eye, head, and arm movements.

The child's movements, at first independent and dissociated, gradually became more integrated. Initially, the patient's association between perception and movement remained unconscious; subsequently, consciousness episodically emerged as knowledge of action [40] (prediction of incipient events). First, repetition of game actions produced movements able to attract the child's attention in an externally triggered way (evoked movements) and further on linked to an internal representation (intentional movements). Specifically, we identified altered or missing movements (reaching, grasping, lifting, rotating, transferring, manipulating, releasing, etc) of his affected upper limb to develop appropriate exercises for single upper limb movement and compounds of these, with particular attention to the child's body positions.

During the rehabilitation treatment our child was able to activate context-dependent movements of upper limb that were progressively adapted to the characteristics of the object. Monitoring of scales, supported by behavioural observations, permits us to identify differences in time's recovery of every upper limb's movements. For example, during the first month of treatment the child partially recovered both reaching and grasping. However, grasping improved during the second month and reaching during the third month. Regarding the emergence of other movements (transferring, releasing, rotating, lifting and pulling), they appeared only after 2–6 months of treatment. After 3 months of treatment

bilateral activity was detected, with major involvement of the affected hand in bimanual co-ordination. This progress was revealed by the PDMS-2 Fine Motor Scale. Continuous improvements were also noted in all domains of the PEDI and GMFM during the first year. During this time, we noticed a moderate improvement in the spontaneous use of the arm-hand in daily life activities by the PMAL and in communicative manual gestures by the CDI. The Two Object-Removal Preference Task and the Gaze Orientation Scale demonstrated that neglect was gradually subsiding but was not completely resolved. Indeed, we were unable to resolve the upper limb deficit in hand initiative.

Our training initially consisted of passive, guided reaching movements toward the target and gradually followed by active movements. In this manner we tried to increase the flexibility of the child's reaching movement organization with simultaneous covariations between arm force production and visual-proprioceptive information during movement trajectories. We adopted this training to facilitate the interjoint synergies of reaching movements involving some joints (shoulder and elbow) and blocking others (wrist) and also to reduce neglect.

In fact, studies of reaching in hemiparetic patients have demonstrated that the abnormal torque production [41] and disrupted interjoint co-ordination of arm [42] may be due to a deficit in motor control [43]. Moreover, not only active but also passive movements are important for an amelioration of neglect by their somatosensory inputs production [44].

Furthermore, the training involved the grasping and manipulation of objects with different spatial and nonspatial characteristics, providing visual-tactile-proprioceptive information to improve movement. According to the child's functional status this training, as well as the reaching training, initially was supported by a passive guide during wrist pre-orientation/orientation, gripping and holding an object in different grasping and releasing conditions. Large objects were used to ensure maximum grasp aperture in accordance with studies [45, 46] showing that this aperture covaries linearly with the size of the object. Use of several object shapes and orientations permitted the experience of many corresponding hand preshapings/shapings and wrist rotations. Novel grasping tasks may open the gap to recover grasping skills.

Finally, we think that a selective re-education of looking, reaching, grasping and balancing can give an opportunity of facilitating functional development. In particular, selective training involving each movement (reaching, grasping, lifting, rotating, releasing, etc) of the affected upper limb can be relevant. In our case, selective training was used to

promote the acquisition of movements and to induce the child's knowledge of action. A suitable environment, with structured contexts (multimodal perceptual clues and motivating tasks), was helpful in the recovery of hemiparesis and neglect.

We conclude that infants with stroke should be routinely checked for neglect. Especially in those with hemiparesis and neglect, an early intensive intervention is essential and it is also important to refer the patient to other rehabilitation professionals.

Our case achieved the activation and enhancement of sequences of upper limb movements with context-dependent aims and the emergence of intentional bilateral activity in which the affected arm had a useful, assisting, but never primary function (typical in hemiparesis is the persistence of the child's deficit in hand initiative).

Consequently treatment for infants with hemiparesis and neglect challenge the rehabilitation team for the complexity of the treatment directly focused on addressing integration at more conscious levels of upper limb paresis and neglect. Brain MRI follow-up related to clinical assessment could have guaranteed additional, enlightening information on the possible plasticity of the developing brain. Unfortunately, we did not conduct it for practical, clinical limits. Greater knowledge about the rehabilitation process can be useful for the rehabilitation team of these patients, for example in improving management strategies and ensuring flexibility in rehabilitation approaches.

A further randomized controlled clinical trial is needed to demonstrate the effectiveness of our rehabilitation approach, in order to distinguish its effectiveness over and above the natural history of recovery.

Acknowledgements

We dedicate this article to the memory of Prof. Marcello Mario Pierro who transmitted his clinical and theoretical experience to us, making this article possible. We are grateful to Rosa Maria Conte for her helpful contribution.

This study was supported by grants from Italian Ministry of Health-Project: ICS 120.2/RF2003.PS/03/3.

References

1. Lynch JK, Hirtz DG, deVeber G, Nelson KB. Report of the national institute of neurological disorders and stroke workshop on perinatal and childhood stroke. *Pediatrics* 2002;109:116-123.

2. Härtel C, Schilling S, Sperner J, Thyen U. The clinical outcomes of neonatal and childhood stroke: Review of the literature and implications for future research. *European Journal of Neurology* 2004;11:431–438.
3. Uvebrant P. Hemiplegic cerebral palsy. Aetiology and outcome. *Acta Paediatrica* 1988;345(Suppl.):S1–S100.
4. Heilman KM, Watson RT, Valenstein E. Neglect and related disorders. In: Heilman KM, Valenstein E, editors. *Clinical neuropsychology*. New York: Oxford University Press; 1993. pp 279–336.
5. Bisiach E, Vallar G. Hemineglect in humans. In: Boller F, Grafman J, editors. *Handbook of neuropsychology*. Vol. 1, Amsterdam: Elsevier; 1988. pp 195–222.
6. Trauner DA. Hemispatial neglect in young children with early unilateral brain damage. *Developmental Medicine & Child Neurology* 2003;45:160–166.
7. Hécaen H. Acquired aphasia in children and the ontogenesis of hemispheric functional specialization. *Brain and Language* 1976;3:114–134.
8. Ferro JM, Martins IP, Tavora L. Neglect in children. *Annals of Neurology* 1984;15:281–284.
9. Johnston CW, Shapiro E. Hemi-inattention resulting from left hemisphere brain damage during infancy. *Cortex* 1986;22:279–287.
10. Ferro JM, Martins IP. Some new aspects of neglect in children. *Behavioural Neurology* 1990;3:1–6.
11. Thompson NM, Ewing-Cobbs L, Fletcher JM, Miner ME, Levin HS. Left unilateral neglect in a preschool child. *Developmental Medicine & Child Neurology* 1991;33:636–644.
12. De Agostini M. Le développement de la spécialisation hémisphérique. In: Kremin H, Leclercq M, editors. *Approche neuropsychologique de l'enfant*. Paris: Société de Neuropsychologie de Langue Française; 1992. pp 43–59.
13. Werth R. Shift and omissions in spatial reference in unilateral neglect. In: Robertson IH, Marshall JC, editors. *Unilateral neglect: Clinical and experimental studies*. Hove: Lawrence Erlbaum Associates; 1993. pp 211–231.
14. Katz N, Cermak S, Shamir Y. Unilateral neglect in children with hemiplegic cerebral palsy. *Perceptual and Motor Skills* 1998;86:539–550.
15. Laurent-Vannier A, Pradat-Diehl P, Chevignard M, Abada G. Négligence spatiale unilatérale et motrice chez l'enfant. *Revue Neurologique* 2001;157:414–422.
16. Grossi D, Lepore M, Napolitano A, Trojano L. On selective left neglect during walking in a child. *Brain and Cognition* 2001;47:539–544.
17. Laurent-Vannier A, Pradat-Diehl P, Chevignard M, Abada G, De Agostini M. Spatial and motor neglect in children. *Neurology* 2003;60:202–207.
18. Frassinetti F, Angeli V, Meneghello F, Avanzi S, Ladavas E. Long-lasting amelioration of visuospatial neglect by prism adaptation. *Brain* 2002;125(Pt 3):608–623.
19. Manly T. Cognitive rehabilitation for unilateral neglect: Review. *Neuropsychological Rehabilitation* 2002;12:289–310.
20. Butefisch C, Hummelsheim H, Denzler P, Mauritz KH. Repetitive training of isolated movements improves the outcome of motor rehabilitation of the centrally paretic hand. *Journal of the Neurological Sciences* 1995;130:59–68.
21. Taub E, Uswatte G, Pidikiti R. Constraint-induced movement therapy: A new family of techniques with broad application to physical rehabilitation – a clinical review. *Journal of Rehabilitation Research & Development* 1999;36:237–251.
22. Sterr A, Freivogel S, Voss A. Exploring a repetitive training regime for upper limb hemiparesis in an in-patient setting: A report on three case studies. *Brain Injury* 2002;16:1093–1107.
23. Taub E, Ramey SL, DeLuca SC, Echols K. Efficacy of constraint-induced movement therapy for children with cerebral palsy with asymmetric motor impairment. *Pediatrics* 2004;113:305–312.
24. van der Weel FR, van der Meer AL, Lee DN. Effect of task on movement control in cerebral palsy: Implications for assessment and therapy. *Developmental Medicine & Child Neurology* 1991;33:419–426.
25. Volman MJ, Wijnroks A, Vermeer A. Effect of task context on reaching performance in children with spastic hemiparesis. *Clinical Rehabilitation* 2002;16:684–692.
26. Gibson JJ. *The ecological approach to visual perception*. Boston: Houghton Mifflin; 1979.
27. Ferber S, Karnath HO. Size perception in hemianopia and neglect. *Brain* 2001;124(Pt 3):527–536.
28. van Hof-van Duin J, Heersema DJ, Groenendaal F, Baerts W, Fetter WP. Visual field and grating acuity development in low-risk preterm infants during the first 2½ years after term. *Behavioural Brain Research* 1992;49:115–122.
29. Eliasson AC, Krumlinde-Sundholm L, Shaw K, Wang C. Effects of constraint-induced movement therapy in young children with hemiplegic cerebral palsy: An adapted model. *Developmental Medicine & Child Neurology* 2005;47:266–275.
30. Naylor CE, Bower E. Modified constraint-induced movement therapy for young children with hemiplegic cerebral palsy: A pilot study. *Developmental Medicine & Child Neurology* 2005;47:365–369.
31. Folio R, Fewell R. *Peabody Developmental Motor Scales*, 2nd edn (PDMS-2). Austin: Pro-Ed; 2000.
32. Fenson L, Dale PS, Reznick JS, Thal D, Bates E, Hartung JP, Pethick S, Reilly JS. *The MacArthur Communicative Development Inventories: User's guide and technical manual*. San Diego, CA: Singular Publishing Group; 1993.
33. Haley SM, Coster WJ, Ludlow LH, Haltiwanger JT, Andrellos PJ. *Pediatric Evaluation of Disability Inventory (PEDI)*. Development, standardization and administration manual. Boston: New England Medical Centre Inc. and PEDI Research Group; 1992.
34. Russell DJ, Rosenbaum PL, Avery LM, Lane M. *Gross Motor Function Measure (GMFM-66 & GMFM-88) User's Manual*. Cambridge: Mac Keith Press; 2002.
35. Azouvi P, Samuel C, Louis-Dreyfus A, Bernati T, Bartolomeo P, Beis JM, Chokron S, Leclercq M, Marchal F, Martin Y, de Montety G, Olivier S, Perennou D, Pradat-Diehl P, Prairial C, Rode G, Siéroff E, Wiart L, Rousseaux M; French Collaborative Study Group on Assessment of Unilateral Neglect (GEREN/GRECO). Sensitivity of clinical and behavioural tests of spatial neglect after right hemisphere stroke. *Journal of Neurology, Neurosurgery and Psychiatry* 2002;73:160–166.
36. Robertson IH. Cognitive rehabilitation: Attention and neglect. *Trends in Cognitive Sciences* 1999;3:385–393.
37. Pierro MM, Stortini M, Giannarelli P, Maiocco D, Pettinari R. Recovery from left hemiplegia and unilateral spatial neglect after traumatic brain injury in a 7 months old child: Clinical evolution with constraint-induced movement therapy and neuropsychological rehabilitation. In: Monduzzi, editor. *3rd World Congress of Neurological Rehabilitation*. 2–6 April 2002; Venice. 2002. pp 189–198.

38. Schendel KL, Robertson LC. Using reaction time to assess patients with unilateral neglect and extinction. *Journal of Clinical and Experimental Neuropsychology* 2002; 24:941–950.
39. Rizzolatti G, Berti A. Neural mechanisms of spatial neglect. In: Robertson IH, Marshall JC, editors. *Unilateral neglect: Clinical and experimental studies*. Hove: Lawrence Erlbaum Associates; 1993. pp 87–105.
40. Arbib MA, Rizzolatti G. Neural expectations: A possible evolutionary path from manual skills to language. *Communication and Cognition* 1997;29:393–424.
41. Dewald JP, Beer RF. Abnormal joint torque patterns in the paretic upper limb of subjects with hemiparesis. *Muscle & Nerve* 2001;24:273–283.
42. Levin MF. Interjoint coordination during pointing movements is disrupted in spastic hemiparesis. *Brain* 1996;119(Pt 1):281–293.
43. Carr J, Shepherd R. *Movement science: Foundations for physical therapy in rehabilitation*, 2nd ed. Gaithersburg: Aspen Publishers; 2000.
44. Frassinetti F, Rossi M, Ladavas E. Passive limb movements improve visual neglect. *Neuropsychologia* 2001;39:725–733.
45. Marteniuk RG, Leavitt JL, Mackenzie CL, Athenes S. Functional relationships between grasp and transport components in a prehension task. *Human Movement Science* 1990;9:149–176.
46. Pryde KM, Roy EA, Campbell K. Prehension in children and adults: The effects of object size. *Human Movement Science* 1998;17:743–752.