

Cerebral Blood Flow Deficits in Hereditary Essential Myoclonus

Florence Delecluse, MD; Gunhild Waldemar, MD; Svein Vestermark, MD; Olaf B. Paulson, MD, PhD

Hereditary essential myoclonus is a disease in which segmental myoclonus is the sole clinical abnormality and whose cause is unknown. It is characterized by an early onset, a benign course, an autosomal dominant pattern of inheritance, the absence of any other neurologic dysfunction, and normal results of auxiliary tests. Cerebral blood flow studies of a father and son with this disease showed a cortical blood flow reduction contralateral to the myoclonus symptoms. We postulate the cause to be a focal unilateral subcortical cerebral lesion, either in the basal ganglia or in the brain stem, with subsequent cortical deafferentation.

(*Arch Neurol.* 1992;49:179-182)

Hereditary essential myoclonus (HEM) is a rare but well-defined syndrome¹⁻⁶ of unknown origin. It has an autosomal dominant pattern of transmission with incomplete penetrance⁷ and onset during childhood. It consists of myoclonic jerks in a proximal distribution, with no other signs of central nervous system involvement. All ancillary tests, such as electroencephalography (EEG), computed tomography, visual evoked potentials, and polymyography, yield normal results.

To our knowledge, this is the first report of cerebral blood flow studies in HEM. Two members of a Scandinavian family with benign HEM spanning three generations were examined with

single-photon emission computed tomography (SPECT) and xenon 133 or [technetium 99m]-*d,l*-hexamethylpropyleneamineoxime (HMPAO), which revealed pertinent focal cerebral blood flow asymmetries.

REPORT OF CASES

CASE 1.—A 6-year-old boy had exhibited normal psychomotor development until his third year, when he developed muscle twitches and jerks affecting his right arm. These twitches and jerks were particularly pronounced during carefully controlled motor activity, such as drinking from a glass. Everyday activities, such as writing, drawing, and playing with toys, were difficult to perform. These sudden, uncontrollable arm jerks could be suppressed by strong voluntary muscle activity. They occurred neither during sleep nor at rest and did not interfere with standing or walking. Computed tomography and physical, mental, and neurologic examinations otherwise yielded normal findings. There has been no disease progression since age 5 years.

CASE 2.—The 40-year-old father of patient 1 has had muscle twitches and jerks since childhood. Jerks of his right upper limb have rendered the manipulation of small objects and drinking glasses difficult. His jerks also could be suppressed by strong muscular activity and disappeared during sleep and rest. The ingestion of small quantities of alcohol, however, had no effect. No other signs of neurologic involvement were noted. His computed tomographic scan was normal. Because of these jerks during controlled activity, this patient has abandoned social contacts, other than those that involve his family.

CASE 3.—The paternal grandfather of patient 1 reportedly has the same problems. He was never able to write a letter because of these same right-sided jerks. This patient could not be included in our study, however, as all attempts at personal contact or examination were refused.

MATERIALS AND METHODS

Regional cerebral blood flow (rCBF) was studied with a three-section brain-dedicated high-resolution SPECT system (Tomomatic 64, Medimatic, Hellerup, Denmark)⁸ in the Department of Neurology, Rigshospitalet, Copenhagen, Denmark. In the father, rCBF was studied twice on the same day by two different techniques: the ¹³³Xe-inhalation method and the [^{99m}Tc]-*d,l*-HMPAO technique. Both studies were performed during rest without myoclonic activity. The ¹³³Xe-inhalation study was performed to obtain quantitative data, and the [^{99m}Tc]-*d,l*-HMPAO study was performed to obtain high-resolution images of the distribution of rCBF. First, two ¹³³Xe-inhalation studies were performed to obtain six horizontal sections parallel to the canthomeatal plane. Each study lasted 4.5 minutes, during which ¹³³Xe was inhaled from a closed system with an initial concentration of 740 mBq/L, during the first 1.5 minutes. The arterial input to the brain was estimated from the lung curve profile obtained from a single stationary scintillation detector placed above the apex of the right lung. The calculation of absolute cerebral blood flow values from the distribution of the ¹³³Xe in the brain has been described in detail previously.⁹ With this technique, the final in-plane resolution is 17 to 20 mm (full width at half maximum), and the section thickness is 20 mm. In addition, SPECT was used to study the isotope distribution after the intravenous injection of 1.1 Giga-Becquerel of [^{99m}Tc]-*d,l*-HMPAO (Ceretek, Amersham, London, England). First, 60-second data acquisitions were performed in six different positions with the use of a low-resolution collimator. Then, three high-resolution data acquisitions were performed to obtain nine sections parallel to the canthomeatal plane. These high-resolution images were normalized to the cerebellum and corrected for back-diffusion of the tracer by a linearization procedure that has been described in detail previously.¹⁰ With the [^{99m}Tc]-*d,l*-HMPAO technique, the final in-

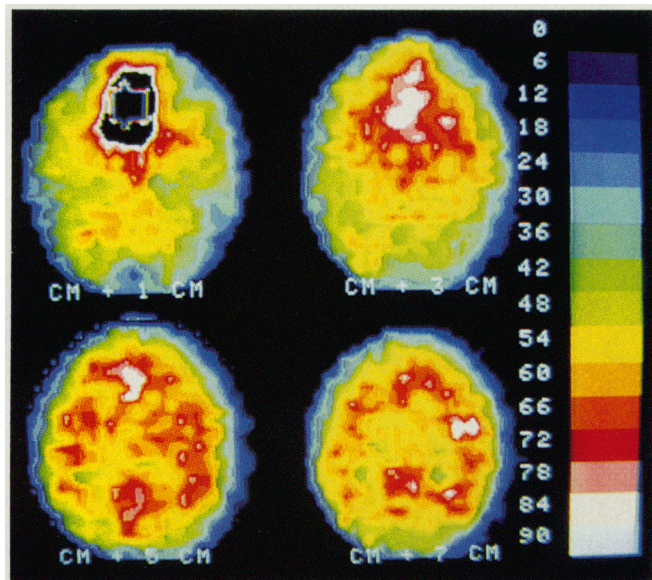


Fig 1.—Xenon Xe 133-inhalation single-photon emission computed tomographic scan of a 40-year-old man (patient 2) with essential myoclonus. Four sections parallel to the canthomeatal (CM) plane are shown. The left hemisphere is shown at left. The color scale indicates absolute blood flow values in milliliters per 100 g per minute.

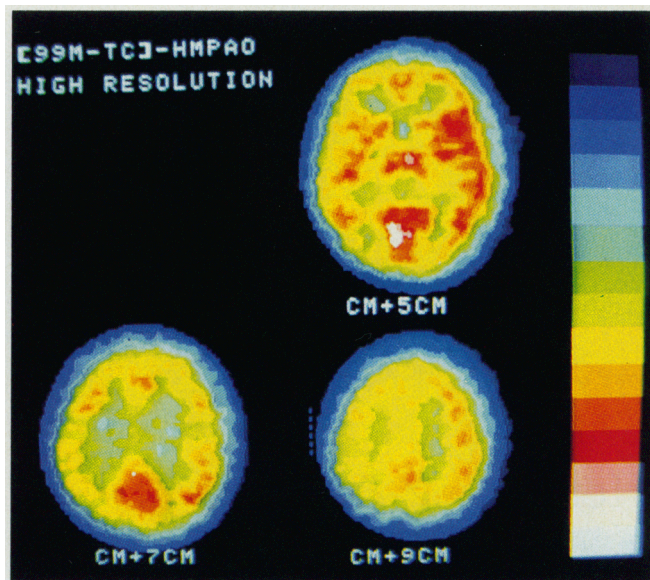


Fig 3.—Technetium Tc 99m-*d,l*-hexamethylpropyleneamineoxime (HMPAO) and low-resolution single-photon emission computed tomographic scans of a 40-year-old man (patient 2, left) and his 6-year-old son (patient 1, right). The left hemisphere is shown at left. One section located approximately 5 cm above the canthomeatal plane is shown.

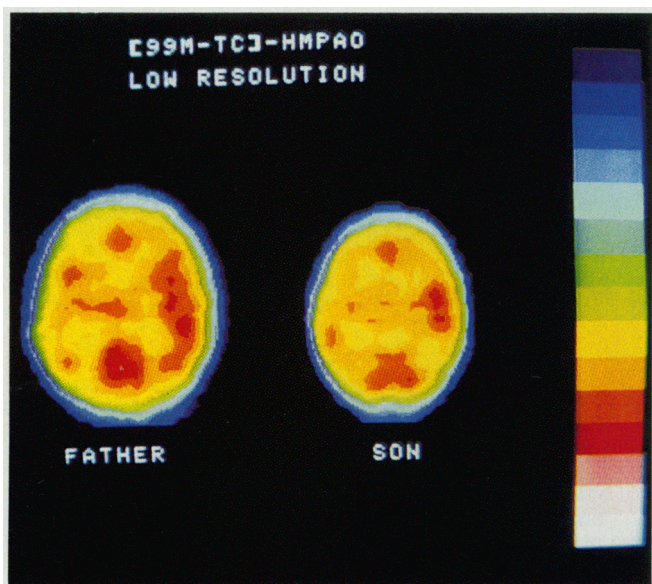


Fig 2.—Technetium Tc 99m-*d,l*-hexamethylpropyleneamineoxime (HMPAO) and high-resolution single-photon emission computed tomographic scans of a 40-year-old man (patient 2) with essential myoclonus. The left hemisphere is shown at left. Three sections 5, 7, and 9 cm above the canthomeatal (CM) plane are shown. The color scale indicates regional cerebral blood flow given in percent relative to the cerebellum.

plane resolution is 9 to 10 mm (full width at half maximum), and the section thickness is 10 mm. In the case of the 6-year-old son, only a low-resolution [^{99m}Tc]-*d,l*-HMPAO study was technically possible. Regional cerebral blood flow, or mean count rates, was calculated in several regions of interest, as described elsewhere.¹¹ The side-to-side asymmetry ratio for blood flow in a region of interest was defined as the difference in count rate or rCBF between the right and left regions of interest taken as a percent of the higher of the two. A side-to-side asymmetry ratio deviating more than 2 SDs from that of control subjects of the same age¹¹ was considered abnormal.

RESULTS

The results of the ¹³³Xe-inhalation study in the father are shown in the Table and in Fig 1. The mean cerebral blood flow values were 56 and 60 mL/100 g per minute in the left and right hemispheres, respectively. A marked reduction of rCBF was seen in the left frontal and temporal lobes. This reduction of blood flow was associated with a crossed cerebellar diaschisis.

The SPECT images from the high-resolution [^{99m}Tc]-*d,l*-HMPAO study are shown in Fig 2. These [^{99m}Tc]-*d,l*-

HMPAO images showed that the frontotemporal low-flow region extended into the parietal lobe as well. The isotope distribution in the basal ganglia and occipital lobes was normal (Table).

An image section from the low-resolution study performed in the son is compared with that of the father in Fig 3. The isotope uptake was reduced in the left hemisphere in both patients.

COMMENT

Until the present, although a number of studies have been conducted about HEM, to our knowledge no biochemical,

Regional Cerebral Blood Flow in a Father and Son With Essential Myoclonus*			
Region	Section	SAI, %	
		Father	Son
Xenon Xe 133 study			
Cerebellum	CM + 1 cm	-4.0	...
Cerebral hemisphere	CM + 5 cm	6.7†	...
Superior frontal cortex	CM + 7 cm	6.1†	...
Inferior frontal cortex	CM + 5 cm	6.7†	...
Temporal cortex	CM + 5 cm	11.0†	...
Superior occipital cortex	CM + 7 cm	3.1	...
Basal ganglia	CM + 5 cm	4.9	...
Frontotemporal ROI	CM + 3 cm	13.0†	...
Frontotemporal ROI	CM + 5 cm	11.0†	...
Frontotemporal ROI	CM + 7 cm	15.0†	...
High-resolution [technetium Tc 99m]-d,l-HMPAO study			
Midinferior temporal cortex	CM + 5, 7 cm	8.3†	...
Frontal ROI	CM + 5 cm	14.0†	...
Parietal ROI	CM + 9 cm	13.2†	...
Low-resolution [technetium Tc 99m]-d,l-HMPAO study			
Frontal ROI	CM + 5 cm	4.9	3.6
Temporal ROI	CM + 5 cm	8.2†	0
Frontotemporal ROI	CM + 5 cm	9.3†	5.8†

* Regional side-to-side asymmetry ratios (SAI) are given for cerebral blood flow values in selected regions of interest (ROI) from sections shown in Figs 1 through 3. HMPAO indicates hexamethylpropyleneamineoxime, CM, canthomeatal.

† Significantly abnormal SAI (ie, deviating >2 SDs from mean SAI for control subjects of the same age).¹¹

pharmacologic, or clinical study has elucidated the pathophysiologic mechanism underlying this disease.⁴ To our knowledge, there are no published anatomopathologic correlates in this disease with a benign course, and neither electrophysiologic nor radiologic studies have disclosed any abnormalities. Only by certain clinical similarities with more common types of action myoclonus have some authors suspected a "bulbopontocerebellar dysfunction" to be a possible cause of HEM.^{1,3}

To our knowledge, this blood flow study is the first to provide a direct clue toward an understanding HEM. Both patients described herein had a clinical syndrome limited to right arm jerks, and both showed a relative hypoperfusion of the left cerebral hemisphere associated with a crossed cerebellar diaschisis. In the father, this result was confirmed with two different techniques for the measurement of rCBF. Both patients were studied during rest only, as the jerks were too short-lasting for an ictal study to be performed.

These data would at first suggest that the underlying lesion causing these right arm jerks is an extensive contralateral cerebral hemispheric lesion, or perhaps a degenerative nature, as the flow deficit is not of a vascular distribution. However, in our cases of HEM, as in other published cases,^{4,6} no focal lesions or atrophy were demonstrated on a computed tomographic scan, nor were there any abnormalities on EEGs or VEPs. Logically, one would expect such an anatomic lesion of such vast cor-

tical extent to have some kind of radiologic or electrophysiologic repercussion. Therefore, the unilateral hemispheric cerebral blood flow hypoperfusion we observed cannot be attributed to a vast cortical lesion. A more plausible explanation for this finding would be the existence of a small subcortical lesion in the midbrain, with a secondary deafferentation of the ipsilateral frontal lobe as well as of the contralateral cerebellar lobe. In our patients, the rCBF pattern in the midbrain was considered normal. With the [^{99m}Tc]-d,l-HMPAO technique, the resolution is sufficiently high to calculate side-to-side differences in rCBF in many midbrain structures. However, for statistical reasons, a flow reduction in these areas must be severe to be significant.¹¹ Therefore, although we found normal rCBF in the subcortical structures, a very mild flow reduction in these areas, in addition to the marked cortical flow reduction, could not be excluded.

Deafferentation is a hypothetical mechanism that has mainly evolved from the study of diaschisis on cerebral blood flow and metabolism studies when acute hemispheric cerebral infarction was discovered to be linked with a decrease of regional flow and metabolism in areas of the brain remote from the infarcted tissue. Diaschisis is defined as the temporary depression of function in an area remote from the site of the primary injury. One of the first such described was the "crossed cerebellar diaschisis" with hypoperfusion of a cerebellar lobe due to a contralateral hemi-

spheric cerebral lesion.¹² The mechanism invoked is of deafferentation, a functional transneuronal depression by deactivation of connecting neural pathways.¹³ This same mechanism has been used to explain other types of diaschisis, such as the ipsilateral parietal hypoperfusion seen with thalamic¹⁴ or internal capsule¹⁵ lesions and the frontal hypoperfusion that has been described in some cases of Parkinson's disease,¹⁶ Huntington's disease,¹⁷ progressive supranuclear palsy,^{18,19} neuroacanthocytosis,²⁰ and even depression.²¹ Clinically, frontal deafferentation has been the postulated cause of the multiple cognitive deficits described in association with these later diseases. It must be noted, however, that frontal hypoperfusion or hypometabolism can coexist with normal cognition,¹¹ particularly in the healthy elderly person.

In keeping with this hypothesis of a primary subcortical lesion as the origin of HEM, an analogy can be attempted between HEM and other types of subcortical myoclonic disease, such as segmental myoclonus, which involves muscles or groups of muscle supplied by contiguous segments of the brain stem without EEG abnormalities. In their study of 18 cases of segmental branchial myoclonus, Jankovic and Pardo²² observed many possible causes and suspected that the underlying mechanism was abnormal discharges in the interneurons and motor neurons due to focal lesions of the inhibitory pathways, particularly in the midbrain. Other central nervous system regions implicated in the pathophysiologic features of other types of subcortical myoclonus include the Guillain-Mollaret triangle in palatal myoclonus²² and other types of segmental myoclonus,^{22,23} the substantia nigra and the dentate nucleus in progressive familial myoclonic epilepsy,²⁴ the medullary reticular formation in reticular reflex myoclonus,²⁵ and the central pons in a case associated with ocular bobbing.²⁶ In contrast, cortical myoclonus is usually multifocal and associated with either an abnormal EEG or giant somatosensory visual evoked potentials.^{27,28}

In conclusion, in these cases of HEM characterized by one-sided myoclonus, we have shown the existence of a contralateral cerebral blood flow hemispheric hypoperfusion. We believe that this finding can be best explained by a secondary deafferentation due to a small primary subcortical lesion, located in the brain stem or in the basal ganglia, with this lesion being the fundamental cause of HEM.

This study was supported by grants from the Danish Medical Research Council and the Lundbeck Foundation, Copenhagen, Denmark.

References

1. Daube JR, Peters HA. Hereditary essential myoclonus. *Arch Neurol*. 1966;15:587-591.
2. Mahloudji M, Pikielny RT. Hereditary essential myoclonus. *Brain*. 1967;90:669-674.
3. Korten JJ, Notermans SLH, Frenken CWGM, Gabreels FJM, Joosten EMG. Familial essential myoclonus. *Brain*. 1974;97:131-138.
4. Bressman S, Fahn S. Essential myoclonus. In: Fahn S, Marsden CD, Van Woert MH, eds. *Advances in Neurology, Vol 43: Myoclonus*. New York, NY: Raven Press; 1986:287-294.
5. Przuntek H, Muhr H. Essential familial myoclonus. *J Neurol*. 1983;230:153-162.
6. Lundemo G, Persson HE. Hereditary essential myoclonus. *Acta Neurol Scand*. 1985;72:176-179.
7. Gualandri V, Montagnani A, Bevilacqua ER, Orsino GB. Hereditary essential myoclonus: a genetic and clinical study of a family. *Rev Neurol (Paris)*. 1987;143:759-760.
8. Stokely EM, Sveinsdottir E, Lassen NA, Rommer P. A single photon dynamic computer assisted tomograph (DCAT) for imaging brain function in multiple cross sections. *J Comput Assist Tomogr*. 1980;4:230-240.
9. Celsis P, Goldman T, Henriksen L, Lassen NA. A method for calculating regional cerebral blood flow from emission computerized tomography of inert gas concentrations. *J Comput Assist Tomogr*. 1981;1:349-356.
10. Lassen NA, Andersen AR, Friberg L, Paulson OB. The retention of ^{99m}Tc -*d,l*-HM-PAO in the human brain after intracarotid bolus injection: a kinetic analysis. *J Cereb Blood Flow Metab*. 1988;8(suppl):13-22.
11. Waldemar G, Hasselbalch S, Andersen AR, et al. [^{99m}Tc]-*d,l*-HMPAO and SPECT of the brain in normal aging. *J Cereb Blood Flow Metab*. 1991;11:508-521.
12. Baron JC, Bousser MG, Comar D, Duquesnoy N, Sastre J, Castaigne P. 'Crossed cerebellar diaschisis': a remote functional depression secondary to supratentorial infarction of man. *J Cereb Blood Flow Metab*. 1981;1:500-501.
13. Meneghetti G, Vorstrup S, Mickey B, Lindewald H, Lassen NA. Crossed cerebellar diaschisis in ischemic stroke: a study of regional cerebral blood flow by ^{133}Xe inhalation and single photon emission tomography. *J Cereb Blood Flow Metab*. 1984;4:235-240.
14. Baron JC, D'antona R, Pantano P, et al. Effects of thalamic stroke on energy metabolism of the cerebral cortex. *Brain*. 1986;109:1243-1259.
15. Pappata S, Baron JC, Cambon H, et al. Remote effects of internal capsular infarcts: a positron tomography study. In: Meyer JS, ed. *Cerebral Vascular Disease*. Amsterdam, the Netherlands: Elsevier Science Publishers; 1987:6:211-217.
16. Perlmutter JS, Raichle ME. Regional blood flow in hemiparkinsonism. *Neurology*. 1985;35:1127-1134.
17. Kuhl DE, Phelps ME, Markham CH. Cerebral metabolism and atrophy in Huntington's disease determined by ^{18}F -FDG and computed tomographic scan. *Ann Neurol*. 1982;12:425-434.
18. Goffinet AM, De Volder AG, Gillain C, et al. Positron tomography demonstrates frontal lobe hypometabolism in progressive supranuclear palsy. *Ann Neurol*. 1989;25:131-139.
19. Blin J, Baron JC, Dubois B, et al. Positron emission tomography study in progressive nuclear palsy: brain hypometabolic pattern and clinicometabolic correlations. *Arch Neurol*. 1990;47:747-752.
20. Delecluse F, Deleval J, Michotte A, Gérard J-M, Zegers de Beyl D. Severe frontal hypoperfusion and impairment in neuroacanthocytosis. *Arch Neurol*. 1991;48:232-234.
21. Baxter LR, Schwartz JM, Phelps ME, et al. Reduction of prefrontal cortex glucose metabolism common to three types of depression. *Arch Gen Psychiatry*. 1989;46:243-250.
22. Jankovic J, Pardo R. Segmental myoclonus: a clinical and pharmacological study. *Arch Neurol*. 1986;43:1025-1031.
23. Costa B, Tacconi P, Pinna L, Cannas A, Fiaschi A. Segmental myoclonus in a young man who had had localized encephalitis in childhood. *Ital J Neurol Sci*. 1989;10:357-359.
24. Harriman DGF, Millar JHD. Progressive familial myoclonic epilepsy in three families: its clinical features and pathological basis. *Brain*. 1955;78:325-349.
25. Hallet M, Chadwick D, Adams J, Marsden CD. Reticular reflex myoclonus: a physiological type of human post-hypoxic myoclonus. *J Neurol Neurosurg Psychiatry*. 1977;40:253-264.
26. Zegers de Beyl D, Flament-Durand J, Borenstein S, Brunko E. Ocular bobbing and myoclonus in central pontine myelinolysis. *J Neurol Neurosurg Psychiatry*. 1983;46:564-565.
27. Halliday AM, Halliday E. Cerebral somatosensory and visual evoked potentials in different forms of myoclonus. In: Desmedt JE, ed. *Clinical Uses of Cerebral, Brainstem and Spinal Evoked Potentials*. Basel, Karger; 1980;7:293-310.
28. Rothwell JC, Obeso JA, Marsden CD. On the significance of giant somatosensory potentials in cortical myoclonus. *J Neurol Neurosurg Psychiatry*. 1984;47:33-42.