

Short communication

Carotid artery pseudoaneurysm resulting from an injury to the neck by a fouled baseball

William J. Benedict^a, Vikram Prabhu^a, Mari Viola^b, Josè Biller^{b,*}

^a Department of Neurological Surgery, Loyola University Chicago, Stritch School of Medicine, 2160 South First Avenue, Maywood, IL 60153, United States

^b Department of Neurology, Loyola University Chicago, Stritch School of Medicine, 2160 South First Avenue, Maywood, IL 60153, United States

Received 26 September 2006; received in revised form 4 January 2007; accepted 6 February 2007

Available online 21 March 2007

Abstract

Objective: Blunt carotid artery injury resulting in either dissection or pseudoaneurysm is a rare entity that can result in significant morbidity and mortality if undiagnosed. Although unavoidable in certain traumatic situations such as motor vehicle collisions, direct neck trauma in sports may be preventable with the use of proper protective equipment.

Clinical presentation: The following report documents a case of extracranial carotid artery dissection resulting from a foul ball striking the upper, lateral neck of an umpire. The patient had transient right upper extremity monoparesis. He later presented with right hemiparesis and aphasia that resolved over several hours. Imaging studies demonstrated a left carotid pseudoaneurysm with evidence of left hemispheric embolic infarcts.

Intervention: Systemic intravenous anticoagulation with heparin followed by oral anticoagulation with warfarin for 6 months, subsequently followed by aspirin monotherapy.

Conclusion: The use of standard protective equipment did not adequately cover the patient's neck in the region of the cervical carotid artery. This case illustrates that modification in current catcher and umpire equipment could potentially avoid this rare but significant vascular injury.

© 2007 Published by Elsevier B.V.

Keywords: Carotid artery; Pseudoaneurysm; Dissection; Baseball; Blunt injury; Anticoagulation

1. Introduction

Only 6% of blunt carotid injuries are diagnosed at the time of initial presentation and medical evaluation.[1] We recently treated a patient whose extracranial carotid artery dissection resulted from blunt injury while umpiring a little league baseball game. Despite the use of standard protective equipment, this patient sustained an injury that could have resulted in permanent neurologic deficits. Fortunately, he fully recovered and completed medical treatment without complication.

Standard umpire and catcher equipment protects primarily the chest and groin areas. Helmets with face protectors

may not guard the anterolateral neck where the extracranial carotid artery is vulnerable to injury, particularly from high velocity fouls as in this case. This report illustrates the need for considering modifications in standard umpire and catcher equipment in an attempt to prevent predictable injuries. Included, is a brief review of the current literature concerning the management of blunt carotid artery injury and dissection.

2. Clinical presentation

A 44-year-old right-handed man with a past medical history noteworthy for asthma presented to an outside hospital with acute onset of slurred speech and right upper extremity and facial weakness. A stroke was suspected; however, intravenous tissue plasminogen activator was not administered since the patient's deficits were improving in the emergency department. An MRI/MRA performed during his initial admission (within 48 h) demonstrated a dissection

* Corresponding author. Department of Neurology, Loyola University Medical Center, 2160 South First Avenue, Maywood, IL 60153, United States. Tel.: +1 708 216 2438; fax: +1 708 216 5617.

E-mail address: jbiller@lumc.edu (J. Biller).

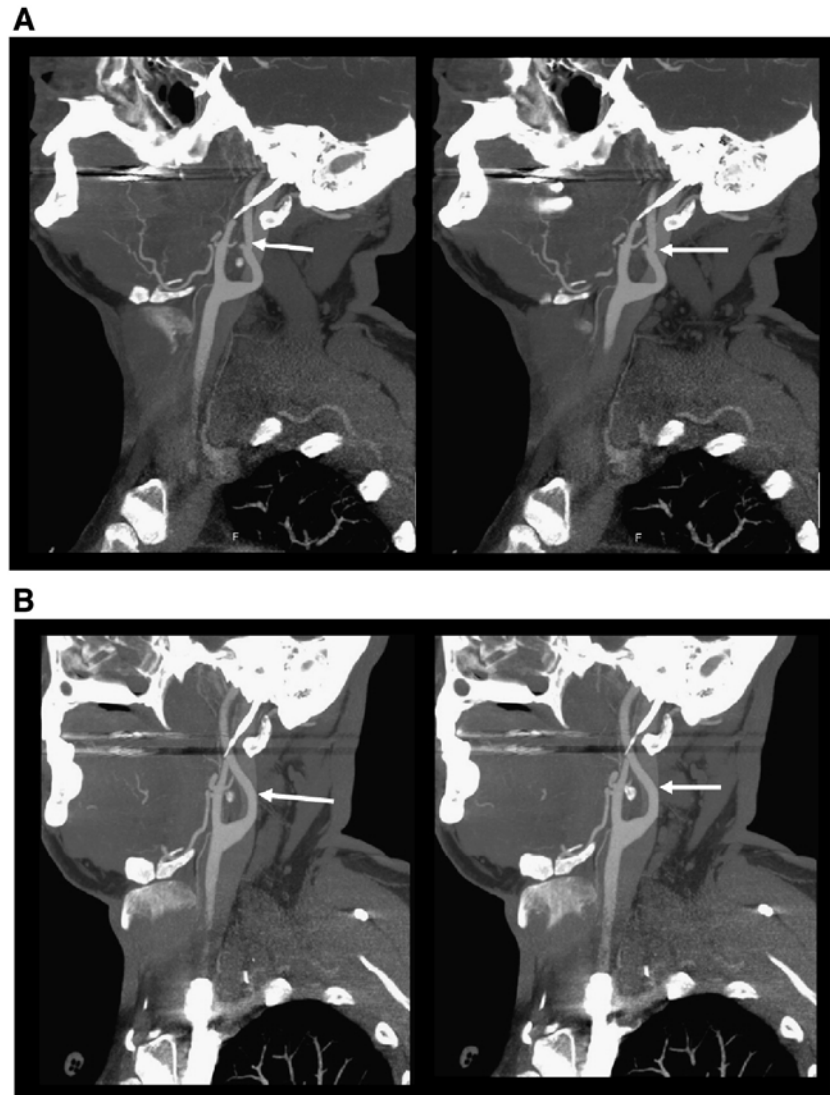


Fig. 1. A. CTA demonstrates a left pseudoaneurysm on the extracranial internal carotid artery (arrow). This lesion is identified 8 weeks following injury. B. Resolution of the pseudoaneurysm after 6 months of anticoagulation. After this study, the patient was placed on aspirin monotherapy.

of the left extracranial cervical internal carotid artery and multiple acute and subacute infarcts of the left hemisphere, particularly in the distribution of the middle cerebral artery. Three weeks prior to presentation, the patient was struck on the left side of the neck with a fouled pitch while umpiring a little league baseball game. The ball was deflected towards the patient as the batter swung. Immediately after this incident, he experienced right upper extremity weakness. Because his symptoms resolved, he did not seek medical attention at the time of injury. While hospitalized (3 weeks after injury), a two-dimensional echocardiogram demonstrated an ejection fraction of 64%. There was no evidence of intracavitary thrombi or valvular heart disease; a bubble study was not performed. An electrocardiogram demonstrated normal sinus rhythm. He received anticoagulation therapy with intravenous heparin, and was later switched to warfarin aiming for a target INR value between 2.0 and 3.0.

The patient presented to our institution for follow-up 8 weeks after his stroke. He was asymptomatic and his neurologic examination was normal. There was no suggestion of Horner's syndrome, any thrills or bruits upon examination of the carotids, and his speech and language were normal. Laboratory studies showed an LDL of 129 mg/dL. A lipid lowering agent was started, warfarin was continued with an INR value averaging 2.5, and the carotid arteries were re-imaged with a CT angiogram (CTA). This CTA (8 weeks after injury) demonstrated a small pseudoaneurysm distal to the left internal carotid artery bifurcation, at the level of the third cervical vertebra. However, as the patient was anticoagulated with warfarin, and otherwise asymptomatic, it was determined that follow-up 4 months later with another CTA would precede any potential surgical or endovascular intervention. Six months later, warfarin was discontinued, and the patient began aspirin monotherapy after another CTA demonstrated

resolution of the pseudoaneurysm. Fig. 1A shows the patient's CTA at 4 months following injury, then at 6 months (Fig. 1B) after resolution of the pseudoaneurysm.

3. Discussion

Most cervicocephalic arterial dissections involve the extracranial carotid arteries. Carotid artery dissection may result from blunt or penetrating trauma. It is among the more common causes of ischemic stroke in younger patients [2]. The terms pseudoaneurysm, false aneurysm, and dissecting aneurysm are applied generally to blunt carotid injury, even though there are subtle differences in pathophysiologic mechanisms. Following trauma to the carotid artery, blood dissects through the tunica media, directed towards either the tunica intima or adventitia. Subintimal dissection causes severe stenosis or occlusion. Imaging studies reveal a false lumen filled with hematoma. Subintimal dissection may also result in a prothrombotic free endothelial flap. Subsequent emboli manifest as transient ischemic attacks (TIAs) or strokes. Subadventitial dissection creates a false lumen as blood escapes and invests into surrounding tissues. When contained, a pseudoaneurysm without adventitial walls results. Significant disruptions may impede airway patency, as blood extravasates throughout the soft tissues of the neck [3].

Blunt mechanisms account for only 3% to 10% of all carotid artery injuries. Most cases of carotid artery trauma are due to penetrating injuries; primarily the result of projectiles [4–7]. Motor vehicle collisions account for the preponderance of blunt dissections. A study from the Mayo Clinic documents two patients over an 8-year period who sustained a carotid artery dissection from baseball injuries. Both patients experienced direct trauma in the region between the mandible and clavicle [8]. There are many small series and case reports of carotid artery dissection following minor trauma or neck maneuvering. These include rapidly drinking shots of alcohol (extending the neck) and tilting the head back in the beauty parlor for hair washing, causing a “beauty parlor stroke” [9,10]. Boxing, violent coughing, head turning while leading a parade, carotid compression, yoga, and chiropractic manipulation have also been implicated as causes of carotid artery dissection [11–15]. Additionally, rapid flexion and extension of the neck to music during “head banging” [16], flexion of the neck during telephone use [17], childbirth [18], ceiling painting, vomiting, sneezing, cardiopulmonary resuscitation, and neck hyperextension during intubation for surgery have been associated with carotid artery dissection [12,19–23]. Predisposing factors include any of the collagen vascular diseases (Ehlers–Danlos syndrome type IV, Marfan's syndrome), adult polycystic kidney disease, and osteogenesis imperfecta type I. Recent respiratory tract infection is an apparent risk factor possibly because of protracted coughing, but *Chlamydia pneumoniae* infection has no direct correlation with carotid artery dissection as once thought [24].

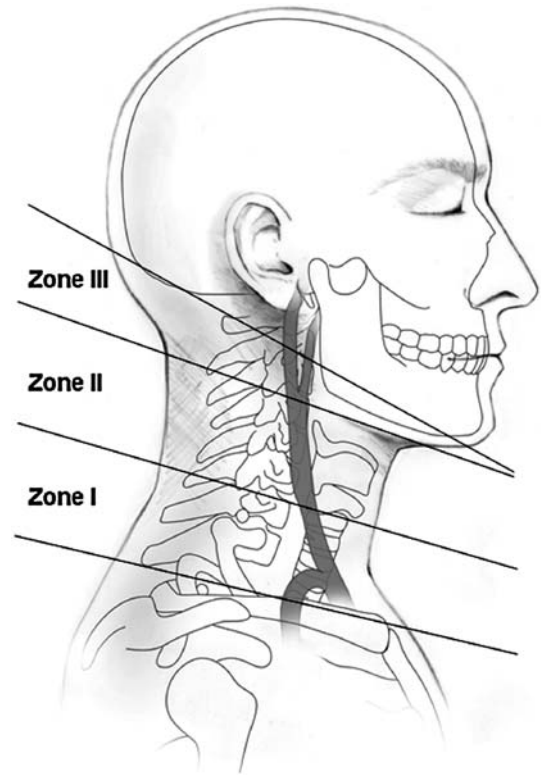


Fig. 2. The zones of the neck, and the relationship of the extracranial internal carotid artery, the cervical spine, and mandible.

For the purpose of descriptive analysis, one considers the neck in terms of three zones, created by constructing oblique lines at the mandible, cricoid cartilage, and clavicle (Fig. 2). The common internal carotid, particularly within Zones I and II, is susceptible to blunt injury because of tethering at the skull base and within the mediastinum. Direct blunt injury to the antero-lateral neck or rapid rotational neck movement will place the internal carotid artery at risk in Zone III. Crissey and Bernstein [25] describe 4 patterns of carotid artery injury. Type I injuries arise from rapid carotid compression (e.g., between the mandible and cervical spine). This may occur during a rear impact motor vehicle collision as the cervical spine experiences extremes of flexion and extension. Type II injuries result from contralateral rotation and hyperextension of the neck. Ninety percent of carotid artery injuries sustained during motor vehicle collisions are type II. Intra-oral trauma yields type III injuries. A classic example is the child who falls while having a sharp object (e.g., pencil or lollipop) in the mouth. Type IV injuries result from petrous skull base fractures. Associated facial nerve palsy may offer a clue to the clinician that a Type IV injury exists [25,26].

Fig. 3 demonstrates common examples of catcher and umpire protective equipment. The chest, groin, face, and neck are well protected by these devices. All zones remain vulnerable to lateral injury from either a baseball, or broken bat. Type I or II injuries may result from a high velocity baseball strike. Extension of either the face cage or upper rim



Fig. 3. Examples of umpire and catcher protective equipment. The midline neck is protected. Exposure of the lateral neck places the carotid artery at risk for blunt injury.

of the chest protector, laterally, would afford greater protection to the area where the extracranial carotid artery travels, preventing type I injury. A device limiting head extension could prevent type II injury.

4. Diagnosis, management, and outcome following blunt carotid injury

Diagnosis of blunt carotid artery injury may be difficult during primary and secondary trauma surveys. The patient may be asymptomatic, or documentation of a proper neurologic examination may be hindered because the patient is too severely injured. Some studies suggest an average of 53 h between injury and diagnosis. Only 6% to 10% of patients have localizing neurologic signs within the first hour following injury. Fifty percent of patients will demonstrate localizing signs within the first 10 h following injury, and 57% to 73% by the end of post-injury day 1. This “lucid interval” mimics that of an undiagnosed epidural hematoma [26].

The clinical features of blunt carotid artery injury are eloquently summarized by Jernigan and Gardener: a hematoma of the lateral neck, an ipsilateral Horner’s syndrome, TIAs, and a “lucid interval” followed by acute neurologic deficit in an awake patient [27]. Certain associated injuries may prompt evaluation of the carotid arteries. Parikh and colleagues determined that combined head and chest trauma is associated with a 14-fold increase in blunt carotid artery injury [28].

For those presenting in a delayed fashion, blunt carotid artery injury and dissection may manifest as unilateral facial or head pain in as many as 50% of patients. Two-thirds of patients have unilateral fronto-temporal and retro-orbital pain. One fourth of patients with a history of migraine characterize it as so. After onset of pain, other symptoms follow within an average of 4 days. Anhydrosis lacks among

those with Horner’s syndrome, as oculomotor sympathetic fibers travel with the external carotid artery. Twelve percent of patients will exhibit single or multiple cranial nerve palsies (XII, V, III). Loss of taste (dysgeusia) also can be a presenting complaint [24].

Several diagnostic tools are available for evaluation of the extra- and intracranial carotid artery, with cerebral angiography remaining the gold standard. MR angiography, CTA, and carotid ultrasound continue to evolve and become more available at a variety of centers. Doppler ultrasonography may identify up to 85% of all extracranial injuries according to one study [29]; however, its limitations include failure to identify subtle intimal changes. The intracranial and distal extracranial carotid artery cannot be evaluated by ultrasound. CTA has an 89% correlation with digital subtraction angiography in identifying carotid narrowing according to one study [30]. Advantages of CTA include minimal invasiveness, and potential availability in many centers. Most trauma patients have CT scanning of the head, abdomen, or cervical spine, allowing for easy integration of this additional study if indicated. Although less practical during the acute trauma radiographic evaluation period, MR angiography has up to 95% sensitivity and 99% specificity for identification of carotid dissection [26].

Overall mortality for blunt carotid artery injury is approximately 20% to 40%. Predictive factors for poor outcome include coma and shock at presentation. Carotid artery thrombosis with extensive stroke and coma predict a poor neurologic outcome. Before 1970, Yamada reported severe neurologic impairment in up to 90% of patients with blunt carotid artery injury [31]. In his series of over 50 patients, only 6 returned to gainful employment following injury. More recent studies by Fabian and Cogbill suggested that “good” neurologic outcomes occur in 45% to 63% of these patients [29,32]. More accurate diagnosis and definitive treatments likely account for such divergent outcomes

data. Treatment options for blunt carotid artery injury include direct surgical repair, systemic anticoagulation, and observation. Treatment goals aim to prevent emboli, promote recanalization, and avoid acute occlusion.

Anticoagulation with heparin, followed by oral anticoagulation with warfarin for 3–6 months is associated with better neurologic outcome, particularly if initiated before deficit develops. In Fabian's study of 87 dissections in 67 patients over 11 years, 62 individuals were diagnosed with partial arterial disruptions (pseudoaneurysm, thrombosis, or dissection). Five of the original cohort had either a complete disruption (one patient) or carotid-cavernous fistula. Of the 62 patients with partial disruption of the arterial wall, 47 received heparin while the others received either no treatment (8 patients), aspirin (6 patients), or surgery (one patient). Patients who received heparin had significantly better outcomes compared to those who did were not anticoagulated. Patients with minor neurological deficits resolved these, while those with major neurologic impairments improved. With anticoagulation, 62% of all dissections had resolved on follow-up angiography. The mean follow-up period was 172 days [32].

Portillo et al. reviewed their experience in 27 patients over 6 years [2]. They treated 17 patients with carotid artery dissection (traumatic and spontaneous). Thirteen of these patients had a modified Rankin score of 1 or 2 at a mean follow-up of 58 months, following treatment with anticoagulation. Biller et al. reviewed 10 years of experience with carotid artery dissection [33]. Eighteen patients were identified, of which 5 had experienced trauma. Although a small cohort, patients treated with heparin did better than those treated with aspirin.

Direct surgical repair has been shown to improve outcome in one older study [1], particularly for lesions that were easily accessible. Surgery may be considered for lesions that are accessible in hemodynamically and neurologically stable patients, where anticoagulation is contraindicated, or has failed. Techniques include thrombectomy, intimal flap repair, placement of interposition grafts with vein or synthetic material, and false lumen repair. For patients whose systemic injuries prohibit anticoagulation, extensive dissections near the skull base may require carotid ligation with or without bypass. Vishteh et al. reported 16 revascularization procedures for complex dissections in 13 patients having blunt carotid artery injuries with progressive neurologic deficits. These patients had either failed medical treatment or harbored systemic injuries prohibiting anticoagulation. At 2 year follow-up, 15 of the 16 grafts were open, and all patients were GCS 15, GOS 5. Complications included 1 epidural hematoma, 1 CSF leak, and 1 vein graft thrombus requiring thrombectomy. The majority of these cases involved high flow saphenous vein grafts connecting the cervical carotid to a portion of the intracranial internal carotid artery [34].

Carotid artery stents continue to develop, and may find a better defined role in the treatment of carotid artery

dissection, particularly when there is pseudoaneurysm formation, as these may not resolve with medical therapy. One study by Liu discussed the use of 11 stents in 7 patients for a variety of carotid pathologies, including dissections and pseudoaneurysms. Average follow-up was 43 months. Six patients had resolution of stenosis, with obliteration of pseudoaneurysms when present. There were no significant complications [35].

5. Conclusion

Blunt carotid artery injury is associated with considerable morbidity and mortality. Most dissections are missed during the initial trauma evaluation and resuscitation, particularly because the development of neurologic deficit may be delayed. Most blunt carotid artery injuries may be unavoidable; particularly those resulting from motor vehicle conclusions. However, the carotid artery may be injured in seemingly innocuous ways. In the case of baseball injuries, modifications in protective equipment may prevent carotid artery dissection in this select group of potential patients. Equipment modification should limit exposure of the lateral neck while preventing hyperextension and rotation. Although randomized controlled studies have demonstrated a reduction of recurrent ischemic events in patients with acute ischemic stroke related to atherothromboembolism and cardiogenic embolism, it is offset by the rate of intracranial and extracranial hemorrhage [36]. In the absence of data from a randomized controlled trial, data from Fabian and Portillo would suggest that anticoagulation is the best treatment option for patients diagnosed with dissection or pseudoaneurysm following blunt carotid artery injury.

Acknowledgement

We gratefully acknowledge the work of Dianne Martia, editor and illustrator for the Department of Neurological Surgery, for her assistance with this manuscript.

References

- [1] Krajewski LP, Hertzner NR. Blunt carotid artery trauma: report of two cases and review of the literature. *Ann Surg* 1980;191(3):341–6.
- [2] Gonzales-Portillo F, Bruno A, Biller J. Outcome of extracranial cervicocephalic arterial dissections: a follow-up study. *Neurol Res* 2002;24(4):395–8.
- [3] Alleyne CH, Vishteh AG, Spetzler RF. Traumatic carotid injury. In: Winn HR, editor. *Youman's Neurological Surgery*. Fifth ed. Philadelphia: W.B. Saunders; 2004. p. 1669–76.
- [4] Fakhry SM, Jaques PF, Proctor HJ. Cervical vessel injury after blunt trauma. *J Vasc Surg* 1988;8(4):501–8.
- [5] Martin RF, Eldrup-Jorgensen J, Clark DE, Bredenberg CE. Blunt trauma to the carotid arteries. *J Vasc Surg* 1991;14(6):789–93 [discussion 793–5].
- [6] Rubio PA, Reul Jr GJ, Beall Jr AC, Jordan Jr GL, DeBakey ME. Acute carotid artery injury: 25 years' experience. *J Trauma* 1974;14(11):967–73.
- [7] Unger SW, Tucker Jr WS, Mrdeza MA, Wellons Jr HA, Chandler JG. Carotid arterial trauma. *Surgery* 1980;87(5):477–87.

- [8] Schievink WI, Atkinson JL, Bartleson JD, Whisnant JP. Traumatic internal carotid artery dissections caused by blunt softball injuries. *Am J Emerg Med* 1998;16(2):179–82.
- [9] Trosch RM, Hasbani M, Brass LM. “Bottoms up” dissection. *N Engl J Med* 1989;320(23):1564–5.
- [10] Weintraub MI. Beauty parlor stroke syndrome: report of five cases. *JAMA* 1993;269(16):2085–6.
- [11] Davis JM, Zimmerman RA. Injury of the carotid and vertebral arteries. *Neuroradiology* 1983;25(2):55–69.
- [12] Hart RG, Easton JD. Dissections of cervical and cerebral arteries. *Neurol Clin* 1983;1(1):155–82.
- [13] Levy RL, Dugan TM, Bernat JL, Keating J. Lateral medullary syndrome after neck injury. *Neurology* 1980;30(7 Pt 1):788–90.
- [14] Peters M, Bohl J, Thomke F, Kallen KJ, Mahlzahl K, Wandel E, et al. Dissection of the internal carotid artery after chiropractic manipulation of the neck. *Neurology* 1995;45(12):2284–6.
- [15] Schellhas KP, Latchaw RE, Wendling LR, Gold LH. Vertebrobasilar injuries following cervical manipulation. *JAMA* 1980;244(13):1450–3.
- [16] Jackson MA, Hughes RC, Ward SP, McInnes EG. “Headbanging” and carotid dissection. *Br Med J (Clin Res Ed)* 1983;287(6401):1262.
- [17] Mourad JJ, Girerd X, Safar M. Carotid-artery dissection after a prolonged telephone call. *N Engl J Med* 1997;336(7):516.
- [18] Wiebers DO, Mokri B. Internal carotid artery dissection after childbirth. *Stroke* 1985;16(6):956–9.
- [19] Caplan LR, Zarins CK, Hemmati M. Spontaneous dissection of the extracranial vertebral arteries. *Stroke* 1985;16(6):1030–8.
- [20] Fisher CM, Ojemann RG, Roberson GH. Spontaneous dissection of cervico-cerebral arteries. *Can J Neurol Sci* 1978;5(1):9–19.
- [21] Gould DB, Cunningham K. Internal carotid artery dissection after remote surgery. Iatrogenic complications of anesthesia. *Stroke* 1994;25(6):1276–8.
- [22] Mokri B, Sundt Jr TM, Houser OW. Spontaneous internal carotid dissection, hemiparesis, and Homer’s syndrome. *Arch Neurol* 1979;36(11):677–80.
- [23] Norris JW, Beletsky V, Nadareishvili ZG. Sudden neck movement and cervical artery dissection. The Canadian Stroke Consortium. *CMAJ* 2000;163(1):38–40.
- [24] Schievink WI. Spontaneous dissection of the carotid and vertebral arteries. *N Engl J Med* 2001;344(12):898–906.
- [25] Crissey MM, Bernstein EF. Delayed presentation of carotid intimal tear following blunt craniocervical trauma. *Surgery* 1974;75(4):543–9.
- [26] Mulloy JP, Flick PA, Gold RE. Blunt carotid injury: a review. *Radiology* 1998;207(3):571–85.
- [27] Jernigan WR, Gardner WC. Carotid artery injuries due to closed cervical trauma. *J Trauma* 1971;11(5):429–35.
- [28] Parikh AA, Luchette FA, Valente JF, Johnson RC, Anderson GL, Blebea J, et al. Blunt carotid artery injuries. *J Am Coll Surg* 1997;185(1):80–6.
- [29] Cogbill TH, Moore EE, Meissner M, Fischer RP, Hoyt DB, Morris JA, et al. The spectrum of blunt injury to the carotid artery: a multicenter perspective. *J Trauma* 1994;37(3):473–9.
- [30] Link J, Brossmann J, Penselin V, Gluer CC, Heller M. Common carotid artery bifurcation: preliminary results of CT angiography and color-coded duplex sonography compared with digital subtraction angiography. *AJR Am J Roentgenol* 1997;168(2):361–5.
- [31] Yamada S, Kindt GW, Youmans JR. Carotid artery occlusion due to nonpenetrating injury. *J Trauma* 1967;7(3):333–42.
- [32] Fabian TC, Patton Jr JH, Croce MA, Minard G, Kudsk KA, Pritchard FE. Blunt carotid injury. Importance of early diagnosis and anticoagulant therapy. *Ann Surg* 1996;223(5):513–22 [discussion 522–5].
- [33] Biller J, Hingtgen WL, Adams Jr HP, Smoker WR, Godersky JC, Toffol GJ. Cervicocephalic arterial dissections. A ten-year experience. *Arch Neurol* 1986;43(12):1234–8.
- [34] Vishteh AG, Marciano FF, David CA, Schievink WI, Zabramski JM, Spetzler RF. Long-term graft patency rates and clinical outcomes after revascularization for symptomatic traumatic internal carotid artery dissection. *Neurosurgery* 1998;43(4):761–7 [discussion 767–8].
- [35] Liu AY, Paulsen RD, Marcellus ML, Steinberg GK, Marks MP. Long-term outcomes after carotid stent placement treatment of carotid artery dissection. *Neurosurgery* 1999;45(6):1368–73 [discussion 1373–4].
- [36] Hankey GJ. *Stroke Treatment and Prevention: An Evidence-based Approach*; 2005.