

COL4A1 Mutation in a Patient With Sporadic, Recurrent Intracerebral Hemorrhage

Katayoun Vahedi, MD; Nathalie Kubis, MD, PhD; Monique Boukobza, MD; Minh Arnoult, MD, PhD; Pascale Massin, MD; Elisabeth Tournier-Lasserre, MD; Marie-Germaine Bousser, MD

Background and Purpose—Recently *COL4A1*, a gene encoding the type IV collagen $\alpha 1$ chain, has been found to be involved in families with autosomal-dominant porencephaly and infantile hemiparesis. In addition to neonatal stroke, some family members had experienced, during adulthood, spontaneous intracerebral hemorrhages (ICHs) and leukoencephalopathy, suggestive of underlying small-vessel disease of the brain. We now report a patient with sporadic, recurrent ICHs and a novel *COL4A1* mutation.

Methods—We performed a clinical and genetic study of a 25-year-old-patient with an 8-year history of recurrent ICHs.

Results—This young, normotensive patient with a history of infantile hemiparesis had experienced, since the age of 17, recurrent, spontaneous, deep ICHs occurring during sports activities. He became severely disabled. Brain magnetic resonance imaging showed ventricular enlargement, diffuse white-matter abnormalities, and newly appearing, deep, silent microbleeds. Extensive investigations found no cause. There was no family history of stroke or infantile hemiparesis. A novel *COL4A1* mutation (G805R) was identified.

Conclusions—The clinical spectrum of *COL4A1* mutations includes recurrent ICHs in association with diffuse leukoencephalopathy in young adults, even in the absence of a family history of infantile hemiparesis or ICH. In addition to birth trauma, anticoagulant use, and head trauma previously reported, sports activities may be a precipitating factor of ICHs in persons with *COL4A1* mutations. (*Stroke*. 2007;38:1461-1464.)

Key Words: intracerebral hemorrhage ■ genetics ■ white matter ■ young adults

Infantile hemiparesis (congenital hemiplegia, or hemiparetic cerebral palsy) is considered the consequence of perinatal stroke. The prevalence of perinatal stroke for infants <30 days of age is estimated to be 1 in 4000 live births, with approximately two thirds ischemic and one third hemorrhagic.¹ The underlying mechanisms of infantile hemiparesis are heterogeneous. Intrauterine growth restriction, preeclampsia, chorioamnionitis, systemic infection, birth asphyxia, prolonged rupture of membranes, cord abnormalities, and cardiac and coagulation disorders have all been reported as risk factors.¹⁻³ However, infantile hemiparesis can occur after normal pregnancy and normal birth. Families with infantile hemiparesis and autosomal-dominant porencephaly have also been reported.⁴ Recently, a new mouse mutant that develops fatal perinatal hemorrhage and porencephaly has been identified with a mutation in *Col4a1*, a gene that encodes the type IV collagen $\alpha 1$ chain.⁵ Mutant *Col4a1* mice have structural alterations of the vascular basement membrane in the brain and other tissues. Recent studies have shown that mutations in *COL4A1* on chromosome 13q34 are involved in human

families with infantile hemiparesis and porencephaly.⁵⁻⁷ Interestingly, some mutant mice had, depending on their genetic background, a highly tortuous retinal vasculature in addition to perinatal hemorrhage and porencephaly.⁸ This retinal phenotype has been previously associated with familial infantile hemiparesis in a French family that was shown to have a *COL4A1* mutation.^{8,9} *COL4A1* also plays a role in intracranial hemorrhage (ICH) during adulthood in the mouse and in humans.^{8,10}

Herein we describe a novel *COL4A1* mutation in a young patient with a history of infantile hemiparesis who experienced, during adulthood, sporadic, recurrent ICHs associated with diffuse white-matter abnormalities.

Subjects and Methods

A 25-year-old male with infantile hemiparesis and recurrent ICHs and his 45-year-old mother were examined. Family history was obtained from the mother. Genomic DNA was extracted from white blood cells of the proband and his mother. Each of the 52 coding exons of the *COL4A1* gene was amplified (oligonucleotides and conditions available on request from E.T.-L.). Direct sequencing of

Received October 10, 2006; final revision received October 24, 2006; accepted November 1, 2006.

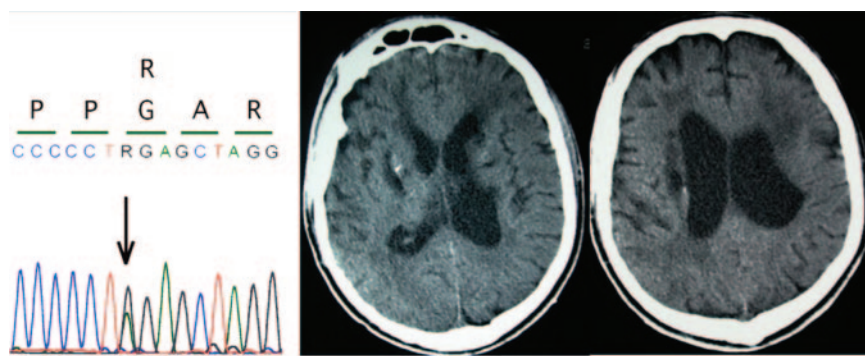
From AP-HP, Service de Neurologie (K.V., N.K., M.G.B.), Centre de Référence pour les Maladies Vasculaires Rares du Système Nerveux Central et de la Rétine (K.V., M.B., P.M., E.T.-L., M.G.B.), and Physiologie-Explorations Fonctionnelles (N.K.), Hôpital Lariboisière, Paris; INSERM U689 (N.K.), Université Paris VII, Paris; AP-HP, Service de Neuroradiologie (M.B.), Hôpital Lariboisière; Paris; INSERM U740 (M.A., E.T.-L., M.G.B.), Université Paris VII, Paris; and AP-HP, Service d'Ophthalmologie (P.M.) and Laboratoire de Cytogénétique (E.T.-L.), Hôpital Lariboisière, Paris, France.

Correspondence to Katayoun Vahedi, MD, AP-HP, Service de Neurologie, Hôpital Lariboisière, 2 rue Ambroise Paré, 75010 Paris, France. E-mail katayoun.vahedi@lrh.aphp.fr

© 2007 American Heart Association, Inc.

Stroke is available at <http://www.strokeaha.org>

DOI: 10.1161/STROKEAHA.106.475194



both strands was performed on an ABI3700 automated sequencing apparatus. Informed consent was obtained from the mother. Fifty DNA samples from healthy individuals were available as a control panel.

Results

Clinical Data

The proband is a 25-year-old man with no remarkable perinatal event except for a postterm forceps delivery. At 3 months of age, the mother first noticed right-sided weakness. Later he developed right-sided hemiatrophy and hand dystonia. Infantile hemiparesis was diagnosed, but he had normal intellectual development. At the age of 17 years, he experienced his first episode of sudden dysarthria during jogging. Brain CT and MRI showed a recent, right lenticular hemorrhage; diffuse, bilateral, white-matter abnormalities; and left lateral ventricle enlargement. Blood pressure was 125/85. Four-vessel cerebral angiography and transesophageal echocardiography disclosed no abnormalities. Extensive biologic investigations, including complete blood count, serum electrolytes, creatinine, liver enzymes, serum and urinary homocysteine, coagulation tests, anticardiolipids, and lupus anticoagulant, were all in the normal range. In addition, albumin urinary concentration was normal with no hematuria. Screening for all coding exons of *KRIT1*, the sole cerebral cavernous malformation gene known at that time, was negative (oligonucleotides and screening conditions available on request from E.T.-L.). At the age of 18, he had a left eye injury with a posterior retinal hemorrhage and then developed a traumatic cataract. Between the ages of 19 and 21, the patient had 3 recurrent episodes of a sudden worsening of dysarthria and right-sided hemiparesis at each time during sports activities. At each episode, a brain CT and MRI disclosed a new, deep ICH located in the internal capsule or the basal ganglia, multiple new microbleeds within the corpus callosum and midbrain on gradient-echo imaging, and a diffuse leukoencephalopathy. At age 22, he had a generalized seizure when swimming, leading to water inhalation and coma. Brain imaging evidenced a large, deep hematoma in the right basal ganglia with a mass effect and intraventricular hemorrhage.

After the last episode of ICH, the patient remained tetraparetic, totally bedridden, and dependent with pronounced generalized spasticity, severe dysphagia, emotional lability, and no verbal communication (modified Rankin scale=5). His 45-year-old mother was clinically asymptomatic, and her brain MRI examination was normal. She reported no family history of infantile hemiparesis, stroke, or retinal hemorrhage

COL4A1 mutation in the proband. Genomic DNA sequence analysis of *COL4A1* revealed a G805R mutation within exon 31 (left panel). This mutation led to the replacement of 1 of the highly conserved glycine residues of the triple-helix domain of *COL4A1* and was not present in 50 control DNA samples. Brain CT (right panels) at age 23 shows bilateral ventricular dilatation, diffuse cortical and left skull atrophy, diffuse white-matter abnormalities, and multiple, deep, hypodense lesions surrounded by punctiform calcifications suggesting vascular cavities.

among the proband's father (of Italian ascent), 18-year-old sister, and grandparents.

COL4A1 Gene Screening

Genomic DNA sequence analysis revealed in this patient a G2413A transition within exon 31 (the Figure). This mutation changed a glycine amino acid to an arginine (G805R) within the triple-helix domain of *COL4A1*. This mutation was not detected in the control panel and was absent in his healthy mother.

Discussion

Herein we report a patient with a novel *COL4A1* mutation who had experienced, since age 17, recurrent, sporadic, deep ICHs leading to severe disability and total dependence at age 22. This *COL4A1* mutation affects a highly conserved glycine residue involved in repeated Gly-Pro-X motifs within the triple helix, and their mutation has been shown to be pathogenic both in *COL4A1* and in various collagen genes.

There are several remarkable particularities in this patient: (1) the early age of onset of ICH; (2) the deep locations of the ICHs and asymptomatic microbleeds; (3) the high frequency of recurrence over a short period of time; (4) the triggering of ICH by sports activities without head trauma; (5) the absence of any cause, including the absence of hypertension; (6) the past history of infantile hemiparesis; and (7) the associated diffuse leukoencephalopathy.

Among genetic vascular malformations that eventually cause recurrent ICHs, cerebral cavernous angiomas were ruled out in this patient on the basis of MRI, which did not show the typical patterns of cerebral cavernous angiomas and revealed diffuse, white-matter abnormalities not typically encountered in cerebral cavernous angiomas. In addition, screening of *KRIT1* showed no mutation.

The clinical phenotype of deep, recurrent ICHs, leukoencephalopathy, and infantile hemiparesis led us to consider *COL4A1* as a candidate gene in this young, normotensive patient. All 5 recently reported families with *COL4A1* mutations had an autosomal-dominant porencephaly and infantile hemiparesis but with incomplete penetrance, suggesting the possibility of sporadic cases (Table 1).^{6,7,10} Among the reported families, variations in the phenotypes of *COL4A1* mutations were noted, including ICHs during adulthood, diffuse leukoencephalopathy on brain imaging, and retinal arteriolar tortuosity, even in the absence of infantile hemiparesis or congenital porencephaly. There is so far no

TABLE 1. Reported Clinical and Imaging Data in 19 Patients With *COL4A1* MUTATIONS^{5,7,9,10}

		No. of Patients/Total of Patients With Data
Neurologic manifestations	Porencephaly and infantile hemiparesis	13/19
	Reported perinatal events	3/19 (postterm pregnancy in 2, protracted duration of expulsion in 1)
	Slight to moderate mental retardation	7/19
	Seizures in childhood	4/19
	ICH in adulthood	5/19
	Migraine	5/19 (migraine with aura in 3)
Neuroradiologic abnormalities	Leukoencephalopathy on brain MRI or CT	16/19
	Porencephaly without infantile hemiparesis	2/19
	Silent microbleeds on gradient-echo MRI	2/4
Ophthalmologic manifestations	Retinal arteriolar tortuositities	5/8
	Retinal hemorrhage	2/7 (traumatic in 1)
Other clinical manifestations	Cataract	3/19 (traumatic in 1)
	Hematuria	1/19

pathology study of the cerebral vessels in patients with *COL4A1* mutations. Endothelial cell basement membrane abnormalities of skin capillaries with focal interruptions or increased thickness have been reported in a patient with *COL4A1* mutations and recurrent and disabling ICHs in adulthood.¹⁰ Abnormalities of the basement membrane of cerebral vessels have also been noted in *col4a1*-mutant mice by electron microscopy.⁵ All of these data suggest that *COL4A1* mutations cause generalized small-vessel disease with particular involvement of the brain vessels. Herein we report the first sporadic patient with *COL4A1* mutation and enlarge the phenotypic spectrum of *COL4A1* mutation to early-onset sporadic, recurrent, and disabling deep ICHs. In our patient, sports activity, in addition to birth trauma, brain trauma, and use of oral anticoagulants previously reported, may have been a precipitating factor of the ICHs associated with the *COL4A1* mutation.

Ophthalmologic manifestations of *COL4A1* mutations include cataract, spontaneous or traumatic retinal hemorrhage, and retinal arteriolar tortuositities present in 5 of 8 patients previously reported with *COL4A1* mutations who underwent fundus examination.^{9,10} It is interesting to note that, depending on their genetic background, some but not all *col4a1*-mutant mice had retinal vascular tortuositities.⁸ Retinal arteriolar tortuositities have also been found in a family without porencephaly but with leukoencephalopathy, hematuria, and renal insufficiency.¹¹ Whether the *COL4A1* gene is also involved in this family is not yet known. Type IV collagen is

an essential component of the glomerular basement membrane. Hematuria has been rarely reported in patients with *COL4A1* mutations (Table 1) but was not found in our patient.

Because of the lack of pathognomonic neurologic symptoms, specific brain MRI abnormalities, and the possibility of asymptomatic gene carriers and sporadic cases, patients with *COL4A1* mutations may be underdiagnosed. Considering our data and the previously reported families with *COL4A1* mutations, at least 1 of the following arguments should prompt *COL4A1* genetic screening in young patients with deep ICHs of undetermined etiology: (1) a personal or family history of infantile hemiparesis or congenital porencephaly, (2) leukoencephalopathy with silent microbleeds in the absence of hypertension, and (3) the presence of retinal arteriolar tortuositities. Genetic counseling of at-risk young women planning to become pregnant is of major importance, because cesarean delivery should be recommended to try to prevent vascular injury attributable to birth trauma. In at-risk adults, sustained physical activity or sports activities that may cause head trauma should be avoided, and anticoagulant use should be strictly monitored.

COL4A1 mutation features are distinct from those of other known genetic small-vessel diseases of the brain, as congenital hemiplegia and perinatal stroke are not features of cerebral amyloid angiopathy or CADASIL, although silent microbleeds on gradient-echo imaging have been frequently associated with both cerebral amyloid angiopathy and CADASIL (Table 2).¹²⁻¹⁴

In conclusion, *COL4A1* mutations have a wide clinical spectrum, including recurrent and disabling ICHs in young adults, even in the absence of any family history of infantile hemiparesis or stroke. Further studies will be needed to determine the frequency of *COL4A1* mutations and the mechanisms by which they lead to hemorrhagic strokes and leukoencephalopathy.

Acknowledgment

The authors thank Stéphane Chabrier for the critical comments on the manuscript.

TABLE 2. Main Features of *COL4A1* Mutations, CADASIL (*NOTCH3* Mutations), and Hereditary Amyloid Angiopathy (CAA)

	<i>COL4A1</i>	CADASIL (<i>NOTCH3</i>)	CAA
Neonatal stroke (infantile hemiparesis, porencephaly)	Yes	No	No
ICH	Yes	Rare	Yes
Cerebral infarcts	Uncertain	Yes	Rare
Leukoencephalopathy	Yes	Yes	Yes
Silent microbleeds	Yes	Yes	Yes

Disclosures

None.

References

- Lynch JK, Nelson KB. Epidemiology of perinatal stroke. *Curr Opin Pediatr.* 2001;13:499–505.
- Lee J, Croen LA, Lindan C, Nash KB, Yoshida CK, Ferriero DM, Barkovich AJ, Wu YW. Predictors of outcome in perinatal arterial stroke: a population-based study. *Ann Neurol.* 2005;58:303–308.
- Sherer DM, Anyaegbunam A, Onyeije C. Antepartum fetal intracranial hemorrhage, predisposing factors and prenatal sonography: a review. *Am J Perinatal.* 1998;15:431–441.
- Mancini GM, de Coo IF, Lequin MH, Arts WF. Hereditary porencephaly: clinical and MRI findings in two Dutch families. *Eur J Paediatr Neurol.* 2004;8:45–54.
- Gould DB, Phalan FC, Breedveld GJ, van Mil SE, Smith RS, Schimenti JC, Aguglia U, van der Knaap MS, Heutink P, John SW. Mutations in *Col4a1* cause perinatal cerebral hemorrhage and porencephaly. *Science.* 2005;308:1167–1171.
- Aguglia U, Gambardella A, Breedveld GJ, Oliveri RL, Le Piane E, Messina D, Quattrone A, Heutink P. Suggestive evidence for linkage to chromosome 13qter for autosomal dominant type 1 porencephaly. *Neurology.* 2004;62:1613–1615.
- Breedveld G, de Coo IF, Lequin MH, Arts WF, Heutink P, Gould DB, John SW, Oostra B, Mancini GM. Novel mutations in three families confirm a major role of *COL4A1* in hereditary porencephaly. *J Med Genet.* 2005;10:1136.
- Gould DB, Phalan FC, van Mil SE, Sundberg JP, Vahedi K, Massin P, Bousser MG, Heutink P, Miner JH, Tournier-Lasserre E, John SW. Role of *COL4A1* in small-vessel disease and hemorrhagic stroke. *N Engl J Med.* 2006;354:1489–1496.
- Vahedi K, Massin P, Guichard JP, Miocque S, Polivka M, Goutieres F, Dress D, Chapon F, Ruchoux MM, Riant F, Joutel A, Gaudric A, Bousser MG, Tournier-Lasserre E. Hereditary infantile hemiparesis, retinal arteriolar tortuosity, and leukoencephalopathy. *Neurology.* 2003;60:57–63.
- van der Knaap MS, Smit LM, Barkhof F, Pijnenburg YA, Zweegman S, Niessen HW, Imhof S, Heutink P. Neonatal porencephaly and adult stroke related to mutations in collagen IV A1. *Ann Neurol.* 2006;59:504–511.
- Plaisier E, Alamowitch S, Gribouval O, Mougnot B, Gaudric A, Antignac C, Roulet E, Ronco P. Autosomal dominant familial hematuria with retinal arteriolar tortuosity and contractures: a novel syndrome. *Kidney Int.* 2005;67:2354–2360.
- Chabriat H, Vahedi K, Iba-Zizen MT, Joutel A, Nibbio A, Nagy TG, Krebs MO, Julien J, Dubois B, Ducrocq X, Levasseur M, Homeyer P, Mas JL, Lyon-Caen O, Tournier-Lasserre E, Bousser MG. Clinical spectrum of CADASIL: a study of 7 families. *Lancet.* 1995;346:934–939.
- Viswanathan A, Guichard JP, Gschwendtner A, Buffon F, Cumurcuic R, Boutron C, Vicaut E, Holtmannspotter M, Pachai C, Bousser MG, Dichgans M, Chabriat H. Blood pressure and haemoglobin A1c are associated with microhaemorrhage in CADASIL: a two-centre cohort study. *Brain.* 2006;129:2375–2383.
- Greenberg SM, Gurol ME, Rosand J, Smith EE. Amyloid angiopathy-related vascular cognitive impairment. *Stroke.* 2004;35(suppl 1):2616–2619.

COL4A1 Mutation in a Patient With Sporadic, Recurrent Intracerebral Hemorrhage
Katayoun Vahedi, Nathalie Kubis, Monique Boukobza, Minh Arnoult, Pascale Massin,
Elisabeth Tournier-Lasserre and Marie-Germaine Bousser

Stroke. 2007;38:1461-1464; originally published online March 22, 2007;
doi: 10.1161/STROKEAHA.106.475194

Stroke is published by the American Heart Association, 7272 Greenville Avenue, Dallas, TX 75231
Copyright © 2007 American Heart Association, Inc. All rights reserved.
Print ISSN: 0039-2499. Online ISSN: 1524-4628

The online version of this article, along with updated information and services, is located on the
World Wide Web at:

<http://stroke.ahajournals.org/content/38/5/1461>

Permissions: Requests for permissions to reproduce figures, tables, or portions of articles originally published in *Stroke* can be obtained via RightsLink, a service of the Copyright Clearance Center, not the Editorial Office. Once the online version of the published article for which permission is being requested is located, click Request Permissions in the middle column of the Web page under Services. Further information about this process is available in the [Permissions and Rights Question and Answer](#) document.

Reprints: Information about reprints can be found online at:
<http://www.lww.com/reprints>

Subscriptions: Information about subscribing to *Stroke* is online at:
<http://stroke.ahajournals.org/subscriptions/>