

Management of tinnitus induced by brainstem and cerebellar infarction associated with complications of cerebello-pontine angle surgery

S BREWIS, D M BAGULEY

Abstract

Following surgery in the USA in 1992 to remove a large right cerebello-pontine angle tumour, a 39-year-old woman developed severe brainstem and cerebellar infarction. This left her with severe visual impairment and ataxia. She became able to communicate by means of an adapted finger-spelling alphabet. She had total hearing loss in the right ear and a mild to moderately severe sensorineural hearing loss in the left ear, and severe tinnitus heard throughout the head. Additionally, she experienced hypersensitivity to sound above normal conversational levels, which evoked a synaesthetic feeling of coldness across her upper torso. Previous linear analogue hearing aid fitting had not been beneficial for either hearing or tinnitus. Careful fitting of a digital hearing aid, together with tinnitus counselling, inhibited the patient's tinnitus to 25 per cent of its former intensity after a six month acclimatisation period, and improved communication.

Key words: Tinnitus; Hearing Aid; Infarction; Brainstem

Patient history

In 1992, a 39-year-old woman, previously a professor of nursing, underwent a right posterior fossa craniotomy for total excision of a right cerebello-pontine angle meningioma, at a tertiary referral teaching hospital in the United States. Brainstem shift and ventricular enlargement were noted pre-operatively. The presenting symptoms included ataxia, imbalance and a profound sensorineural hearing loss in the right ear. No mention was made in the case notes of left-sided hearing loss or tinnitus.

Post-operatively, there were a number of complications which resulted in severe brainstem and cerebellar infarctions on the second post-operative day. The patient was left with numerous disabilities, which included severe visual impairment, ataxia and bilateral hearing loss. She had no useful hearing in her right ear and a mild to moderately severe sensorineural hearing loss in her left ear. In addition, she suffered severe tinnitus and reduced sound tolerance, both of which caused her very significant distress. She became able to communicate by means of an adapted version of the British deaf-blind hand-spelling alphabet.

After making slow progress with rehabilitation in the US, the patient was brought to the UK, where attempts were made at hearing rehabilitation in a UK hospital. A variety of analogue hearing aids were tried on the patient's left ear but she was unable to acclimatise to any of these. As a result, she rejected hearing aids completely and reverted back to attempting to communicate unaided.

Tinnitus and synaesthesia

The patient reported a variety of tinnitus sounds, using the descriptions 'rushing', 'hissing' and 'rattling'. These were

continuous and perceived 'all over the head' rather than being localised to any particular ear. Additionally, it was reported that sound of an intensity greater than that of conversational speech evoked a consistent and unpleasant sensation of 'coldness' across the patient's body, leading to reduced sound tolerance. This synaesthetic transfer between sound and temperature sensation has not to our knowledge been previously reported.

Hearing aid prescription and outcome

Following initial assessment and counselling, it was suggested that the patient trial a digital hearing aid, in an effort to simultaneously reduce her tinnitus and maximise the residual hearing in her left ear. Due to the patient's sound intolerance and previous problems with wearing hearing aids, a conservative approach to the programming of the aid was adopted.

On review following six months of hearing aid use, the patient reported that she was very happy with the sound of the hearing aid and did not want any changes made to it. Furthermore, there had been no problems with acoustic feedback or intolerance of loud sounds. In addition, she found that, whilst worn, the aid inhibited the intensity of her tinnitus by an estimated 75 per cent. Tinnitus intensity when the aid was removed was estimated to be reduced by 25 per cent. No change in the synaesthesia between hearing and temperature sensation was reported.

Mechanisms of tinnitus generation and inhibition

Several authors have proposed that tinnitus perception may arise due to spontaneous activity in reorganised areas of the auditory pathway following injury.^{1–5} This builds

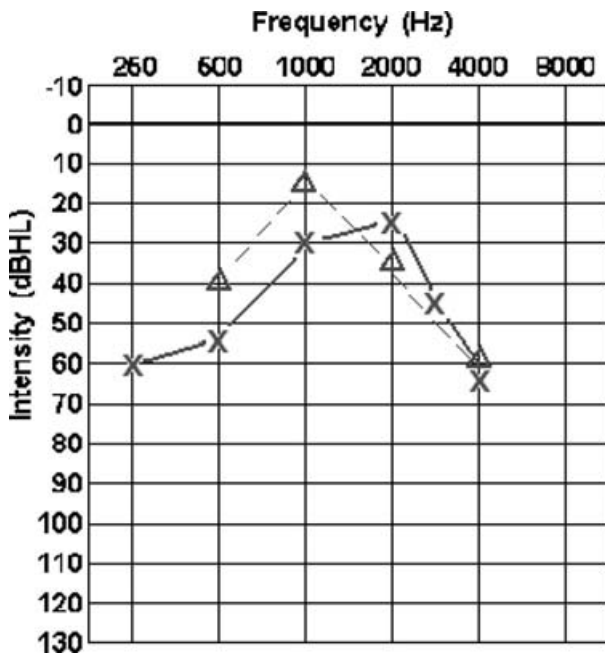


FIG. 1

Patient audiogram. No hearing is present in the right ear. X = air conduction thresholds, left ear; Δ = unmasked bone conduction thresholds.

upon an insightful analogy between tinnitus and phantom limb pain, which was first proposed by Goodhill in 1950.⁶ In the present patient, there were two potential drivers of reorganisation. First, the loss of afferent auditory input from the right ear. This situation has been reported to induce reorganisation in the contralateral auditory cortex, demonstrated by both functional magnetic resonance imaging⁷ and magnetic encephalography.⁸ Second, a process of reorganisation may have affected both auditory and non-auditory structures following the patient's infarct. It is this second process that may underlie the patient's synaesthesia between sound perception and temperature.

- Little is known about tinnitus rehabilitation following brainstem and cerebellar infarction
- This case study reports an audiological rehabilitation strategy, utilising a digital hearing aid with non-linear compression, which resulted in improved hearing and reduction of tinnitus intensity

Conclusions

The advantages of digital signal processing and non-linear hearing aid compression systems became apparent while

working with this patient. Previously, she had rejected amplification completely and had resigned herself to not being able to hear adequately. However, following the interventions described, the patient was able to hear speech comfortably, without the anxiety of unpleasant sounds and over-amplification. Furthermore, a very significant reduction in tinnitus intensity was achieved by the hearing aid.

Patients with multiple disabilities present very significant challenges to conventional tinnitus assessment and management procedures. However, by taking time to try to establish the exact needs of the patient, working within the patient's existing support system and being clinically creative, it is possible to set realistic goals and produce exciting results.

References

- 1 Meikle MB. The interaction of central and peripheral mechanisms in tinnitus. In: Vernon JA, Moller AR, eds. *Mechanisms of Tinnitus*. London: Allyn and Bacon, 1995;181–206
- 2 Salvi RJ, Lockwood AH, Burkard R. Neural plasticity and tinnitus. In: Tyler RS, ed. *Tinnitus Handbook*. San Diego: Singular, 2000;123–48
- 3 Salvi RJ, Wang J, Powers NL. Plasticity and reorganisation in the auditory brainstem: implications for tinnitus. In: Reich GE, Vernon JE, eds. *Proceedings of the Fifth International Tinnitus Seminar*. American Tinnitus Association, Portland, 1996. Portland Oregon, USA: Publisher American Tinnitus Association, 1996;457–66
- 4 Rauschecker JP. Auditory cortical plasticity: a comparison with other sensory systems. *Trends in Neuroscience* 1999; **22**:74–80
- 5 Irvine DRF, Rajan R, McDermott HJ. Injury-induced reorganization in adult auditory cortex and its perceptual consequences. *Hear Res* 2000;**147**:188–99
- 6 Goodhill V. The management of tinnitus. *Laryngoscope* 1950;**60**:442–50
- 7 Bilecen D, Seifritz E, Radu EW, Schmid N, Wetzel S, Probst R *et al*. Cortical reorganization after acute hearing loss traced by fMRI. *Neurology* 2000;**54**:765–7
- 8 Po-Hung Li L, Shiao AS, Lin YY, Chen LF, Niddam DM, Chang SY *et al*. Healthy-side dominance of cortical neuro-magnetic responses in sudden hearing loss. *Ann Neurol* 2003;**53**:810–15

Address for correspondence:
Dr D M Baguley,
Department of Audiology (94),
Addenbrooke's Hospital,
Hills Road, Cambridge CB2 2QQ, UK.

Fax: 01223 596101
E-mail: dmb29@cam.ac.uk

Dr D Baguley takes responsibility for the integrity of the content of the paper.

Competing interests: None declared