

NOTE

DIRECTIONAL DISORIENTATION FOLLOWING LEFT RETROSPLENIAL HEMORRHAGE: A CASE REPORT WITH FMRI STUDIES

Tadashi Ino¹, Toshiki Doi^{1, 3}, Syuichi Hirose¹, Toru Kimura¹, Jin Ito² and Hidenao Fukuyama³

(¹Department of Neurology, ²Department of Radiology, Rakuwakai-Otowa Hospital, Kyoto, Japan; ³Department of Functional Brain Imaging, Human Brain Research Center, Kyoto University Graduate School of Medicine, Kyoto, Japan)

ABSTRACT

We report a 55 year-old right-handed man who presented with topographical disorientation following left retrosplenial hemorrhage. His directional information about familiar places, encoded by previous navigation, was severely impaired, and he could not learn the direction to new places in large-scale spaces beyond the range of visual surveillance. By contrast, he had no difficulties with directional information encoded in a tabletop manner: he could locate major cities or countries on a map, and he also could memorize the spatial relationship of objects in a room. Six months after the ictus, when he had recovered from his directional disorientation, a functional magnetic resonance imaging (fMRI) study of mental navigation demonstrated prominent activation in the retrosplenial area along the right parieto-occipital sulcus and the circumference of the injured area on the left side. The present study, together with previous investigations including clinical case reports, functional neuroimaging, and anatomical and physiological studies on monkeys, suggests that the 'sense of direction' in a large-scale locomotor environment is subserved by the visual area along the parieto-occipital sulcus, and that bilateral deterioration of this function causes directional disorientation.

Key words: directional disorientation, navigation, parieto-occipital sulcus, V6A, fMRI

INTRODUCTION

Deficits of way-finding, often called topographical disorientation, are caused by cognitive disturbances such as agnosia for landmark information, difficulty in learning new spatial information, and the inability to recall directional information (Farrell, 1996; Aguirre and D'Esposito, 1999). There are relatively few reports of cases belonging to the last category, directional or heading disorientation, and the majority of them suffered from lesions in the retrosplenial area (Obi et al., 1992; Takahashi et al., 1997; Aguirre and D'Esposito, 1999; Katayama et al., 1999; Alsaadi et al., 2000; Maguire, 2001). Functional neuroimaging studies involving navigation or orientation in large-scale spaces have also shown that the retrosplenial area is activated during the task (Aguirre et al., 1996, 1998; Ghaem et al., 1997; Maguire et al., 1997, 1998; Burgess et al., 2001b; for review, see Maguire, 2001). We observed that the activated peak during a mental navigation task is located in the anterior bank of the parieto-occipital sulcus (APO), where newly defined visual areas (V6 and V6A) have been identified in monkeys (Covey et al., 1982; Colby et al., 1988; Galletti et al., 1991, 1993), and we have proposed that APO may be related to the transformation of allocentric coordinates to egocentric coordinates during the mental navigation task (Ino et al., 2002). A similar suggestion was made by Burgess et al. (2001a), who hypothesized that neurons in the posterior parietal cortex translate egocentric representations encoded in the medial

parietal area into allocentric representations encoded in the medial temporal lobe and vice versa. In this paper, we report a case of directional or heading disorientation following left retrosplenial hemorrhage, with an fMRI study of the patient's brain activation during a mental navigation task.

CASE REPORT

On the evening of December 11th, 2000, a 55 year-old right-handed man with a history of hypertension, who had been working as a taxicab driver in Kyoto City for 10 years, suddenly lost his knowledge of the route to his house while returning home after work. He could recognize buildings and the landscape and therefore understand where he was, but the landmarks that he recognized did not provoke directional information about any other places with respect to those landmarks. Consequently, he could not determine which direction to proceed to go home. He telephoned his wife and successfully returned home by her instructions. The next morning, he was still disoriented to the direction of familiar places and was brought by his wife to our hospital.

He was found to be neurologically alert, and neither motor paresis nor sensory disturbance was present. His visual acuity was normal except for partial right homonymous hemianopsia. Neuropsychologically he was severely disoriented as to the direction of familiar places. He was unable to determine the direction to familiar destinations

within the city with respect to his position at our hospital, although he had often visited this hospital while transporting passengers. He was also unable to describe or draw routes between his home and familiar places in his town, and could not draw the layout of his house. On the other hand, his topographical orientation with regard to locations previously learned in a tabletop or map-like manner were preserved: he could locate major cities such as Tokyo on a map of Japan and major places such as Hawaii on a world map. He also could describe the compass direction from one familiar place to another, both in Japan (e.g., Tokyo is east of Osaka) and around the world (e.g., Australia is south of Japan). He could recognize and identify everyday articles, familiar faces, buildings and landscapes. He exhibited no difficulty in reaching for objects or in manipulating them, and there was no right-left confusion between his own limbs or between those of the examiner's. He could accurately perform line bisections and copy model drawings. His digit span was normal (7 forward, 4 backward). On the Benton Visual Reproduction test, he gave 8 correct and 3 error responses. By contrast, he could recall none of three words after 30 sec of distraction consisting of simple calculations, and he could recall only one of ten associated word-pairs following auditory presentation. Retrograde memory disturbance was not noted, and his remote episodic memory was not disturbed. Thus, his anterograde verbal learning was disturbed whereas other memory functions such as verbal immediate memory, visual memory and remote episodic memory appeared normal. His score for Raven's colored matrices was 30. He was right-handed and judged to have an L.Q. of + 90 by the Japanese version of the Edinburgh handedness inventory (Oldfield, 1971).

A computed tomography (CT) scan revealed a high-density area in the left retrosplenial region, and thus he was admitted to our hospital for further neuroradiological examination. Cerebral angiography obtained three days after admission revealed no vascular abnormality and a contrast enhanced MRI obtained four days after admission revealed no lesions except for the hemorrhage in the

left retrosplenial region. A single photon emission computed tomography (SPECT) scan using ^{99m}Tc -ethyl cysteinyl dimer (ECD) obtained seven days after admission showed decreased perfusion in the left parietal region. A functional magnetic resonance imaging (fMRI) study performed 19 days after onset showed that the dominant hemisphere for language was on the left side (see below).

He could remember the position of objects in a room; when queried with his eyes closed, he could show without difficulty the direction of objects such as the door and window. On the other hand, when he moved through a path with turns, he found it difficult to indicate the direction of the starting point. He was unable to remember the route between his room and the lavatory, which involved two right turns and one left turn, during several days of hospitalization. He was trained in the rehabilitation room every day with the aim of recovering from the topographical disorientation and, around the twenty days after admission, he could travel back-and-forth between his room and the rehabilitation room, whose routes involved five turns. During admission, he was examined by a standard test for agnosia in Japan, the Visual Perception Test for Agnosia (VPTA, 1997, edited by the Japanese Society of Aphasiology). This test evaluates basic visual perception such as the evaluation of length and slope of a line; perception of objects as measured by naming and copying; recognition of faces as measured by the identification of familiar faces and differentiation of unfamiliar faces; perception of color assessed by naming, pointing and classifying; perception of symbols as measured by reading characters and naming map symbols; and operating or manipulating visual spaces such as bisection of a line. The patient performed normally on all aspects of the VPTA. His only consistent failure was directional disorientation in large-scale locomotor environments.

The patient's neuropsychological test results during admission are shown in Table I. After discharge, he visited our hospital at the outpatient clinic for treatment of his hypertension every month and reported that his directional disorientation was gradually improving. Six months after onset, when

TABLE I
Neuropsychological test performance

Test	Time after onset	Score
Wechsler adult intelligent scale		
Verbal IQ	7 days	98
Performance IQ	7 days	105
Full scale IQ	7 days	102
Raven's coloured progressive matrices	1 day	30
Benton Visual Reproduction test		
Correct	1 day	8
Error	1 day	3
Digit span forward	1 day	7
Digit span backward	1 day	4
Recall of 10 associated word-pairs	1 day	1
	12 days	4
Recall of three words after 30 sec distraction	1 day	0
	12 days	1

he was able to perform our mental navigation task (Ino et al., 2002, see below), he was examined with fMRI during this task. He performed the task exactly like a normal volunteer.

fMRI STUDY

Two fMRI studies were performed after the patient was given a complete explanation of the study and in turn gave his informed consent. The first study was carried out to determine the dominant side for language 19 days after onset, and the second study was conducted to disclose the activated regions during the mental navigation task six months after onset, when he had recovered from directional disorientation. In both studies, he was scanned with his eyes covered by an eye mask, and no output was required during the scans to minimize head motions. Gradient echo, single shot, echo-planar images (EPIs) were obtained from 16 axial slices utilizing a 1.5 tesla Siemens Vision Plus with the following parameters: field of view (FOV) of 200×200 mm, 64×64 matrix, slice thickness of 6 mm, gap of 1.2 mm, echo time (TE) of 50 msec, flip angle of 90° , repetition time (TR) of 3.5 sec for the first fMRI and 5 sec for the second fMRI. A three-dimensional T1 weighted structural image was obtained for anatomical normalization (FOV of 220×220 mm, 256×256 matrix, slice thickness of 2 mm, TR of 11.6 msec, TE of 4.9 msec, and flip angle of 8°). The data were analyzed with Statistical Parametric Mapping (SPM99, The Wellcome Department of Cognitive Neurology, Institute of Neurology, University College London, UK). The first three image sets were discarded because of unsteady magnetization, and the remaining images were realigned to the first image using sinc interpolation for motion correction. T1 anatomical images were co-registered to the mean image of the EPIs, and then the EPIs were co-registered to the SPM T1 template using the same parameters obtained when normalizing the co-registered patient's T1-weighted image. Nonlinear transformation was applied to all images for spatial normalization to the Montreal Neurological Institute (MNI) space. The normalized images were subsequently smoothed with a 9 mm

full-width half-maximum (FWHM) Gaussian filter. Statistical parametric maps corresponding to a comparison between the task condition and control baseline were generated, and activated areas were regarded as significant if more than twenty contiguous voxels exceeded $p < .05$ with multiple comparison corrections. The anatomical localization of activated areas was determined by superimposition on the mean EPI image normalized to the MNI standard space.

The first fMRI study consisted of twenty-eight 21-sec blocks in which word generation blocks were alternated with control blocks, starting with the latter. At the beginning of each of word generation block, one category names cue (animal, fish, insect, flower, vegetable, furniture, vehicle, clothing, etc.) was given auditorily and the subject was asked to covertly generate the names of as many examples as possible until he heard 'stop'. This indicated the end of the word-generation epoch and the beginning of the control block, when he was asked to silently count numbers starting from 1 until he heard the next category name cue. Significantly activated regions during the word generation task compared to the control condition were the left ventrolateral/dorsolateral prefrontal cortex (PFC), left dorsal premotor area, left anterior PFC, medial frontal region, left inferior parietal lobule and right cerebellum (Table II, Figure 1). These results indicated that the dominant hemisphere for language was on the left side.

The design of the second fMRI study was identical to our previous report (Ino et al., 2002) and consisted of fifteen 30-sec blocks (2 stimuli per block, 15-sec ISI) in which mental navigation blocks were alternated with control blocks, starting with the latter. During the mental navigation block, the patient was given two names of familiar places in Kyoto City through an air-pressure headphone every 15 seconds and was required to mentally navigate from the first place to the second while counting how many times he successively turned right or left without phonation. During the control task, he was given two successive numbers consisting of three figures (e.g., 123, 124) every 15 seconds and was instructed to count mentally from the last number. Immediately after the fMRI scan, the correctness of

TABLE II
Regions activated during the word generation task

Anatomical area	Brodmann area	Side	MNI coordinates			t-value	Voxels
			X	Y	Z		
Ventrolateral PFC	45	L	-50	30	18	13.3	3364
	47	L	-52	20	-4	13.1	
Dorsolateral PFC	9	L	-50	14	38	13.0	
Dorsal premotor area	8	L	-34	16	48	11.7	
Anterior PFC	11	L	-38	58	-10	9.4	
Medial frontal region	8		-2	28	42	11.2	646
Inferior parietal lobule	40	L	-66	-36	32	7.2	31
Cerebellum		R	10	-84	12	8.1	649
		R	32	-82	6	7.8	

PFC: prefrontal cortex.

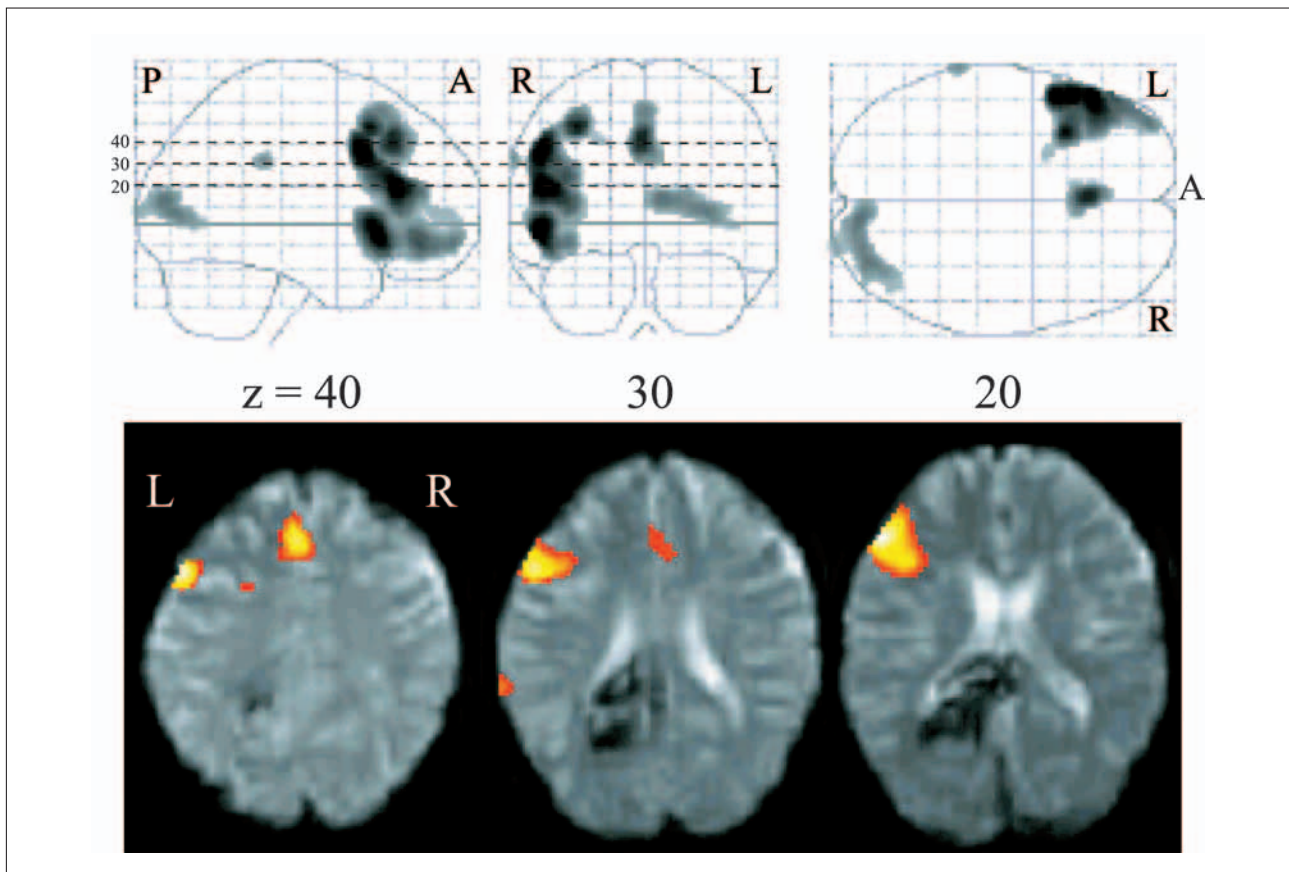


Fig. 1 – Regions significantly activated during the word generation task compared to the control ($k > 20$, $p < .05$, corrected for multiple comparison). This study was performed 19 days after onset.

Upper: Activated areas are displayed on a glass brain.

Lower: Axial images of the activation superimposed on the subject's mean EPI image normalized to the MNI standard space. Activation of the PFC is lateralized to the left side. The hemorrhage in the retrosplenial area caused signal loss in this region.

TABLE III
Regions activated during the mental navigation task

Anatomical area	Brodmann area	Side	MNI coordinates			t-value	Voxels
			X	Y	Z		
Superior parietal lobule	7	L	-16	-54	70	15.8	1154
	7	R	38	-66	52	8.1	105
Retrosplenial area		R	10	-46	26	11.9	1315
		L	-12	-52	24	8.0	
Dorsal premotor area	8	L	-26	24	54	11.2	270
Ventrolateral PFC	46	R	32	38	44	7.4	106
	46	L	-48	34	14	6.6	71

the covert responses during the fMRI examination was assessed by asking him to describe the routes on paper between the same places provided in the scanner. All of his responses were correct. Significantly activated regions during the mental navigation task compared to the control condition were the bilateral superior parietal lobule with left-side dominance, bilateral retrosplenial areas with right-side dominance, the left dorsal premotor area, and bilateral ventrolateral PFC (Table III, Figure 2). Activation in the left retrosplenial area was found along the circumference of the lesion site. As reported in our previous paper (Ino et al., 2002), to display activated blobs in the retrosplenial area more accurately, the realigned images were smoothed with

a 9 mm Gaussian filter and the contrast between mental navigation and the control task ($p < .05$ with multiple comparison corrections) was superimposed upon the subject's T1 anatomical image. Peaks of activation in the retrosplenial area were located in the anterior bank of the parieto-occipital sulcus (APO) (Figure 3).

DISCUSSION

Two types of navigation have been distinguished: dead reckoning and piloting (Farrell, 1996). Dead reckoning refers to the calculation of one's change in distance and direction from a known point,

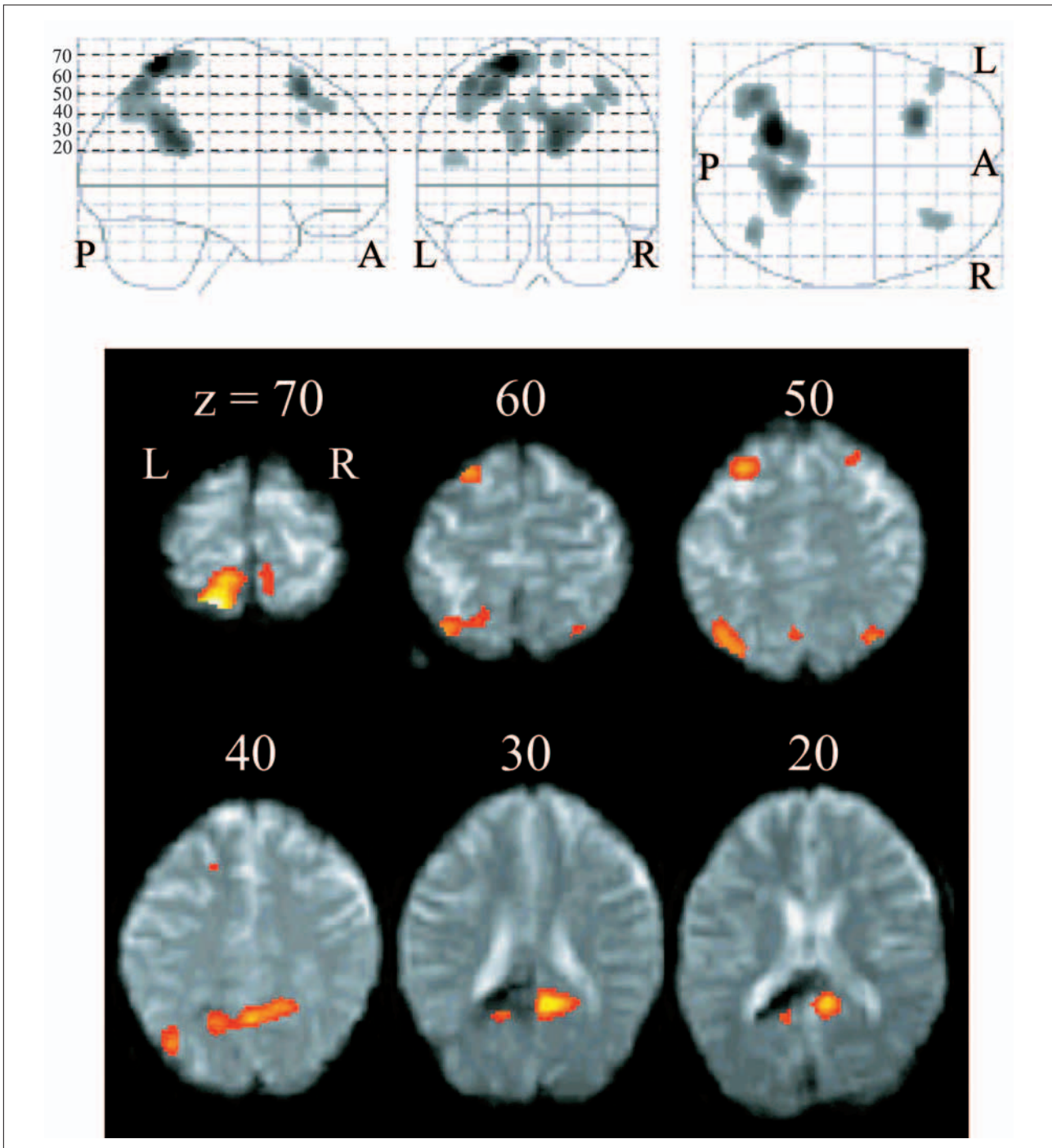


Fig. 2 – Regions significantly activated during mental navigation task compared to the control ($k > 20$, $p < .05$, corrected for multiple comparison). This study was carried out six months after onset.

Upper: Activated areas are displayed on a glass brain.

Lower: Axial images of the activation superimposed on the subject's mean EPI image normalized to the MNI standard space, showing bilateral activation of the retrosplenial area.

continuously updating one's position relative to this known position when it becomes briefly invisible. On the other hand, piloting refers to the computation of one's distance and direction relative to visible features in the environment, intermittently (when one sees a landmark) updating one's position relative to the landmark. Based on another point of view, navigation can be divided into egocentric and allocentric spatial processing (Wang and Spelke, 2000). Egocentric spatial processing maintains

egocentric representations of distance and direction from the landmark, updating these representations by vector summation as one moves, while allocentric spatial processing uses a cognitive map that encodes information about the geometric relationship between the goal and landmarks, updating one's position on the map as one moves. Egocentric spatial processing contributes to dead reckoning and piloting, and the conjunction of dead reckoning and piloting results in the formation of allocentric

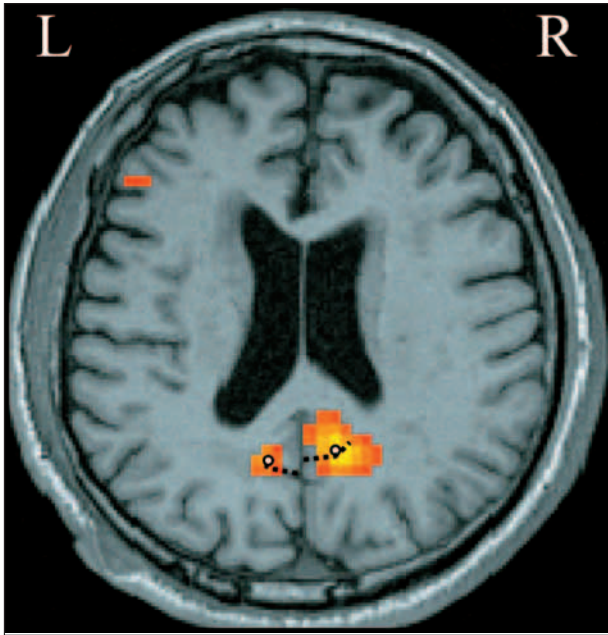


Fig. 3 – Axial images of the activation during the mental navigation task superimposed on the subject's anatomical image. The broken lines indicate the parieto-occipital sulcus and the open circles correspond to the peaks of activation.

representations by providing stable information on spatial relationships between locations. It has been suggested that lesions in the hippocampal system selectively impair allocentric spatial memory (O'Keefe and Nadel, 1978; Pearce et al., 1998; Holdstock et al., 2000). Although egocentric spatial processing is evolutionally older and inflexible when compared with allocentric spatial processing, it may predominate even in human navigation (Wang and Spelke, 2000; Shelton, 2001).

The most striking symptom of this patient was his topographical disorientation due to his inability to recall the direction traveled from one place to another in a familiar environment. He had lost spatial representations in the egocentric frame of reference since he was unable to determine the direction of any familiar destination with respect to his current position. He had also lost spatial representations in the allocentric frame of reference since any landmarks that he normally recognized failed to offer directional information on any other familiar place with respect to those landmarks. His survey perspective from a bird's eye view of the environment, learned by navigation, was also lost since he could not draw maps of familiar places in Kyoto City and could not draw the layout of his house. On the other hand, his spatial memory acquired in a tabletop or map-like manner was preserved since he could locate familiar places that he had never visited on a map of Japan or of the world. Thus, his disturbance of spatial memory was confined to route-based knowledge encoded by previously experienced navigation.

We previously reported that the retrosplenial area is the region of the most prominent activation

during our mental navigation task, and noted that this area is prominently activated during various navigation tasks such as route memorization in a large-scale virtual environment (Ino et al., 2002). Although precise anatomical localization is difficult to observe by an fMRI examination, the observation that peak activation in this area was consistently located in the APO of every subject examined suggests that APO is specialized for certain processes in the mental navigation task (Ino et al., 2002). This region is neither a posterior continuation of the parahippocampal gyrus such as the isthmus of the cingulate gyrus nor the retrosplenial cortex, which is buried in the callosal sulcus (Vogt et al., 2001). Recent anatomical and physiological investigations identified visual areas V6 and V6A in the APO of monkeys and indicated that neurons in these visual areas are sensitive to orientation and the direction of movement of visual stimuli (Covey et al., 1982; Colby et al., 1988; Galletti et al., 1991, 1993). In particular, V6A includes neurons which have a receptive field anchored to head-centered coordinates irrespective of eye movement. Furthermore, the pattern of the receptive field of V6A neurons is complex and some neurons are insensitive to visual stimuli (Galletti et al., 1999), suggesting that V6A neurons are related to higher order visual processing in egocentric coordinates. Based on these findings, we proposed that the APO, which is strongly activated during the mental navigation task, may be equivalent to V6A in monkeys and may subserve egocentric spatial processing (Ino et al., 2002). Takahashi et al. (1997) proposed that 'sense of direction', the ability to recall the positional relationship between one's current position and a destination within a wider space not surveyable at one time, is localized in the retrosplenial area. This 'sense of direction' may be identical to or included in egocentric spatial processing subserved by the APO in the retrosplenial area.

Our patient showed prominent activation in the retrosplenial area during the mental navigation task and the peak of this region was located in the APO (Figure 3), which is consistent with our previous study. Activation of the lesion site in the left hemisphere may have been underestimated by signal loss due to hemosiderin deposit. The peak of activation for our patient in the retrosplenial area including the APO was slightly more dorsal compared to that of normal volunteers in our previous study (Ino et al., 2002), and this finding may reflect functional reorganization following the lesion. Unfortunately, the patient was not subjected to an fMRI examination at a time when he was unable to perform the mental navigation task. However, given the observation that normal volunteers who do not know the location of places in the task did not show significant activation of the retrosplenial area during the mental navigation task (unpublished data), it is reasonable to assume that

his retrosplenial area would not have been activated when he could not perform the task. Therefore, we suggest (a) that the functional disturbance of the bilateral retrosplenial area was related to the directional disorientation of our patient, and (b) that when the retrosplenial area on the right side as well as on the left side surrounding the lesion had recovered a significant degree of neural function, his directional orientation improved.

Although most cases of topographical disorientation have been reported following the occurrence of a retrosplenial lesion on the right rather than the left side, activation studies have not confirmed right-side dominance in the retrosplenial area during navigation (Maguire, 2001). This is in contrast with the finding that the hippocampus and parahippocampal gyrus are activated with right-side dominance during navigation tasks (Ino et al., 2002; see also for review, Burgess et al., 2002). We suspect that topographical disorientation may be masked by a more global amnesic syndrome caused by the left retrosplenial lesion (Valenstein et al., 1987) and that this is why cases of directional disorientation following left retrosplenial lesion are rarely reported. Although our patient could not properly be described as suffering from an amnesic syndrome, neuropsychological examinations did reveal a disturbance of anterograde verbal learning memory, which may have been related to the left retrosplenial lesion. Further studies are essential to disclose whether navigation is characterized by lateralized function in the retrosplenial area. If so, an investigation into the relationship between the dominant side for navigation and that for language would become important and interesting issue.

REFERENCES

- AGUIRRE GK, DETRE JA, ALSOP DC and D'ESPOSITO M. The parahippocampus subserves topographical learning in man. *Cerebral Cortex*, 6: 823-829, 1996.
- AGUIRRE GK, ZARAHN E and D'ESPOSITO M. Neural components of topographical representation. *Proceedings of the National Academy of Sciences*, 95: 839-846, 1998.
- AGUIRRE GK and D'ESPOSITO M. Topographical disorientation: A synthesis and taxonomy. *Brain*, 122: 1613-1628, 1999.
- ALSAADI T, BINDER JR, LASAR RM, DOORANI T and MOHR JP. Pure topographical disorientation: A distinctive syndrome with varied lesion location. *Neurology*, 54: 1864-1866, 2000.
- BURGESS N, BECKER S, KING JA and O'KEEFE J. Memory for events and their spatial context: models and experiments. *Philosophical Transactions of the Royal Society of London B*, 356: 1493-1503, 2001a.
- BURGESS N, MAGUIRE EA and O'KEEFE J. The human hippocampus and spatial and episodic memory. *Neuron*, 35: 625-641, 2002.
- BURGESS N, MAGUIRE EA, SPIERS HJ and O'KEEFE J. A temporoparietal and prefrontal network for retrieving the spatial context of lifelike events. *NeuroImage*, 14: 439-453, 2001b.
- COLBY, CL, GATTASS R, OLSON CR and GROSS CG. Topographical organization of cortical afferents to extrastriate visual area PO in the macaque: a dual tracer study. *Journal of Comparative Neurology*, 269: 392-413, 1988.
- COVEY E, GATTASS R and GROSS CG. A new visual area in the parieto-occipital sulcus of the macaque. *Society of Neuroscience Abstract*, 8: 681, 1982.
- FARRELL JM. Topographical disorientation. *Neurocase*, 2: 509-520, 1996.
- GALLETTI C, BATTAGLINI PP and FATTORI P. Functional properties of neurons in the anterior bank of the parieto-occipital sulcus of the macaque monkey. *European Journal of Neuroscience*, 3: 452-461, 1991.
- GALLETTI C, BATTAGLINI PP and FATTORI P. Parietal neurons encoding spatial locations in craniotopic coordinates. *Experimental Brain Research* 96: 221-229, 1993.
- GALLETTI C, FATTORI P, KUTZ DF and GAMBERINI M. Brain location and visual topography of cortical area V6A in the macaque monkey. *European Journal of Neuroscience*, 11: 575-582, 1999.
- GHAEM O, MELLET E, CRIVELLO F, TZOURIO N, MAZOYER B, BERTHOZ A and DENIS M. Mental navigation along memorized routes activates the hippocampus, precuneus, and insula. *Neuroreport*, 8: 739-744, 1997.
- HOLDSTOCK JS, MAYES AR, CEZAYIRLI E, ISAAC CL, AGGLETON JP and ROBERTS N. A comparison of egocentric and allocentric spatial memory in a patient with selective hippocampal damage. *Neuropsychologia*, 38: 410-425, 2000.
- INO T, INOUE Y, KAGE M, HIROSE S, KIMURA T and FUKUYAMA H. Mental navigation in humans is processed in the anterior bank of the parieto-occipital sulcus. *Neuroscience Letters*, 322: 182-186, 2002.
- KATAYAMA K, TAKAHASHI N, OGAWARA K and HATTORI T. Pure topographical disorientation due to right posterior cingulate lesion. *Cortex*, 35: 279-282, 1999.
- MAGUIRE EA. The retrosplenial contribution to human navigation: A review of lesion and neuroimaging findings. *Scandinavian Journal of Psychology*. 42: 225-238, 2001.
- MAGUIRE EA, FRACKOWIAK RS and FRITH CD. Recalling routes around London: Activation of the right hippocampus in taxi drivers. *Journal of Neuroscience*, 17: 7103-7110, 1997.
- MAGUIRE EA, FRITH CD, BURGESS N, DONNET JG and O'KEEFE J. Knowing where things are: Parahippocampal involvement in encoding objects locations in virtual large-scale space. *Journal of Cognitive Neuroscience*, 10: 61-76, 1998.
- OBI T, BANDO M, TAKEDA K and SAKUTA M. A case of topographical disturbance following left medial parieto-occipital lobe infarction. *Clinical Neurology*, 32: 426-429, 1992 [in Japanese].
- O'KEEFE J and NADEL L. *The Hippocampus as a Cognitive Map*. Oxford: Clarendon Press, 1978.
- OLDFIELD RC. The assessment and analysis of handedness: The Edinburgh inventory. *Neuropsychology*, 9: 97-113, 1971.
- PEARCE JM, ROBERTS AD and GOOD M. Hippocampal lesions disrupt navigation based on cognitive maps but not heading vectors. *Nature*, 396: 75-77, 1998.
- SHELTON AL. Systems of spatial reference in human memory. *Cognitive Psychology*, 43: 274-310, 2001.
- TAKAHASHI N, KAWAMURA M, SHIOTA J, KASAHARA N and HIRAYAMA K. Pure topographical disorientation due to right retrosplenial lesion. *Neurology*, 49: 464-469, 1997.
- VALENSTEIN E, BOWERS D, VERFAELLIE M, HEILMAN KM, DAY A and WATSON RT. Retrosplenial amnesia. *Brain*, 110: 1631-1646, 1987.
- VOGT BA, VOGT JL, PERL DP and HOF PR. Cytology of human caudomedial cingulate, retrosplenial, and caudal parahippocampal cortices. *Journal of Comparative Neurology*, 438: 353-376, 2001.
- WANG RF and SPELKE ES. Updating egocentric representations in human navigation. *Cognition*, 77: 215-250, 2000.

Tadashi Ino, Department of Neurology, Rakuwakai-Otowa Hospital, Otowachinicho 2 Yamashina-Ku, Kyoto 607-8062, Japan. e-mail: rakuwad042@rakuwad.com

(Received 23 February 2004; reviewed 12 May 2004; revised 2 June 2004; accepted 21 December 2005; action editor: Edward de Haan)