

Cerebral Infarct Secondary to Traumatic Carotid Artery Dissection

Jainn-Jim Lin, MD,* Min-Liang Chou, MD,* Kuang-Lin Lin, MD,*
Mun-Ching Wong, MD,† and Huei-Shyong Wang, MD*

Abstract: Internal carotid artery dissection is an important cause of ischemic stroke in children and young patients. Children presenting with gross neurological abnormalities after blunt trauma to the head or neck should be considered to have sustained injury to the carotid arteries until proven otherwise. Treatment options include observation, anticoagulation and endovascular stenting, and aggressive surgical repair of the carotid artery injury. We present the case of a 7-year-old boy who had a dissection of his right internal carotid artery after a dangerous position of head upside down from a water slide.

Key Words: cerebral infarct, traumatic carotid artery dissection

Internal carotid artery dissection (ICAD) is an important cause of ischemic stroke in children and young patients. Trauma and/or an underlying structural defect of the arterial wall have been suggested to be predisposing factors.¹ The clinical presentation of ICAD patients has been described as a characteristic triad of symptoms including ipsilateral neck or head pain, ipsilateral Horner syndrome, and delayed focal hemispheric ischemic symptoms.² Brain magnetic resonance imaging (MRI) and magnetic resonance angiography (MRA) are the imaging modalities of choice for suspected ICAD. Arterial dissection is 1 form of traumatic vascular injury, and the vertebrobasilar arteries are the most frequently involved, followed by the carotid arteries and their branches. Here, we report a boy presenting with acute hemiplegia and central facial palsy after playing on water slides in a head upside-down position. His ICAD was caused by a violent water impact.

CASE

The previously healthy 7-year-old boy arrived at the emergency department because of limb weakness over the left side after playing on the water slides at a water park. Trauma and choking were uncertain. However, a head upside-down position from water slide was told. Headache, vomiting, neck pain, and

numbness over left limbs were complained. There were no loss of consciousness, seizure, stool incontinence, or urine retention noted. Beside, no fever, diarrhea, or symptoms of upper respiratory tract infection were noted in preceding days. At emergency department, physical examinations showed left central facial palsy and left hemiplegia with a positive Babinski sign on the left side. Brain computed tomography without contrast revealed no evidence of cerebral hemorrhage or ischemia. He was admitted to the ward for further evaluation and treatment on May 14, 2005.

Glasgow Coma Scale score was 15, and neurological examinations showed left central facial palsy, mild uvula deviation to the left side, slurred speech, left limbs weakness (muscle power, 2 over 5 of left upper and lower limbs) with numbness, and positive Babinski sign on the left side.

During hospitalization, a neurological deficit was still evident, and the Glasgow Coma Scale score progresses to 8. A brain MRI and MRA were performed at the second day of admission. The MRI of the brain without and with gadopentetic acid enhancement revealed acute infarction involving the right hippocampus, posterior caudate nucleus, posterior corona radiata, posterior putamen, and anterolateral thalamus (Fig. 1). Brain MRA showed decreased caliber of the right internal carotid artery (ICA) after the common carotid artery bifurcation, and abnormal high signal around the right carotid siphon at the right cavernous sinus region were found (Figs. 2, 3). Cerebral angiography showed right ICA dissections at petrosal and communicating segments with resultant hypoperfusion of right hemisphere. The patient was received conservative medical care with anticoagulant of warfarin sodium for 3 months. After rehabilitation, improvement of left-side weakness was found (muscle power, 3 over 5 of left arm and 4 over 5 of left leg). He could walk with a walking stick after 3-month follow-up.

DISCUSSION

Arterial dissection has been also associated with a variety of factors, including hypertension, fibromuscular dysplasia, Marfan syndrome, cystic medial necrosis, oral contraceptives, drug abuse (sympathomimetics), and infection.¹ In our patient, the history of playing water slides with a head upside-down position make it a possible cause for his ICAD. That dangerous position could produce a violent impact on the ICA.

Although increasing diagnosis through modern neuro-radiological techniques, its pathogenesis remains unclear. Internal carotid artery dissection occurs when an intimal tear permits blood to enter the potential space between the vessel intima and media. However, arterial dissection, cerebral

*Division of Pediatric Neurology, Department of Pediatrics and †Division of Neuroradiology, Chang Gung Children's Hospital and Chang Gung Memorial Hospital, Chang Gung University Medical College, Taoyuan, Taiwan.

Address correspondence and reprint requests to Kuang-Lin Lin, MD, Division of Pediatric Neurology, Chang Gung Children's Hospital, 5 Fu-Shin Street, Kwei-Shan, Taoyuan, 333 Taiwan. E-mail: lincgh@adm.cgmh.org.tw.

Copyright © 2007 by Lippincott Williams & Wilkins
ISSN: 0749-5161/07/2303-0166

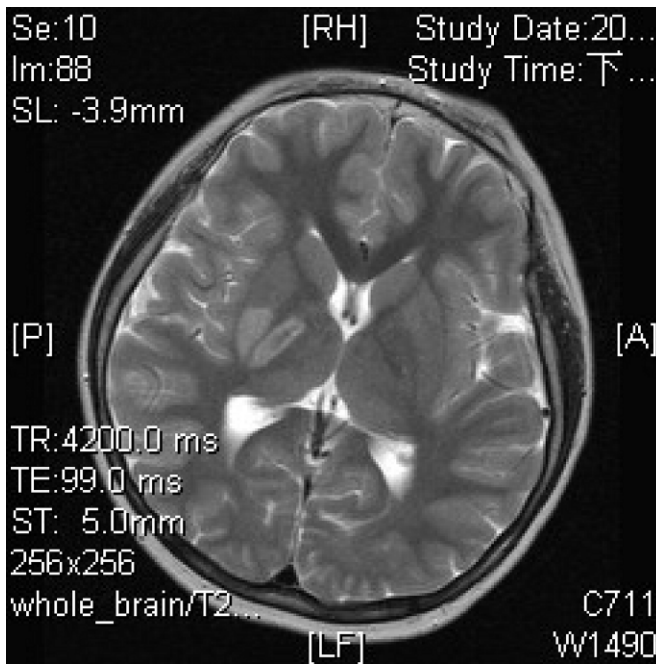


FIGURE 1. Hyperintensity on magnetic resonance T2-weighted imaging at the right hippocampus, posterior caudate nucleus, posterior corona radiata, posterior putamen, and anterolateral thalamus.

vasospasm, and thrombosis have been some of the theories discussed in the pathogenesis of cerebral infarct secondary to carotid artery dissection after trauma. The common carotid

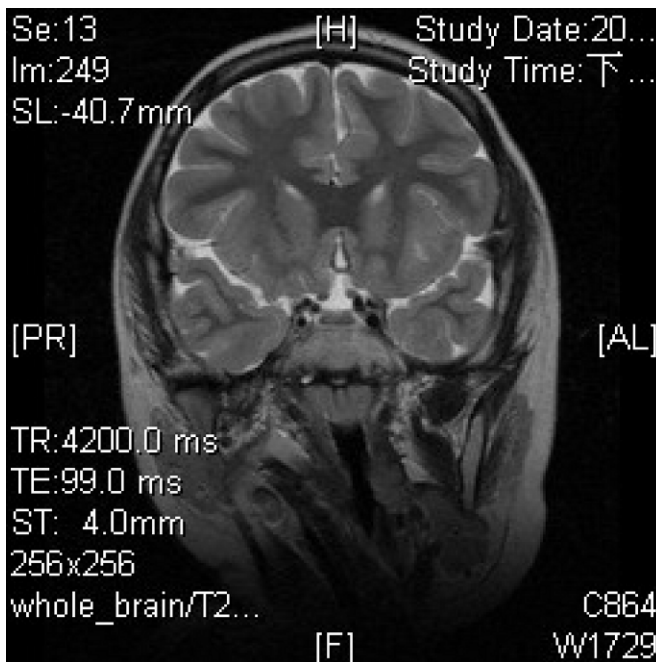


FIGURE 2. Coronal magnetic resonance T2-weighted imaging showed abnormal high signal around the right carotid siphon at the right cavernous sinus region, which support the diagnosis of intimal tear of the internal carotid artery.

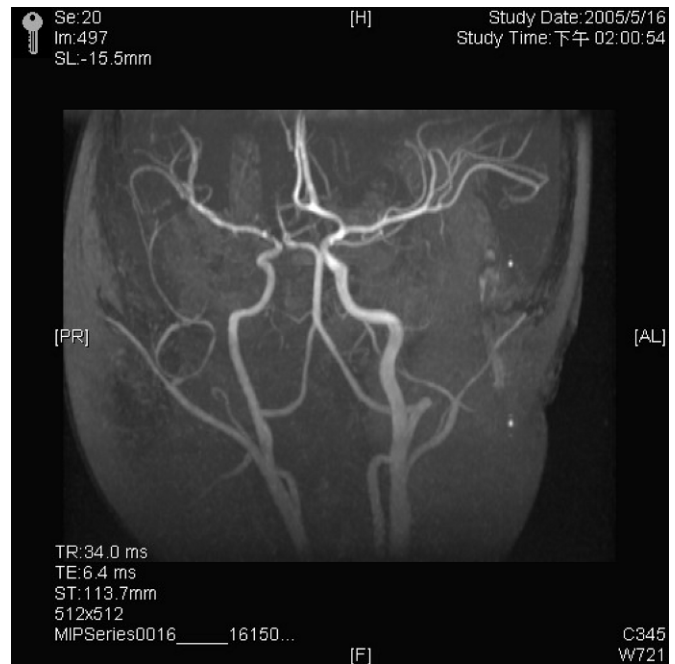

FIGURE 3. Magnetic resonance angiography showed relative small caliber of right ICA as compared with the left. Focal narrowing of right ICA at petrosal segment and communicating segments. Right A1 segment is patent, but blood flow arose from left ICA circulation via anterior communicating artery.

injuries after blunt cervical trauma, in descending order of incidence, are as follows: dissection, pseudoaneurysm, and thrombosis.^{3,4} The dissection of carotid artery usually begins just above the carotid bifurcation and extends toward the foramen lacerum.⁵ In our patient, MRA and cerebral angiography showed focal narrowing of right ICA at petrosal segment and communicating segments.

In general, clinical findings seem to be different when comparing traumatically induced ICAD with spontaneous ICAD. In the traumatic group, focal cerebral ischemic symptoms were the most common manifestations. In the spontaneous group, unilateral headaches were the most commonly experienced symptom, often in association with Horner syndrome.^{6,7} Like spontaneous ICAD, the onset of ischemic signs and symptoms may be delayed in traumatic cases.⁸ The longer this delay, the greater the confusion in assigning any causation to the ICAD. So in all, a case of the coincidence of any local pain in neck or face with an ipsilateral Horner syndrome preceding transient or persistent retinal or cerebral ischemic symptoms should alert physicians to rule out an underlying dissection of the ipsilateral carotid artery. In our patient, traumatic ICAD must be considered because of presentations of acute onset of neck pain, headache, left central facial palsy without Horner syndrome, and left hemiplegia after blunt cervical injury.

The imaging characteristics of the thrombus within the carotid sheath are the key to the radiological diagnosis of an

extracranial ICAD.⁹ The thrombus will appear as a bright crescent (isointense with fat) encircling the ICA lumen on both T1 and T2 fast spin-echo axial MRI. No appreciable enhancement will occur after the administration of intravenous gadolinium. Typically, the vessel lumen is narrowed when compared with the normal side secondary to compression from the extravasated blood products within the carotid sheath. In our patient, MRI and MRA showed decreased caliber of the right ICA after the common carotid artery bifurcation. Abnormal high signal around the right carotid siphon at the right cavernous sinus region support the diagnosis of intimal tear of the ICA.

The management goal in cases of extracranial ICAD is to prevent the development or worsening of neurological deficits by preventing thrombosis and embolization. Treatment options include observation, anticoagulation and endovascular stenting, and aggressive surgical repair of the carotid artery injury. And it is usually medical rather than surgical. Anticoagulation has become a mainstay of treatment. Anticoagulation is often initially achieved with heparin and then, after 1 to 3 weeks, maintained with warfarin, which is continued for up to 6 months.¹⁰ In our patient, we kept warfarin for anticoagulation therapy with a good result.

In summary, a dangerous position of head upside down from water slide could produce a violent impact on ICA

causing dissection. Delayed clinical symptoms may occur in such a condition of traumatic ICAD.

REFERENCES

1. Klufas RA, Hsu L, Barnes PD, et al. Dissection of the carotid and vertebral arteries: imaging with MR angiography. *AJR Am J Roentgenol*. 1995;164:673–677.
2. Steinke W, Rautenberg W, Schwartz A, et al. Noninvasive monitoring of internal carotid artery dissection. *Stroke*. 1994;25:998–1005.
3. Fabian TC, Patton JH, Croce MA, et al. Blunt carotid injury: importance of early diagnosis and anticoagulant therapy. *Ann Surg*. 1996;223:513–525.
4. Cogbill TH, Moore EE, Meissner M, et al. The spectrum of blunt injury to the carotid artery: a multicenter perspective. *J Trauma*. 1994;37:473–479.
5. John M, Lasak, Thomas C, et al. Extracranial internal carotid artery dissection. *Otol Neurotol*. 2005;26:131–132.
6. Mokri B. Traumatic and spontaneous extracranial internal carotid artery dissections. *J Neurol*. 1990;237:356–361.
7. Mokri B, Piepgras DG, Houser OW. Traumatic dissections of the extracranial internal carotid artery. *J Neurosurg*. 1988;68:189–197.
8. Hughes KM, Collier B, Greene KA, et al. Traumatic carotid artery dissection: a significant incidental finding. *Am Surg*. 2000;66:1023–1027.
9. Klufas RA, Hsu L, Barnes PD, et al. Dissection of the carotid and vertebral arteries: imaging with MR angiography. *AJR Am J Roentgenol*. 1995;164:673–677.
10. Lee DH, Hur SH, Kim HG, et al. Treatment of internal carotid artery dissections with endovascular stent placement: report of two cases. *Korean J Radiol*. 2001;2:52–56.