

Cavernous Sinus Thrombosis

Successful Treatment Using Functional Endonasal Sinus Surgery

Ramzi T. Younis, MD, Rande H. Lazar, MD

Objective: Infections of the paranasal sinuses can be complicated by septic thrombosis of the cavernous venous sinuses. After standard antibiotic treatment, fewer than 50% of the patients recover completely, and the mortality rate is approximately 30%. We chose to treat this potentially catastrophic complication with functional endonasal sinus surgery in addition to standard antibiotic therapy.

Design: Case study.

Patient: A 15-year-old boy presented to the emergency room of LeBonheur Children's Medical Center, Memphis, Tenn, with right proptosis, chemosis, ptosis, ophthalmoplegia, cranial nerve palsies, and paresthesia. The physical examination and computed tomographic scans of the sinuses and orbits revealed edema of the right orbit and pansinusitis, with secondary right cavernous sinus thrombosis and right superior ophthalmic vein thrombosis.

Intervention: The patient was started on a regimen of cefuroxime and nafcillin sodium and was scheduled for emergency functional endonasal sinus surgery to drain the primary sites of infection. After surgery, the patient was placed on a 3-week regimen of cefotaxime sodium, metronidazole hydrochloride, vancomycin hydrochloride, and heparin sodium.

Results: During surgery, the frontal recess and ethmoid, sphenoid, and maxillary sinuses were found to be filled with polypoid tissue and purulent material. Functional endonasal sinus surgery restored the sinuses to their normal physiologic state. The sinuses demonstrated the progress observed clinically.

Conclusions: The improvement in outcome effected by standard antibiotic therapy can be significantly augmented by using functional endonasal sinus surgery in the treatment of cavernous sinus thrombosis.

(*Arch Otolaryngol Head Neck Surg.* 1993;119:1368-1372)

THE POSTMORTEM changes of septic cavernous sinus thrombosis were first described by Duncan¹ in 1821. All of the initial attempts to treat the condition with surgery failed.^{2,3} In 1936, Grove⁴ reviewed 400 cases and reported a mortality rate of 100%. One year later, MacNeal and Cavallo⁵ described the first survivor after using sulfonamides and antistreptococcus serum.

Since the advent of antibiotics, the incidence and mortality rate for cavernous sinus thrombosis have decreased. New diagnostic and therapeutic modalities have markedly improved outcome, but this infectious complication still carries a significant risk of morbidity and mortality. The customary treatment in-

cludes drainage of the primary focus of infection, high doses of intravenous antibiotics, and subclinical doses of heparin sodium. With standard treatment, fewer than 50% of the patients recover completely, and approximately 30% of them die, emphasizing the need for improved treatment.

We report the case of a child with pansinusitis in whom right cavernous sinus thrombosis developed. He was successfully treated with intravenous antibiotics, a subclinical dose of heparin, and functional endonasal sinus surgery (FESS). The pathogenesis, diagnosis, roentgenographic findings, and treatment of this potentially lethal complication are discussed, highlighting the role of FESS as a new therapeutic modality.

From the Otolaryngology
Consultants of Memphis (Tenn),
LeBonheur Children's Medical
Center.

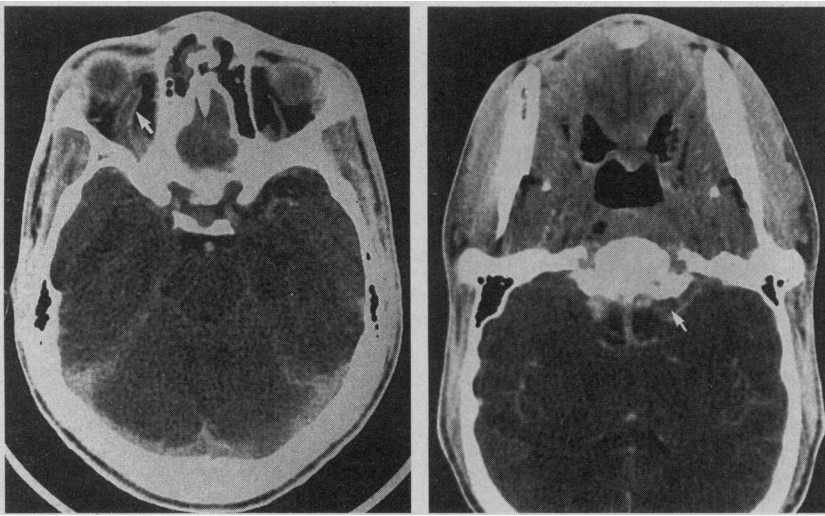


Figure 1. Left, Axial computed tomographic scan of the brain (April 3, 1989) shows right-sided facial and orbital swelling and proptosis and thrombosed right superior ophthalmic vein (arrow). Right, Computed tomographic scan shows enhancement of the right internal carotid artery (arrow) within a thrombosed cavernous sinus (no uptake of contrast) and the left cavernous sinus (enhanced with contrast).

REPORT OF A CASE

A 15-year-old boy presented to our emergency room at LeBonheur Children's Medical Center, Memphis, Tenn, on April 3, 1989. One day before hospital admission, the patient had swelling of the right eye with pain and diplopia. For 3 weeks, he had had an upper respiratory tract infection and right-sided headache, but his medical history was essentially unrevealing. Physical examination disclosed that he had a temperature of 39.5°C, heart rate of 102 beats per minute, respirations of 24/min, and blood pressure of 120/64 mm Hg. He had right proptosis, chemosis, ptosis, and ophthalmoplegia. The boy had third, fourth, and sixth cranial nerve palsies and paresthesia over the maxillary branches of the trigeminal nerve, but he was otherwise neurologically intact with no meningeal signs.

The physical examination also revealed congested erythematous nasal mucosa with bilateral purulent nasal discharge. The right side of his face was swollen and tender. Computed tomographic (CT) scans of the sinuses and orbits revealed pansinusitis, with secondary right cavernous sinus thrombosis and right superior ophthalmic vein thrombosis (**Figure 1**). The right orbit had mod-

erate edema. After the diagnosis of acute sinusitis with right cavernous sinus thrombosis, neurosurgical, neurologic, and ophthalmologic consultations were requested. Informed consent for treatment was obtained after the procedures were explained.

The patient was started on a regimen of 1.5 mg of cefuroxime given intravenously every 8 hours and 2 g of nafcillin sodium given intravenously every 4 hours. He was also scheduled for emergency FESS. During surgery, the ethmoid and sphenoid sinuses were found to be filled with polypoid tissue and purulent material. The frontal recess and maxillary sinuses were also filled with polypoid disease. Results of the pathologic examination of these specimens were compatible with chronic sinusitis.

After surgery, the patient was transferred to the intensive care unit, where he was started on a regimen of 3 g of cefotaxime sodium, 500 mg of metronidazole hydrochloride, given intravenously. The heparin dose was altered according to the results of the daily partial thromboplastin time.

The patient's laboratory profile was carefully monitored during hospitalization. At the time of hospital admission, he had a hemoglobin value of 122 g/L, hematocrit of 0.36, and leukocyte count of $24.7 \times 10^9/L$, with

0.92 neutrophils. The leukocyte count dropped progressively during treatment and was normal at the time of hospital discharge. From the time of hospital admission to hospital discharge, results of all serum chemistry studies were normal. His partial thromboplastin time was maintained between 25.0 and 35.0 seconds. Group C *Streptococcus* grew from one of three blood cultures. Group C *Streptococcus* and coagulase-negative *Staphylococcus* grew from intraoperative cultures of his sinuses. Analysis also revealed anaerobic organisms, including *Streptococcus viridans* and *Bacteroides melaninogenicus*.

The patient was extubated on the second postoperative day and closely observed. A repeated CT scan of the sinuses and orbits on April 6 showed further progression of the thrombosis of the facial veins and increased soft-tissue swelling (**Figure 2**). However, because the patient's clinical condition was improving, the same therapeutic regimen was maintained. On April 10, the facial edema and right eye proptosis were regressing. Another CT scan of the sinuses and orbits (**Figure 3**) on the same day demonstrated clinical improvement.

The patient was transferred to a regular nursing floor, where he was treated with 7500 IU of heparin sodium administered subcutaneously every 6 hours. Treatment with beclomethasone dipropionate spray and sa-

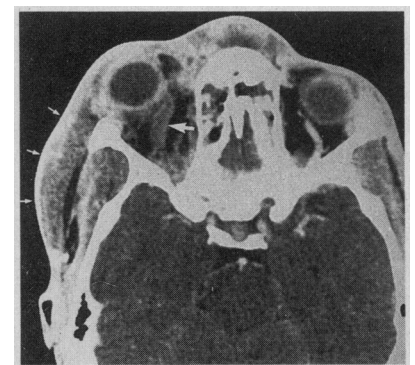


Figure 2. Axial computed tomographic scan of the brain (April 5, 1989) shows increased right-sided facial and orbital swelling and proptosis (small arrows) and thrombosed right superior ophthalmic vein (solid white arrow).

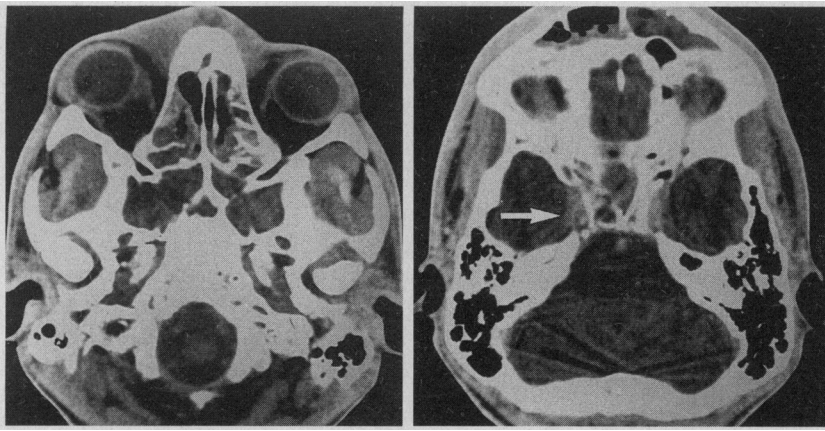


Figure 3. Left, Axial computed tomographic scan of the brain (April 10, 1989) shows regression of the right-sided facial and orbital swelling. Right, Axial computed tomographic scan of the brain (April 10, 1989) shows recanalization (enhancement) of the cavernous sinus (arrow).

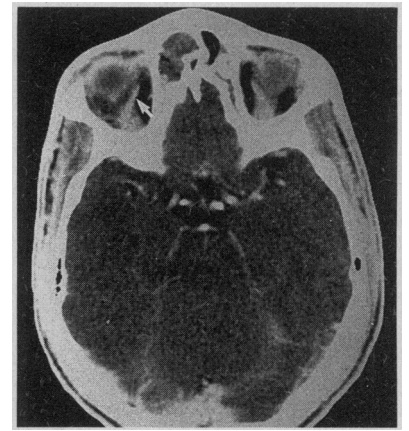


Figure 4. Axial computed tomographic scan of the brain (April 20, 1989) shows recanalization of the right superior ophthalmic vein (arrow).

line nasal washes was also started. The antibiotic and heparin therapy was continued for a total of 21 days. Another CT scan of the sinuses (**Figure 4**) performed on April 20 demonstrated the progress observed clinically. On April 24, the patient was in good condition and was discharged from the hospital to his home.

COMMENT

The cavernous sinuses, located at the base of the skull superolateral to the sphenoid sinus (**Figure 5**), are valve-

less venous channels within the leaves of the dura. The right and left cavernous sinuses communicate through the intercavernous sinuses, which pass anteriorly and posteriorly to the sella turcica and pituitary gland. The oculomotor nerve (III), trochlear nerve (IV), and the ophthalmic and maxillary branches of the trigeminal nerve (V) course along the lateral wall of the cavernous sinus. The internal carotid artery, sympathetic plexus, and the abducens nerve (VI) traverse the center of the cavernous sinus near its medial wall. Thrombophlebitis of

this sinus may affect all of these anatomic structures.

The cavernous sinuses drain the anterior portion of the face, oral cavity, tonsils, pharynx, nasal cavity, orbit, eye, paranasal sinuses, middle ear, mastoid region, cerebral cortex, and the pituitary. The cavernous sinuses empty into the superior and inferior petrosal sinuses and ultimately drain into the internal jugular vein. Because of these associations, focal infection of the head or neck region may produce septic thrombosis of the cavernous sinuses.

Infections of the medial third of the face, including the nose, orbit, tonsils, and soft palate, were the most common causes of cavernous sinus thrombosis in the past.⁶⁻⁸ Bacteria can enter the facial or pterygoid plexus and reach the cavernous sinus by the superior or inferior ophthalmic veins. After antibiotics were introduced, sinusitis involving the sphenoid and ethmoid air sinuses became a more frequent antecedent condition. Of the eight patients reviewed by Southwick and colleagues,⁸ all had sphenoid or ethmoid sinusitis before cavernous sinus thrombophlebitis developed. The predisposing infection may spread from the air sinuses by small emissary veins, the sphenoid vein, or directly from the sphenoid sinus. Infrequently, infections of the ear spread by way of emissary veins to the sigmoid sinuses and reach

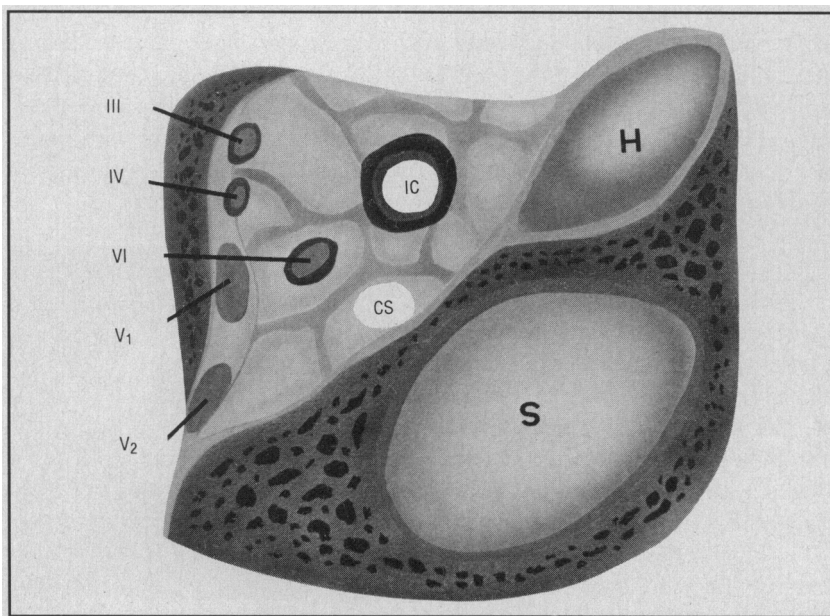


Figure 5. Anteroposterior vertical cross-section of the cavernous sinus anatomy. CS indicates cavernous sinus; IC, internal carotid artery; III, oculomotor nerve; IV, trochlear nerve; V₁ and V₂, ophthalmic and maxillary branches of the trigeminal nerve; VI, abducens nerve; H, hypophysis; and S, sphenoid sinus.

Table 1. Clinical Manifestations of Cavernous Sinus Thrombosis

Manifestations

Headache
Retro-orbital pain
Fever
Periorbital edema
Ptosis
Proptosis
Chemosis
Ocular muscle palsies (III-VI)
Reduced visual acuity
Papilledema
Nuchal rigidity
Lethargy
Coma

the cavernous sinus through the inferior petrosal sinuses.⁸

The many clinical manifestations of cavernous sinus thrombosis are given in **Table 1**. Most patients have spiking fever and chills. Other signs of toxemia include profuse perspiration, rapid thready pulse, nausea, vomiting, confusion, delirium, and coma. Headache may occur in as many as 50% of the patients who eventually have development of cavernous sinus thrombosis.⁹

The first signs of venous obstruction are eyelid edema and chemosis, followed by proptosis, ptosis, and edema of the bridge of the nose. Periorbital edema occurs in approximately 75% of these patients.⁹ It is initially confined to one side, but it often progresses to involve the contralateral eye within 2 days.^{8,10}

Diplopia and photophobia are uncommon early complaints. Ophthalmoplegia secondary to orbital congestion, dilatation, and possibly thrombosis of the facial vein may develop.⁹

Limitation of the extraocular muscles can be demonstrated at some point in most patients.⁸⁻¹⁰ Lateral gaze palsy may be an isolated early neurologic finding because the abducens nerve is the only cranial nerve that traverses the cavernous sinus.⁹ Involvement of the ophthalmic and maxillary branches of the trigeminal

nerve can lead to paresthesia of the upper two thirds of the face, which can exacerbate headache and obliterate the corneal reflex. The pupils in patients with cavernous sinus thrombosis become fixed and dilated after the loss of parasympathetic control. However, if the internal carotid artery sympathetic plexus is affected, the pupil may be small and fixed.^{10,11} More than half of the patients exhibit changes in neural status.⁹ Meningismus occurs in a few patients. As the thrombophlebitis extends through the intercavernous sinuses, the signs and symptoms become bilateral, and the toxic manifestations increase.¹⁰

The diagnosis of cavernous sinus thrombosis is usually based on clinical findings. According to Price et al,¹² five criteria are required to make the diagnosis of cavernous sinus thrombosis (**Table 2**). The diagnosis is further confirmed by roentgenographic and laboratory studies.¹³ Computed tomography with enhancement is the best available radiologic tool. Coronal CT scans of the sinuses can demonstrate any sinus disease, and a contrast-enhanced CT scan of the brain may help in diagnosing cavernous sinus thrombosis.^{14,15} Although a CT scan may fail to demonstrate occlusion of the cavernous sinus, it may reveal provocative findings, such as thrombosed superior ophthalmic vein, cortical venous infarcts, or an orbital abscess.⁹ The diagnostic yield can be improved by infusion of higher doses of contrast material followed by rapid sequential views of the cavernous sinus and by employing thin sections with multiple relationships and direct coronal scanning.⁹

Radionuclide brain scans usually impart nonspecific findings, but magnetic resonance imaging can aid the diagnosis.⁹ Carotid audiography or orbital venography can be used, but these are highly invasive and do not provide more information than enhanced CT.

Leukocytosis, elevated protein level in cerebrospinal fluid, pleocy-

tosis, and normal glucose level are usually detected among the laboratory findings. Blood cultures are usually positive.

The mainstay of therapy in cavernous sinus thrombosis is high doses of intravenous antibiotics. A combination of antibiotics effective against gram-positive, gram-negative, and anaerobic organisms should be instituted before the results of cultures and sensitivity studies are available. *Staphylococcus aureus* is documented in more than 67% of these patients.⁹ Pneumococci and other streptococcal species account for most of the remaining cases.⁸⁻¹⁰ Gram-negative bacilli and anaerobes are occasionally isolated.

A penicillinase-resistant penicillin, such as nafcillin, and a third-generation cephalosporin, such as ceftazidime or cefotaxime sodium, provide good initial combination therapy. Chloramphenicol can also be used with nafcillin to combat anaerobes.^{8-10,16} Medical treatment should be continued for 2 to 4 weeks after local and general signs of infection have subsided.¹⁰ Our patient was treated with cefotaxime, a wide-spectrum antibiotic that covers gram-negative bacilli. Metronidazole was given to cover anaerobes and vancomycin was administered to optimize coverage for *S aureus*.

The use of heparin is controversial, but it can benefit patients with early unilateral manifestations of cav-

Table 2. Diagnostic Criteria for Cavernous Sinus Thrombosis*

Criteria

Bilateral involvement or sequential progression to the contralateral eye
Proptosis, chemosis of conjunctiva, eyelid edema
Limitation of extraocular motion
Meningismus, may include cerebrospinal fluid pleocytosis
Residual cranial nerve palsy of cranial nerves III, IV, or V after arrest of process

*From Price et al.¹²

ernous sinus thrombosis. Southwick and associates⁸ showed that mortality was decreased with heparin use. Anticoagulation may prevent further spread of thrombosis and may prevent septic emboli to the other venous sinus. It may also contribute to recanalization and dissolution of the clot, allowing the antibiotic to reach the infected thrombosis more readily.^{10,17} Alternatives to heparin include warfarin sodium (Coumadin), dextran, streptokinase, or streptodornase.¹⁰ Anticoagulation should be considered only if there is no clinical or CT evidence of cortical venous infarction.^{9,10}

INTRAVENOUS corticosteroids may sometimes serve as adjunctive therapy, especially if there is a lack of response to high-dose antibiotics.^{10,11} Corticosteroids are occasionally used to decrease orbital congestion, and they may prevent Addisonian crisis if the septic thrombosis has spread to the pituitary.^{8,18} Therapeutic hypothermia is sometimes employed to control fever and decrease cerebral edema.¹⁹

In cases of cavernous sinus thrombosis, surgery is indicated to drain the primary site of infection. Surgical intrusion into the cavernous sinus is difficult and not recommended. If sphenoid or ethmoid sinusitis is documented by CT scans, surgical drainage of these infected pockets should be performed promptly. Functional endonasal sinus surgery is a quick and effective procedure for these patients.²⁰ The procedure restores the sinuses to their normal physiologic state by providing adequate aeration and restoring normal mucociliary flow through patent sinus ostia.²¹ Functional endonasal sinus surgery adequately drains the infected sinuses with little morbidity. If the patient cannot withstand general anesthesia, FESS can be performed under local anesthesia.

With the increasing incidence

of sinusitis as the principal source of infection in cavernous sinus thrombosis, FESS may eventually prove to be an essential step in the treatment of these patients. Rapid improvement occurred in all three patients who underwent débridement of the sphenoid sinuses in the series of Southwick et al.⁸ We believe that our strategy of employing antibiotics, heparin and, FESS provided optimal treatment because our patient's condition began to improve within 2 days and he recovered without adverse sequelae.

CONCLUSION

Antibiotics revolutionized the outcome of treatment for cavernous sinus thrombosis. In 1961, Yarrington²² reported a mortality rate of 80%, with a morbidity rate of 75% among the survivors. With standard treatment, the mortality rate dropped to approximately 30%, and full recovery was observed for fewer than half of the patients. We believe the dramatic improvement in outcome effected by antibiotics can be significantly augmented by employing FESS in the treatment of cavernous sinus thrombosis. Sinusitis has increasingly become the primary source of infection leading to cavernous sinus thrombosis, and skillfully executed FESS provides drainage of the infected sinuses.

The introduction of potent antibiotics, adjunctive therapies, and advanced surgical techniques has markedly improved the outcome of septic thrombosis of the cavernous sinus, but it remains a potentially catastrophic disorder. Prevention, prompt diagnosis, and optimal treatment exploiting all existent therapeutic modalities offer the best hope for recovery.

Accepted for publication December 11, 1992.

Reprint requests to Otolaryngology Consultants of Memphis, LeBonheur Children's Medical Center, 777 Washington Ave, P240, Memphis, TN 39105 (Dr Younis).

- Duncan A. Contributions to morbid anatomy. *Edinburgh Med Surg J.* 1821;17:321-336.
- Chilsolm J, Watkins SS. Twelve cases of thrombosis of the cavernous sinus. *Arch Surg.* 1920; 1:483-512.
- Smith D. Cavernous sinus thrombosis with notes of five cases. *Arch Ophthalmol.* 1981;47:482-496.
- Grove WE. Septic and aseptic types of thrombosis of the cavernous sinus. *Arch Otolaryngol.* 1936;24:29-50.
- MacNeal WJ, Cavallo ME. Streptococcal bacteremia and apparent thrombosis of cavernous sinus and recovery. *JAMA.* 1937;109: 2139-2141.
- Eagleon WP. *Cavernous Sinus Thrombophlebitis.* New York, NY: Macmillan Publishing Co Inc; 1926.
- Thomson SC. The causes and symptoms of cavernous sinus thrombosis. *Ophthalmol Rev.* 1908; 27:293-302.
- Southwick FS, Richardson EP, Swartz MN. Septic thrombosis of the dural venous sinuses. *Medicine (Baltimore).* 1986;65:82-106.
- DiNubile MJ. Septic thrombosis of the cavernous sinus. *Arch Neurol.* 1988;45:567-572.
- Karlin RJ, Robinson WA. Septic cavernous sinus thrombosis. *Ann Emerg Med.* 1984;13:449-455.
- Zahler M, Spector RH, Skoglund RR, et al. Cavernous sinus thrombosis. *West J Med.* 1980; 133:44-48.
- Price D, Hameroff SB, Richard D. Cavernous sinus thrombosis and orbital cellulitis. *South Med J.* 1971;64:1243-1247.
- Sofferan RA. Cavernous sinus thrombophlebitis secondary to sphenoid sinusitis. *Laryngoscope.* 1983;93:797-800.
- Ahmadi J, Kalue JR, Segall HD, Zee CS. CT observations pertinent to septic cavernous sinus thrombosis. *AJNR Am J Neuroradiol.* 1985;6: 755-758.
- Segall HD, Ahmadi J, McComb JG, et al. Computed tomographic observations pertinent to intracranial thrombotic and occlusive disease in childhood. *Neuroradiology.* 1982;143: 441-449.
- Yarrington CT Jr. Cavernous sinus thrombosis revisited. *Proc R Soc Med.* 1977;70:456-459.
- Levine SR, Twyman RE, Gilman S. The role of anticoagulation in cavernous sinus thrombosis. *Neurology.* 1985;38:517-522.
- Friberg TR, Sogg RL. Ischemic optic neuropathy in cavernous sinus thrombosis. *Arch Ophthalmol.* 1978;96:543-556.
- Brown P. Septic cavernous sinus thrombosis. *Bull Johns Hopkins.* 1961;109:68-75.
- Lazar RH, Younis RT. Pediatric functional endonasal sinus surgery: preoperative evaluation, surgical technique and postoperative care. Presented at the First International Symposium on Contemporary Sinus Surgery; November 5, 1990; Pittsburgh, Pa.
- Lazar RH, Younis RT, Gross CW. Pediatric functional endonasal sinus surgery: review of 210 cases. *Head Neck.* 1992;14:92-98.
- Yarrington CT Jr. The prognosis and treatment of cavernous sinus thrombosis: review of 878 cases in the literature. *Ann Otol Rhinol Laryngol.* 1961;70:263-267.