

Vascular

Intra-arterial verapamil-induced seizures: case report and review of the literature

Franklin D. Westhout, MD*, Chiedozie I. Nwagwu, MD

Department of Neurological Surgery, University of California Irvine School of Medicine, Orange, CA 92868, USA

Received 29 June 2006; accepted 2 August 2006

Abstract

Background: Intra-arterial verapamil infusion with or without balloon angioplasty is a common therapy for patients with hypertensive, hypervolemic, and nimodipine-refractory vasospasm following aSAH. Seizures occurring from IA infusion of verapamil are rare.

Case Description: A 24-year-old Korean-American woman presented with aSAH from the rupture of a 5-mm ICA bifurcation aneurysm. The aneurysm was secured with clip ligation through a craniotomy, and the patient was treated with HHH therapy in the neurosurgical ICU. Routine postoperative cerebral angiography was performed to confirm occlusion of the treated aneurysm and assess for vasospasm. In the first angiogram, vasospasm was detected in the supraclinoid portion of the ICA. Intra-arterial verapamil was started; during this treatment, the patient developed right-sided focal motor seizures. The infusion was terminated and the seizures were halted with midazolam. The patient's course was unremarkable until postoperative day 7, when she developed expressive aphasia, for which she was taken for emergent cerebral angiography under anesthesia. Marked focal spasm was identified in the distal supraclinoid ICA and the left A1. The patient was treated with 25 mg of superselective verapamil infusion. Upon emerging from anesthesia, her aphasia had resolved; however, 90 minutes after angiography, she experienced generalized seizures while she was in the ICU.

Conclusions: Seizures are a rare complication during cerebral angiographic procedures. Intra-arterial verapamil-induced seizures are infrequently reported. Cognizance for the potential of seizures to occur is advised during verapamil infusion for the treatment of refractory vasospasm in certain individuals.

© 2007 Elsevier Inc. All rights reserved.

Keywords:

Cerebral angiogram; Aneurysm; Vasospasm; Seizures; Tonic-clonic seizures

1. Introduction

Vasospasm is a common occurrence following SAH from ruptured aneurysms; it reportedly occurs in up to 70%

Abbreviations: A1, anterior cerebral artery A1 segment; aSAH, aneurysmal subarachnoid hemorrhage; AV, atrioventricular; Ca²⁺, Calcium ion; HHH, hypervolemic-hemodilution-hypertensive; IA, intra-arterial; ICA, internal carotid artery; ICU, intensive care unit; K⁺, Potassium ion; M1, middle cerebral artery M1 segment; MCA, middle cerebral artery; MeSH, medical subject heading; Na⁺, sodium ion; SAH, subarachnoid hemorrhage.

* Corresponding author. Tel.: +1 202 487 3548; fax: +1 714 456 8212.

E-mail address: westhout@yahoo.com (F.D. Westhout).

of patients [8]. Seizures occurring during the infusion of vasodilating agents are rare [5]. Usually given intravenously, verapamil is an antiarrhythmic agent and is usually given intravenously. This class of drugs has been implicated in drug-induced seizures [16]. However, most adverse effects of verapamil reported are QT prolongation, AV block, dyspnea, rash, and flushing in approximately 1% to 2% of verapamil administrations [10].

Occasional seizures with intravenous verapamil have been reported according to the manufacturer's package insert (American Regent, Inc [a Luitpold Pharmaceuticals, Inc, company]). Generalized convulsions have been reported to occur after a 300-mg IA infusion of papaverine

for vasospasm [6]. Feng et al [7] studied 29 patients over a 2-year period who received IA verapamil in 34 procedures for the treatment of vasospasm following aSAH and concluded that the IA infusion of low-dose verapamil is safe in patients with cerebral vasospasm. We describe the case of a patient who developed recurrent seizures on 2 occasions after being treated with IA verapamil infusion for angiographic and clinical vasospasm following aSAH. We also present a brief review of the literature.

2. Case report

A 24-year-old right-handed Korean-American woman presented with SAH from an aneurysm rupture. Her symptoms included sudden onset of severe headache, along with nausea and emesis. There was no report of recent trauma, loss of consciousness, and any history of seizure activity. The patient had no significant past medical history. Her father had died of aSAH complications. Her social history was unremarkable. She was not taking any medication, nutritional supplements, or contraceptives. On physical examination, she appeared to be in no apparent distress and had no focal neurologic deficit.

Computed tomography scan without contrast revealed diffuse SAH with mild ventriculomegaly consistent with Hunt-Hess grade 1 and Fisher grade 2 SAH. Computed tomography angiography with 3-dimensional reconstruction demonstrated a left ICA aneurysm measuring $5 \times 5 \times 5$ mm. A small bleb at the inferior aspect of the lesion was visible as well.

The lesion was surgically treated based on its location, anterior projection, and broad-based nature on radiographic imaging as well as on the patient's clinical presentation. Phenytoin therapy was started for seizure prophylaxis, with daily morning-level assessment for proper titration. A left pterional craniotomy was carried out for clip ligation with lumbar drain placement and third ventriculocisternostomy. The patient tolerated the procedure without any neurologic or postanesthesia complication. She was managed with HHH therapy and nimodipine (60 mg, 3 times a day) for vasospasm prevention.

During postoperative diagnostic angiography on day 7, there was significant vasospasm identified in the supraclinoid portion of the left ICA, with less severe vasospasm in the M1 (Fig. 1A). An infusion of verapamil was started; however, after slow infusion of 15 mg of verapamil, the patient developed right-sided focal motor seizures, with deviation of the eyes to the left, for 25 seconds. (We used concentrations of 5 mg/10 mL: 25 mg of verapamil diluted with 10 mL of normal saline.) Prompt cessation of verapamil infusion and administration of 1 mg of midazolam abated the seizure. Despite the early withdrawal of verapamil infusion, the patient experienced almost 50% reversal of vasospasm in the supraclinoid ICA (Fig. 1B). A review of records revealed that her phenytoin levels had been subtherapeutic at 9.1 on the

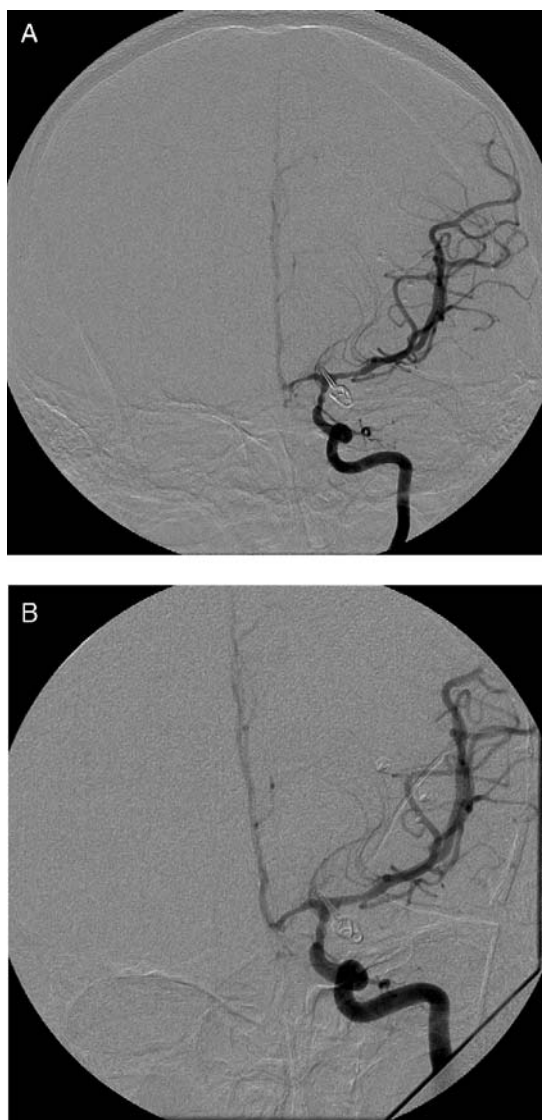


Fig. 1. A: Left ICA injection angiogram (anteroposterior projection) demonstrating severe vasospasm in the supraclinoid portion of the left ICA, with less severe vasospasm visible in the M1. B: Left ICA angiogram (anteroposterior projection) after infusion of 15 mg of IA verapamil induced right-sided focal motor seizures. Variable reversal of vasospasm is visible in the supraclinoid ICA, M1, and A1.

morning of the cerebral angiography. Increased boluses of phenytoin had been administered starting 2 days before the event, and her daily dose was increased from 200 to 400 mg.

No seizure was noted in the days after this procedure; however, the patient developed expressive aphasia with mild right-sided hemiparesis 7 days later. Emergent cerebral angiography was performed with the patient under anesthesia, and marked focal spasm was demonstrated of the distal supraclinoid ICA as well as the left A1 and mild vasospasm of the left M1 (Fig. 2A). Twenty-five milligrams of verapamil was slowly infused; improvement was noted in the left A1, left M1, and supraclinoid ICA, with

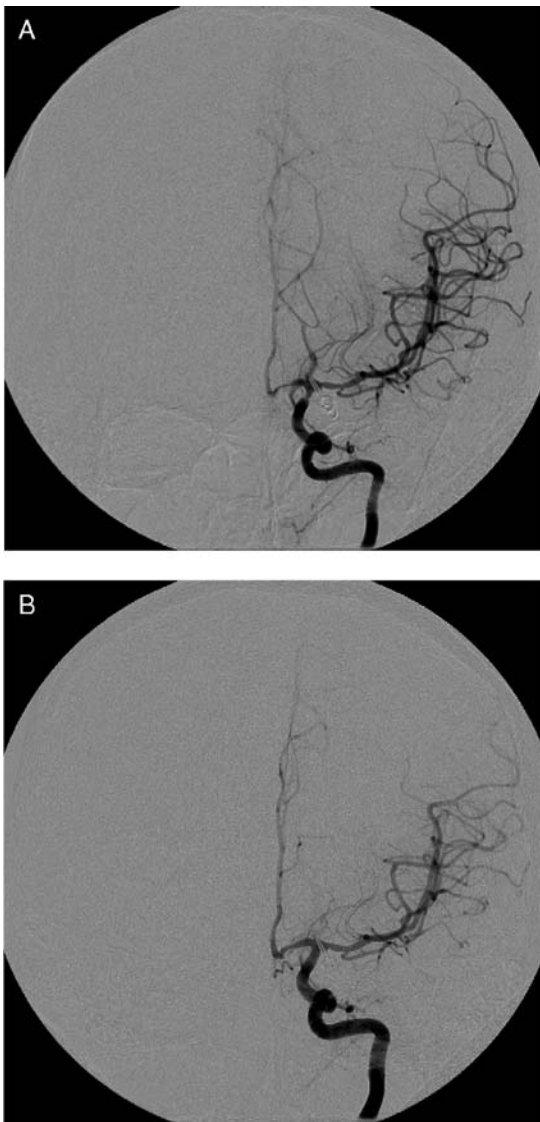


Fig. 2. A: Left ICA injection angiogram (anteroposterior projection) revealing marked focal spasm of the distal supraclinoid ICA as well as the left A1 and mild vasospasm of the left M1. B: Left ICA angiogram (anteroposterior projection) after slow infusion of 25 mg of IA verapamil. Considerable improvement was noted in the left A1, left M1, and supraclinoid ICA, with markedly improved circulation time through the hemisphere.

markedly improved circulation time through the left hemisphere (Fig. 2B).

Upon emerging from anesthesia, the patient had successful reversal of expressive aphasia secondary to the vasospasm in the supraclinoid ICA. However, 90 minutes after angiography, she experienced generalized tonic-clonic seizures lasting 25 seconds, despite the fact that her phenytoin levels were therapeutic. These seizures were treated with midazolam. The rest of the patient's postoperative care was uneventful, and she was discharged to home in a stable condition. At the 3-month follow-up, she had remained seizure-free and without neurologic deficit.

3. Discussion

Several factors potentially could have precipitated the seizures in this patient with aSAH-induced cerebral vasospasm. First aneurysm induced mass effect of an MCA aneurysm pressing into the mesial aspect of the temporal lobe [2] (ICA/MCA bifurcation), perhaps less likely in this case patient based on the size of her aneurysm (5 mm) and on the fact that she had no history of seizures. Second, aSAH increases the risk for seizures, especially in surgically treated cases [12]. Our patient's history of hypertension could have played a role, but this is more commonly seen in older patients [14]. Other factors increasing the risk of seizures, such as aSAH clot thickness, the presence of a subdural hematoma, and cerebral infarctions, were not significantly present in our case patient.

Carhuapoma et al [6] reported on a case of and reviewed the literature on IA papaverine-induced seizures following aSAH. They postulated as a conceivable pathophysiologic mechanism that IA-administered papaverine may have a direct proconvulsant effect on the metabolically challenged neuronal tissue of the anterior cerebral circulation [6,15]. This on aSAH induced metabolically challenged neuronal tissue of the anterior cerebral circulation have a lowered seizure threshold in certain patients; when subsequently challenged with papaverine [6], or verapamil in our case, a seizure occurrence is precipitated.

Our patient experienced seizures despite receiving phenytoin for seizure prophylaxis. Seizure prophylaxis is common in surgically treated aSAH, although evidence for seizure prophylaxis in surgically treated aSAH has not been established in either retrospective [13] or prospective [12] controlled trials. Lin et al [11] retrospectively found that 21 (9.7%) of 217 surgically treated patients (over a 2-year period) with aSAH experienced at least one seizure episode after the first week of their operation and that perioperative seizures were not a significant predictor of epilepsy. There is no known enzymatic drug-to-drug interaction between phenytoin and verapamil. Phenytoin is known to alter the membrane potentials of Na^+ , Ca^{2+} , and K^+ , although its mechanism of action is yet to be fully elucidated ("Phenytoin" [MeSH], National Library of Medicine).

Bahls et al [3], in a retrospective series of 43 patients, reviewed the interactions between Ca^{2+} -channel blockers and the anticonvulsants carbamazepine and phenytoin. They identified toxicity occurring with both diltiazem and verapamil but not with nifedipine. Beattie et al [4] determined verapamil as the cause of carbamazepine toxicity in 2 patients with signs of carbamazepine neurotoxicity after combined treatment with verapamil. These patients showed complete recovery after verapamil was discontinued. Kishore et al [9] reported on a possible interaction and subsequent increased bioavailability of verapamil with ceftriaxone and clindamycin, which led them to encourage extreme caution in the administration of a highly protein-bound drug to a patient already receiving verapamil because of the risk of complete heart block.

4. Conclusions

Seizures during or after cerebral angiography are rare [5]. There have been occasional seizures reported with intravenous verapamil injections for other indications (Verapamil insert, American Regent, Inc, Shirley, NY). Verapamil-induced seizures, after controlled IA infusion for the reversal of cerebral vasospasm, to our knowledge have not been reported in the literature. Rechallenge with medication is the most definitive approach for showing a direct relationship between a drug and its side effects [1]. As such, our case illustrates an instance of seizures reproducibly induced by IA verapamil administration. Although IA verapamil infusion is considered to be safe [7], the potential for seizure occurrence is increased when concomitant conditions that can lower the seizure threshold of potential seizures are present [6]. Therefore, caution with IA verapamil infusion in the treatment of aSAH-induced vasospasm in certain patients is prudent.

Acknowledgments

We thank Dr Devin Binder and Dr Marlon Mathews for their constructive comments on the manuscript.

References

- [1] Arbeiter K, Greenbaum L, Balzar E, et al. Reproducible erythroid aplasia caused by mycophenolate mofetil. *Pediatr Nephrol* 2000;14:195-7.
- [2] Baeesa SS, Dang T, Keene DL, et al. Unusual association of intractable temporal lobe seizures and intracranial aneurysms in an adolescent: is it a coincidence? *Pediatr Neurosurg* 1998;28:198-203.
- [3] Bahls FH, Ozuna J, Ritchie DE. Interactions between calcium channel blockers and the anticonvulsants carbamazepine and phenytoin. *Neurology* 1991;41:740-2.
- [4] Beattie B, Biller J, Mehlhaus B, et al. Verapamil-induced carbamazepine neurotoxicity. A report of two cases. *Eur Neurol* 1988;28:104-5.
- [5] Biller J. *Iatrogenic neurology*. 1st ed. Boston: Butterworth-Heinemann; 1998. p. 31.
- [6] Carhuapoma JR, Qureshi AI, Tamargo RJ, et al. Intra-arterial papaverine-induced seizures: case report and review of the literature. *Surg Neurol* 2001;56(3):159-63.
- [7] Feng L, Fitzsimmons BF, Young WL, et al. Intraarterially administered verapamil as adjunct therapy for cerebral vasospasm: safety and 2-year experience. *AJNR Am J Neuroradiol* 2002;23:1284-90.

- [8] Kassell NF, Sasaki T, Colohan AR, et al. Cerebral vasospasm following aneurysmal subarachnoid hemorrhage. *Stroke* 1985;16:562-72.
- [9] Kishore K, Raina A, Misra V, et al. Acute verapamil toxicity in a patient with chronic toxicity: possible interaction with ceftriaxone and clindamycin. *Ann Pharmacother* 1993;27:877-80.
- [10] Lentini S, Rao ML, Schroder R, et al. QT prolongation and torsade de pointes tachycardia during therapy with maprotiline. Differential diagnostic and therapeutic aspects. *Dtsch Med Wochenschr* 2001;126:1396-400.
- [11] Lin CL, Dumont AS, Lieu AS, et al. Characterization of perioperative seizures and epilepsy following aneurysmal subarachnoid hemorrhage. *J Neurosurg* 2003;99:978-85.
- [12] Naval NS, Stevens RD, Mirski MA, et al. Controversies in the management of aneurysmal subarachnoid hemorrhage. *Crit Care Med* 2006;34:511-24.
- [13] Ogden JA, Utley T, Mee EW. Neurological and psychosocial outcome 4 to 7 years after subarachnoid hemorrhage. *Neurosurg Online* 1997;41:25-34.
- [14] Rowan AJ. Epilepsy in older adults. Common morbidities influence development, treatment strategies, and expected outcomes. *Geriatrics* 2005;60:30-2, 34.
- [15] Speckmann EJ, Walden J, Bingmann D. Functional implication of calcium ions in epileptic seizures. Antiepileptic effects of organic calcium antagonists. *Arzneimittelforschung* 1989;39:149-56.
- [16] Zaccara G, Muscas GC, Messori A. Clinical features, pathogenesis and management of drug-induced seizures. *Drug Saf* 1990;5:109-51.

Commentary

This well-written article documents a side effect associated with the use of IA verapamil during the active management of clinical vasospasm. Because there is still no definitive treatment for symptomatic vasospasm, many teams have explored a variety of medical therapies, some of which have been proven to be inefficient whereas others have been associated with significant potential risks.

The authors' data add to the body of knowledge and understanding of the risks of an adjuvant therapy for intracranial vasospasm.

Karel G. TerBrugge, MD
Department of Medical Imaging
Toronto Western Hospital
Toronto, Ontario M5T 2S8, Canada