

Piperacillin/Tazobactam-Induced Seizure Rapidly Reversed by High Flux Hemodialysis in a Patient on Peritoneal Dialysis

CHIN-SHENG LIN, MD; CHIH-JEN CHENG, MD; CHUNG-HSING CHOU, MD; SHIH-HUA LIN, MD

ABSTRACT: Despite popular use of piperacillin, the dire neurotoxicity associated with piperacillin still goes unrecognized, leading to a delay in appropriate management. We report a 57-year-old woman with end-stage renal disease receiving continuous ambulatory peritoneal dialysis (CAPD), who developed slurred speech, tremor, bizarre behavior, progressive mental confusion, and 2 episodes of generalized tonic-clonic seizure (GTCS) after 5 doses of piperacillin/tazobactam (2 g/250 mg) were given for bronchiectasis with secondary infection. The laboratory data revealed normal plasma electrolyte and ammonia levels but leukocytosis. Neurologic examinations showed dysarthria and bilateral Babinski sign. Computed tomography of brain and electroen-

cephalogram were unremarkable. Despite the use of antiepileptic agents, another GTCS episode recurred after the sixth dose of piperacillin/tazobactam. Brain magnetic resonance imaging did not demonstrate acute infarction and organic brain lesions. Initiation of high-flux hemodialysis rapidly reversed the neurologic symptoms within 4 hours. Piperacillin-induced encephalopathy should be considered in any uremic patients with unexplained neurological manifestations. CAPD is inefficient in removing piperacillin, whereas hemodialysis can rapidly terminate the piperacillin-induced encephalopathy. **KEY INDEXING TERMS:** Hemodialysis; Neurotoxicity; Piperacillin; Seizure; Uremia. [*Am J Med Sci* 2007;333(3):181-184.]

Neurotoxicity induced by penicillin and other β -lactam antibiotics is a well-documented side effect. It occurs in several vulnerable subgroups, including patients with impaired renal function, elderly patients, those receiving an excess dosage, those with blood-brain barrier injury, those with preexisting diseases of the central nervous system, and those concurrently using neurotoxic drugs.¹ Patients with penicillin-induced neurotoxicity usually present with confusion, disorientation, twitching, somnolence, myoclonus, convulsions, and nonconvulsive status epilepticus.

Piperacillin/tazobactam contains of β -lactam ureidopenicillins and β -lactamase inhibitor and is widely used for sepsis patients infected by β -lactamase producing pathogens. Piperacillin is less neurotoxic than penicillin.² Nevertheless, piperacillin-induced enceph-

alopathy (PIPE) can still occur in susceptible groups of patients. To date, 4 patients with PIPE have been reported without early recognition.³⁻⁶ Here, we describe a uremic patient receiving continuous ambulatory peritoneal dialysis (CAPD) who developed initially unrecognized PIPE that was rapidly reversed by high-flux hemodialysis.

Case Report

A 57-year-old woman with end-stage renal disease receiving CAPD for 5 years was admitted due to cough, right pleuritic pain, and fever for 3 days. She had no residual renal function (anuria). Her medical history included type 2 diabetes mellitus, bronchiectasis, and hypertensive cardiovascular disease. Her current medications were rosiglitazone, calcium citrate, amlodipine, and proceraterol.

The patient was alert and well oriented with blood pressure of 142/84 mmHg, pulse rate of 79/minute, and body temperature of 37.8°C. Crackle breathing sounds were heard over the bilateral lower lung fields. Pertinent laboratory data showed a white blood cell count of $13.7 \times 10^3/\text{mm}^3$, hemoglobin of 9.7 g/dL, platelet count of $323 \times 10^3/\text{mm}^3$, C-reactive protein level of 5.71 mg/L, and alanine aminotransferase level of 26 U/L. Chest radiography revealed bronchial wall thickening and peribronchial infiltration on both lower lung fields. Bronchiectasis with secondary infection was diagnosed.

Intravenous piperacillin/tazobactam was administered at a dosage of 2 g/250 mg every 6 hours. The patient continued CAPD with 4 2 L exchanges per day. After the fifth dose of piperacillin/tazobactam, she began to present with slurred speech, tremor, bizarre behavior, and progressive mental confusion. Two episodes

From the Division of Nephrology, Department of Medicine (CSL, CJC, SHL), and the Department of Neurology (CHC), Tri-Service General Hospital, National Defense Medical Center, Taipei, Taiwan, R.O.C.

Submitted July 25, 2006; accepted in revised form September 6, 2006.

Correspondence: Shih-Hua Lin, MD, Division of Nephrology, Department of Medicine, Tri-Service General Hospital, Number 325, Section 2, Cheng-Kung Road, Neihu 114, Taipei, Taiwan (E-mail: shihhualin@yahoo.com).

of generalized tonic-clonic seizure (GTCS) occurred later and were controlled by giving intravenous lorazepam (2 mg) and phenytoin (750 mg). On neurologic examination, the patient was drowsy with dysarthria and a bilateral Babinski sign was present. Pupils were symmetric and reactive to light; ocular fundi were normal; extraocular movements were full and conjugated. There were no meningeal signs and neither motor nor sensory focal deficits. Deep tendon reflexes were normal. Laboratory investigations showed normal plasma levels of sodium (138 mEq/L), potassium (3.6 mEq/L), chloride (99 mEq/L), calcium (10.8 mg/dL), magnesium (1.8 mg/dL), and ammonia (62 µg/dL) levels. Computed tomography of the brain and electroencephalogram were unremarkable. The diagnosis of acute ischemic stroke was made tentatively. However, the GTCS recurred after the sixth dose of piperacillin/tazobactam. Emergency magnetic resonance imaging (MRI) and angiography of the brain showed no evidence of acute infarction, aneurysm, and vascular malformation.

Because no other causes could be identified for the patient's severe neurologic manifestations, PIPE was highly suspected. The neurologic abnormalities were rapidly reversed after 4 hours high-flux hemodialysis (synthetic polysulfone, surface area 2.1 m²) and substituting ciprofloxacin for piperacillin/tazobactam. The patient was discharged 4 days later without any neurologic sequelae.

Discussion

Piperacillin is primarily eliminated unchanged by the kidneys and its elimination rate is significantly correlated with creatinine clearance.⁷ The half-life of piperacillin in individuals with creatinine clearances above 90 mL/min ranges from 1.3 to 1.5 hours. In patients with chronic renal failure (creatinine clearances less than 7 mL/min), its half-life extends 2- to threefold due to the accumulation of the drug.⁸ The generally recommended dosage of piperacillin is 4 g intravenously every 6 to 8 hours (12–16 g/day) in patients with normal renal function and the maximum recommended dosage is 8 g/day in patients whose creatinine clearances are less than 20 mL/min.⁹ In uremic patients receiving regular dialysis, administration of 2 g every 8 hours (6 g/day) has been suggested to treat serious systemic or peritoneal infections.¹⁰ Because peritoneal clearance of piperacillin is poor, with only 6% of piperacillin being removed by peritoneum,¹⁰ no supplement dose is required in patients receiving CAPD. Given the structural and pharmacokinetic characteristics of piperacillin, such as water solubility, relatively small molecular weight (517 D), and protein binding affinity (16–20%),¹¹ approximately 30% to 40% of piperacillin could be removed by hemodialysis and an additional 750 mg piperacillin should be administered after each hemodialysis session.

Our patient received 8 g/day piperacillin intravenously and developed GTCS after the fifth dose. Although the neurologic symptoms were temporarily relieved by antiepileptic agents, the GTCS recurred after the sixth dose of piperacillin and the patient rapidly recovered after receiving high-flux hemodialysis and the withdrawal of the drug. All of the above pointed to the diagnosis of PIPE and supported the effectiveness of high-flux hemodialy-

Table 1. Reported Cases of Piperacillin-Induced Encephalopathy

Case	Age/ Sex	RRF	Dialysis	Infection	Piperacillin Dosage	Neurologic Presentation	Initial Diagnosis	Treatment of PIPE	Recovery Time
1 (Park-Matsumoto, 1996)	82/F	NA	No	Subacute bacterial endocarditis	6 g daily × 5 days	Confusion, hallucinations	CNS infection ^a	WP	1 day
2 (Malanga, 1997)	11/M	Normal	No	<i>Pseudomonas aeruginosa</i> bacteremia	3 g 4 times daily × 2 days	GTCS	CNS infection ^a	WP	NA
3 (Bassilios, 2002)	46/F	NA	HD	<i>Hemophilus influenzae</i> pneumonia	4 g twice daily × 2 days	GTCS	CNS infection ^a	WP + hemodialysis × 4 hrs	2 days
4 (Tong, 2004)	47/M	3 mL/min	CAPD	Lobar pneumonia	4 g twice daily × 7 days	Acute delirium	CNS infection ^a	WP	3 days
Current case	57/F	Anuria	CAPD	Bronchiectasis with secondary infection	2 g 4 times daily × 1.5 days	GTCS	Acute cerebral infarction	WP + high-flux hemodialysis × 4 hrs	4 hour

CAPD, continuous ambulatory peritoneal dialysis; CCr, creatinine clearance; CNS, central nervous system; F, female; GTCS, generalized tonic clonic seizure; HD, hemodialysis; M, male; NA, not available; PIPE, piperacillin-induced encephalopathy; RRF, residual renal function; WP, withdrawal of piperacillin.
^a Patient underwent lumbar puncture to exclude CNS infection.

sis in removing piperacillin despite no direct measurement of serum and/or dialysate piperacillin concentrations before and after hemodialysis in this patient.

To date, 5 patients including ours have been reported to develop PIPE (Table 1). All of them presented with diverse neurologic manifestations such as confusion, drowsiness, hallucinations, myoclonus, and convulsion. Furthermore, these patients were initially misdiagnosed as having a central nervous system infection or acute cerebral infarction, leading to invasive lumbar puncture and unnecessary examinations. As in our case, the previous 2 uremic patients receiving dialysis therapy developed GTCS seizure and acute delirium after the identical dosage of piperacillin/tazobactam (8 g/1 g/day) for 7 days and 2 days, respectively. A maximum 8 g/day of piperacillin, recommended as the appropriate dosage for dialysis patients by some authors, appeared to be excessive.⁶ The precipitating factors were old age in the first patient and excess dosage in the other 4 patients.^{10,11} The neurologic symptoms often disappeared 1 to 3 days after the withdrawal of piperacillin/tazobactam. Our promising finding suggests that high-flux hemodialysis can rapidly reverse the PIPE due to its higher ultrafiltration coefficient, larger pores dialyzer membrane and higher clearance of small to middle molecular weight molecules.

The mechanisms underlying PIPE may be similar to those of penicillin. Epileptogenic properties of penicillins have been related to the β -lactam ring, and an enzymatic cleavage of this ring has resulted in the loss of epileptogenic activity.¹² The pathogenesis of seizure induced by β -lactam antibiotics involves the inhibition of γ -aminobutyric acid (GABA) binding to the GABA_A receptors.¹ It has been also shown that penicillin can reduce the number of benzodiazepine receptors, which might play a significant role in the development of PIPE.¹³ In addition to β -lactam ring, thiazolidine ring (benzylpenicillin) and substitutions of the side chain (cefazolin, cefepime) had been demonstrated to increase the high likelihood of neurotoxicity (Fig 1).^{2,12} Without any epileptogenic side chain substitutions, piperacillin is less neurotoxic than cefazolin, cefepime, and benzylpenicillin. Despite less neurotoxicity, the drug's pharmacokinetic and pharmacodynamic changes, the presence of the comorbid conditions such as old age and preexisting neurologic disorders, and the concomitant use of potential neurotoxic drugs may render the patients with chronic renal failure more vulnerable to the neurotoxic side effects of piperacillin.

In conclusion, PIPE is often either overlooked or misinterpreted as other neurologic disorders. Clinicians need to have a higher index of suspicion for PIPE when piperacillin is administered, especially in patients with impaired renal function. High-flux

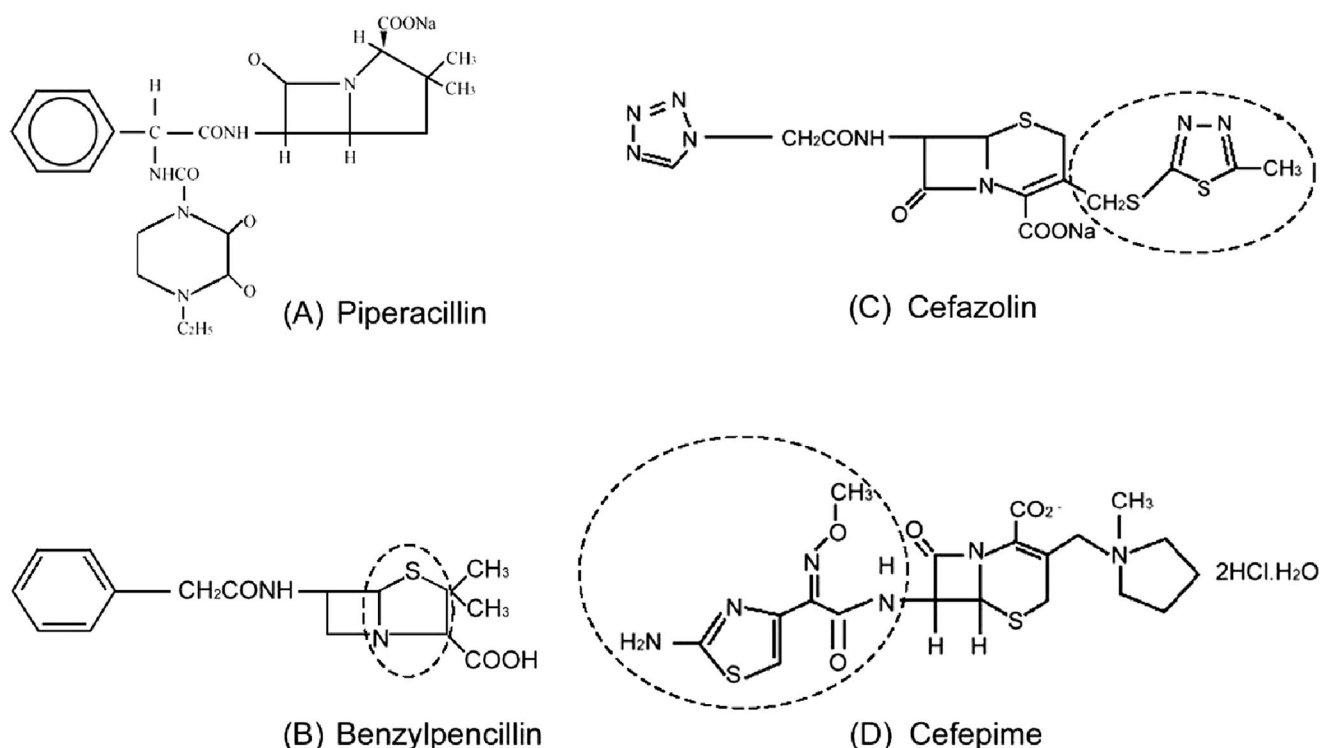


Figure 1. Piperacillin, benzylpenicillin, and cephalosporins. All have the β -lactam ring (dotted line) structure. (A) piperacillin; (B) 5-member thiazolidine ring (dotted line) in benzylpenicillin; (C, D) heterocyclic ring at position 3 and heteroaromatic nucleus at position 7 in cefazolin and cefepime, respectively.

hemodialysis can rapidly terminate the life-threatening condition associated with PIPE.

References

1. **Schliamser SE, Cars O, Norrby SR.** Neurotoxicity of β -lactam antibiotics: pre-disposing factors and pathogenesis. *J Antimicrob Chemother* 1991;27:405–25.
2. **Chow KM, Hui AC, Szeto CC.** Neurotoxicity induced by β -lactam antibiotics: from bench to bedside. *Eur J Clin Microbiol Infect Dis* 2005;24:649–6.
3. **Park-Matsumoto YC, Tazawa T.** Piperacillin-induced encephalopathy. *J Neurol Sci* 1996;140:141–2.
4. **Malanga CJ, Kokontis L, Mauzy S.** Piperacillin-induced seizures. *Clin Pediatr* 1997;36:475–8.
5. **Bassilios N, Restoux A, Vincent F, et al.** Piperacillin/tazobactam inducing seizures in a hemodialysed patient. *Clin Nephrol* 2002;58:327–8.
6. **Tong MK, Siu YP, Yung CY, et al.** Piperacillin/tazobactam-induced acute delirium in a peritoneal dialysis patient. *Nephrol Dial Transplant* 2004;19:1341.
7. **Batra VK, Morrison JA, Lasseter KC, et al.** Piperacillin kinetics. *Clin Pharmacol Ther* 1979;26:41–53.
8. **Francke EL, Appel GB, Neu HC.** Pharmacokinetics of intravenous piperacillin in patients undergoing chronic hemodialysis. *Antimicrob Agents Chemother* 1979;16:788–91.
9. **Johnson CA, Halstenson CE, Kelloway JS, et al.** Single-dose pharmacokinetics of piperacillin and tazobactam in patients with renal disease. *Clin Pharmacol Ther* 1992; 51:32–41.
10. **Debruyne D, Ryckelynck JP, Hurault De Ligny B, et al.** Pharmacokinetics of piperacillin in patients on peritoneal dialysis with and without peritonitis. *J Pharm Sci* 1990;79: 99–102.
11. **Aronoff GR, Sloan RS, Brier ME, et al.** The effect of piperacillin dose on elimination kinetics in renal impairment. *Eur J Clin Pharmacol* 1983;24:543–7.
12. **Gutnick MJ, Prince DA.** Penicillinase and the convulsant action of penicillin. *Neurology* 1971;21:759–64.
13. **Shiraishi H, Ito M, Go T, et al.** High doses of penicillin decreases [3H]flunitrazepam binding sites in rat neuron primary culture. *Brain Dev* 1993;15:356–61.