

# Evidence of Somatotopic Organization of the Sensory Thalamus Based on Infarction in the Nucleus Ventralis Posterior

Onofre Combarros, MD; José M. Polo, MD; Julio Pascual, MD; and José Berciano, MD

**Background:** This is to describe a restricted sensory syndrome of unique distribution due to thalamic infarct.

**Case Description:** We report a case of pure sensory disturbance involving the left intraoral and perioral regions and the tips of the thumb and forefinger of the left hand. Magnetic resonance imaging revealed a small infarct in the contralateral thalamus, presumably affecting the nucleus ventralis posterior.

**Conclusions:** This patient provides an excellent correlation between clinical findings and thalamic representation of body surface as established during stereotactic procedures. (*Stroke* 1991;22:1445–1447)

The cheiro-oral syndrome (from the Greek “cheiros” meaning “hand”) is a sensory disturbance affecting both the hand and the corner of the mouth on the same side, but without motor impairment. Pure sensory deficit with a cheiro-oral topography usually occurs as a result of a vascular lesion, either hemorrhage or infarction, in the region of the ventralis posterior nucleus of the thalamus<sup>1–7</sup> and in the brain stem sensory pathways projecting to this nucleus.<sup>7–11</sup> In a large survey of pure sensory stroke, Fisher<sup>12</sup> analyzed the patterns of distribution of paresthesias and suggested that selective involvement of some, rather than all, fingers indicated a cortical localization, whereas a thalamic lesion typically caused involvement of all fingers indiscriminately.

We report a case of small thalamic infarction showing a contralateral cheiro-oral syndrome with sensory impairment restricted to the tips of the thumb and forefinger. No previous cheiro-oral syndrome case has been associated with such a sensory distribution, which is consistent with the current view concerning the somatotopic representation on the human sensory thalamus.

## Case Report

A 54-year-old hypertensive woman suddenly developed burning paresthesia, as if stung by nettles, in the

tongue, oral cavity, lips, cheek, and the tips of the thumb and forefinger, all on the left side. General physical examination was unremarkable except for a blood pressure of 165/110 mm Hg. Neurological examination in the emergency room revealed no significant abnormalities, and no sensory deficit was evident. Routine blood and urine examinations, x-rays of the chest, and electrocardiogram were normal. Brain computed tomography with and without contrast was normal.

Three months after its onset, she continued to complain of persistent burning in the left oral cavity and tongue. These dysesthetic sensations were aggravated by exposure to extremes of temperature, especially hot liquids and food. Taste was unaffected. Pins-and-needles paresthesia affected the left upper and lower lips, adjacent face, and the tips of the two medial fingers, and touching over these areas caused electriclike sensations. Sensory examination revealed decreased left intraoral pain and light touch sensation. Sensation to pinprick was diminished in the left perioral structures and in the tips of the first and second fingers of the left hand, but these areas were hyperesthetic to light touch. Proprioceptive sensation, however, was preserved.

Magnetic resonance imaging (MRI) at this time showed an area of increased signal on the T<sub>2</sub>-weighted scan in the right inferolateral thalamus (Figure 1). The somatosensory evoked potentials elicited by left median nerve stimulation showed absent N20 and subsequent responses on the contralateral sensory cortex.

Two years later, moderate to severe distress from unpleasant paresthesia had not significantly changed.

From the Service of Neurology, University Hospital “Marqués de Valdecilla,” Faculty of Medicine, Santander, Spain.

Address for correspondence: José Berciano, MD, Service of Neurology, University Hospital “Marqués de Valdecilla,” 39008 Santander, Spain.

Received April 12, 1991; accepted July 17, 1991.

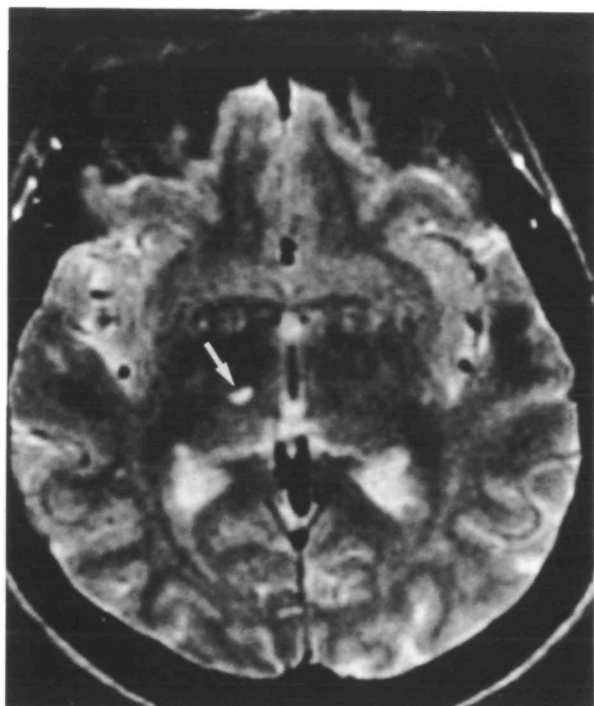


FIGURE 1.  $T_2$ -weighted magnetic resonance imaging revealing lacunar infarction in the area corresponding to ventralis posterior nucleus (arrow).

Treatment with carbamazepine, imipramine, amitriptyline, and mexilitine had produced no effect. Reexamination showed that sensory signs remained confined to the same distribution.

### Discussion

The traditional view has held that the cheiro-oral syndrome is a combined unilateral sensory distur-

bance limited to the peribuccal area and palm of the hand and fingers. In fact, most previously reported cases showed this stereotyped pattern (Table 1). Paresthesia or numbness referable to the face occurred in one half of the patients, and sensory defect localized within the mouth was encountered in only one third. An unusual cheiro-oral syndrome with bilateral oral involvement has been described in one case of small pontine hemorrhage.<sup>11</sup> Characteristically, all the fingers were equally affected.

In a detailed clinical study of pure sensory stroke, Fisher<sup>12</sup> proposed patterns of sensory deficit to predict the localization, thalamic or cortical, of the vascular lesion. Patients with occlusive disease of a penetrating thalamic branch artery had paresthesia of the face, arm, and leg on one side, and all fingers of that side were affected. However, in occlusion of the internal carotid and middle cerebral arteries, paresthesias were usually restricted to a faciobrachial or brachial topography, with some fingers more impaired than others. A similar pattern was described in a patient with a small cortical infarction affecting the parietal region, accompanied by sudden onset of pure sensory deficit in the three medial fingers of the right hand and in the right foot.<sup>13</sup>

The limited sensory deficit in the tips of the thumb and forefinger, as described in our case, is extremely unusual in cheiro-oral syndrome caused by a thalamic infarct. In this respect, our case is similar to that reported by Garcin and Lapresle,<sup>2</sup> who described numbness in the right peribuccal region, the radial edge of the forearm, and the first to third fingers of the right hand; at autopsy a lacune was found in the ventralis posterior nucleus of the contralateral thalamus. In our patient MRI revealed a

TABLE 1. Summary of Previous Reports of Cheiro-Oral Syndrome

Reference	Distribution						Lesion location	Identification
	IO	PO	F	D	H	FA		
Garcin and Lapresle <sup>1</sup>		+				+	VP thalamic infarct	Autopsy
Garcin and Lapresle <sup>2</sup>		+		+		+	VP thalamic infarct	Autopsy
Fisher, <sup>3</sup> Case 9	+	+		+			VP thalamic infarct	Autopsy
Fisher, <sup>4</sup> Case 1	+	+	+	+			VP thalamic infarct	Autopsy
Case 2	+	+	+	+	+	+	VP thalamic infarct	Autopsy
Ono and Inoue <sup>8</sup>		+	+		+		Midbrain hemorrhage	CT
Valzelli <sup>5</sup>		+		+	+		Thalamic infarct	CT
Araga et al, <sup>9</sup> Case 1		+		+	+		Dorsolateral pontine hemorrhage	CT
Case 2		+	+	+	+		Dorsolateral pontine hemorrhage	CT
Awada <sup>6</sup>	+	+	+	+	+		Thalamic infarct	MRI
Kawakami et al, <sup>7</sup> Case 1	+	+	+	+	+	+	Pontine infarct	MRI
Case 2		+		+	+		Thalamic hemorrhage	CT
Case 3		+		+	+		Thalamic infarct	MRI
Case 4		+	+	+	+		Pontine hemorrhage	CT
Iwasaki et al <sup>10</sup>		+		+	+		Thalamic hemorrhage	CT
Matsumoto et al, <sup>11</sup> Case 1	+	+	+		+		Pontine hemorrhage	CT/MRI
Case 2		+		+			Pontine hemorrhage	CT/MRI

IO, intraoral; PO, perioral; F, face; D, digits; H, hand; FA, forearm; VP, ventralis posterior nucleus; CT, computed tomography; MRI, magnetic resonance imaging.

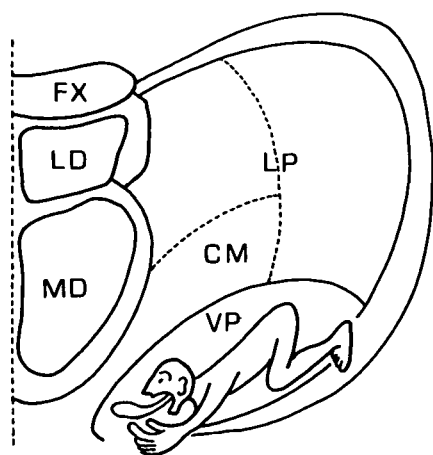


FIGURE 2. Homunculus representation in the ventralis posterior nucleus in its coronal section. Adapted from Ohye.<sup>14</sup> FX, formix; LD, nucleus lateral dorsal; MD, nucleus medial dorsal; CM, nucleus centrum medianum; LP, nucleus lateral posterior; VP, nucleus ventralis posterior.

small inferolateral thalamic infarct that presumably involved that nucleus.

The particular topography of sensory deficit in our patient exactly conforms to the representation of body surface in the ventralis posterior nucleus, as obtained from microelectrode mapping techniques during stereotactic thalamotomy for treatment of involuntary motor disturbances.<sup>14</sup> These studies indicate that in the ventralis posterior nucleus, the principal rule of the somatotopic representation is face, upper limb, and lower limb, progressing to its dorsolateral pole. The tongue extrudes most medially, and the fingers, especially the thumb, are located adjacent to the former, as shown in the homunculus proposed by Ohye<sup>14</sup> (Figure 2). An organization comparable to that existing in human sensory thalamus has been described in primates by Kaas et al,<sup>15</sup> who emphasized that the representation of tips of the digits occupies a relatively large portion of the ventralis posterior nucleus. These cases help to explain how a limited sensory disturbance, such

as that of our patient, can be produced by a small infarction in this thalamic area.

### Acknowledgments

The authors thank Dr. María Teresa Berciano for the redrawing of Figure 2 and Mrs. Marta de la Fuente for secretarial assistance.

### References

1. Garcin R, Lapresle J: Syndrome sensitif de type thalamique et à topographie chéiro-orale par lésion localisée du thalamus. *Rev Neurol* 1954;90:124-129
2. Garcin R, Lapresle J: Deuxième observation personnelle de syndrome sensitif de type thalamique et à topographie chéiro-orale par lésion localisée du thalamus. *Rev Neurol* 1960;103:474-481
3. Fisher CM: Pure sensory stroke involving face, arm and leg. *Neurology* 1965;15:76-80
4. Fisher CM: Thalamic pure sensory stroke: A pathologic study. *Neurology* 1978;28:1141-1144
5. Valzelli L: About the cheiro-oral syndrome. *Neurology* 1987;37:1564-1565
6. Awada A: Fourmillements cheiro-faciaux isolés par hématome thalamique. *Rev Neurol* 1989;145:861-862
7. Kawakami Y, Chikama M, Tanimoto T, Shimamura Y: Radiological studies of the cheiro-oral syndrome. *J Neurol* 1989;236:177-181
8. Ono S, Inoue K: Cheiro-oral syndrome following midbrain haemorrhage. *J Neurol* 1985;232:304-306
9. Araga S, Fukada M, Kagimoto H, Takahashi K: Pure sensory stroke due to pontine haemorrhage. *J Neurol* 1987;235:116-117
10. Iwasaki Y, Kinoshita M, Ikeda K, Takamiya K, Shiojima T: Pure sensory stroke and cheiro-oral syndrome. *J Neurol* 1989;236:186-187
11. Matsumoto S, Kaku S, Yamasaki M, Imai T, Nabatame H, Kameyama M: Cheiro-oral syndrome with bilateral oral involvement: A study of pontine lesions by high-resolution magnetic resonance imaging. *J Neurol Neurosurg Psychiatry* 1989;52:792-794
12. Fisher CM: Pure sensory stroke and allied conditions. *Stroke* 1982;13:434-447
13. Derouesné C, Mas JL, Bolgert F, Castaigne P: Pure sensory stroke caused by a small cortical infarct in the middle cerebral artery territory. *Stroke* 1984;15:660-662
14. Ohye C: Thalamus, in Paxinos G (ed): *The Human Nervous System*. San Diego, Calif, Academic Press, Inc, 1990, pp 439-468
15. Kaas JH, Nelson RJ, Sur M, Dykes RW, Merzenich MM: The somatotopic organization of the ventroposterior thalamus of the squirrel monkey, *Saimiri sciureus*. *J Comp Neurol* 1984;226:111-140

KEY WORDS • cerebral infarction • hypesthesia • thalamus

## Evidence of somatotopic organization of the sensory thalamus based on infarction in the nucleus ventralis posterior.

O Combarros, J M Polo, J Pascual and J Berciano

*Stroke*. 1991;22:1445-1447

doi: 10.1161/01.STR.22.11.1445

*Stroke* is published by the American Heart Association, 7272 Greenville Avenue, Dallas, TX 75231

Copyright © 1991 American Heart Association, Inc. All rights reserved.

Print ISSN: 0039-2499. Online ISSN: 1524-4628

The online version of this article, along with updated information and services, is located on the World Wide Web at:

<http://stroke.ahajournals.org/content/22/11/1445>

**Permissions:** Requests for permissions to reproduce figures, tables, or portions of articles originally published in *Stroke* can be obtained via RightsLink, a service of the Copyright Clearance Center, not the Editorial Office. Once the online version of the published article for which permission is being requested is located, click Request Permissions in the middle column of the Web page under Services. Further information about this process is available in the [Permissions and Rights Question and Answer](#) document.

**Reprints:** Information about reprints can be found online at:  
<http://www.lww.com/reprints>

**Subscriptions:** Information about subscribing to *Stroke* is online at:  
<http://stroke.ahajournals.org/subscriptions/>