

Delayed Manifestation and Slow Progression of Cerebral Infarction Caused by Polycythemia Rubra Vera

HITOSHI KURABAYASHI, MD; AKIKO HISHINUMA, MD; RYUSEI UCHIDA, MD; SHIGERU MAKITA, MD; MITSURU MAJIMA, MD

ABSTRACT *Background:* Polycythemia rubra vera is often found after the manifestation of cerebral infarction, though the pathogenesis is still controversial. We present a case of cerebral infarction secondary to polycythemia rubra vera, which presented a slow expansion on magnetic resonance imaging despite severe hemiplegia. This case suggests a possible mechanism for development of cerebral infarction in polycythemia rubra vera. *Methods:* This case report was conducted in a university hospital. Magnetic resonance imaging and diffusion-weighted imaging were performed to assess the evolution of infarction, and the total blood volume and cerebral blood flow were determined with the use of isotopes, ^{51}Cr and $^{99\text{m}}\text{Tc}$, respectively. Phlebotomy was performed, but intervention was not applicable. The manual muscle test and sensory disturbance were assessed by the same physiotherapist throughout the clinical course. *Results:* A 64-year-old male patient with polycythemia rubra

vera had a cerebral infarction. A subtle change was observed on CT scan on the third day after the onset of infarction, and a small signal was demonstrated on magnetic resonance imaging on the fourth day. The cerebral infarction expanded slowly in size and reached a maximum on day 24. A diagnosis of cerebral infarction secondary to polycythemia rubra vera was made, and treatment by phlebotomy, hydration, and hydroxyurea was begun. Though the hemiplegia remained, he became ambulatory with a brace, as do patients with atherosclerotic infarction. *Conclusions:* It is suggested that the delayed manifestation and slow expansion of cerebral infarction caused by elevated hematocrit might be derived from a pathogenesis different from atherosclerotic infarction. **KEY INDEXING TERMS:** Polycythemia rubra vera; Cerebral infarction; CT scan; Magnetic resonance imaging. [*Am J Med Sci* 2007;333(5):317–320.]

It is generally accepted that cerebral infarction is triggered by plaque rupture, based on atherosclerosis, and is detected on magnetic resonance imaging (MRI) just after the onset.¹ Polycythemia rubra vera (PRV) is often found or diagnosed by the manifestation of thrombosis.² The process to form a thrombus in PRV would be different from that of atherogenic infarction, which has systemic vascular atherosclerosis, stenosis or obstruction of the cerebral arteries, plaque rupture with platelet aggregation, and hypertension or metabolic syndrome.³ Therefore, the characteristics of cerebral infarction caused by PRV may be different from that by atherosclerosis. Some authors have reported the hemorheology in PRV and the association with thrombosis,^{4–6} although little is

known about the differences in clinical features or MRI findings between cerebral infarctions caused by atherosclerosis and polycythemia. We report a patient with cerebral infarction based on PRV, in whom complete hemiplegia and motor aphasia were observed, although no abnormal findings were noted on the CT scan for 3 days after the onset and a small and abnormal signal was found on MRI on day 4. Thereafter, the lesion expanded slowly and peaked in size at 24 days after the onset.

Case Report

A 64-year-old male patient consulted a regional hospital because of left hemiplegia after repeated transient ischemic attacks including left hemiparesis lasting for 4 to 5 hours 10 and 12 days previously, although CT scan of the brain had shown no abnormal findings. On the next day, or day 2, he was referred to our hospital because the hemiplegia deteriorated with no abnormal findings on repeated CT scan and the blood examination revealed polycythemia. On admission, he presented left hemiplegia of 3/5 by manual muscle test and moderate dysarthria, although the CT scan showed no abnormal findings. The blood cell counts were elevated as follows; erythrocyte count, $6.99 \times 10^{12}/\text{L}$; hematocrit, 60.2%; hemoglobin concentration, 194 g/L; platelet count, $560.0 \times 10^9/\text{L}$; and leucocyte count, $34.16 \times 10^9/\text{L}$, with 1.0% myelocytes,

From the Department of Rehabilitation Medicine, Saitama Medical University, Moroyama, Japan.

Submitted August 1, 2006; accepted in revised form October 19, 2006.

Correspondence: Hitoshi Kurabayashi, MD, Department of Rehabilitation Medicine, Faculty of Medicine, Saitama Medical University, 38 Morohongo, Moroyama, Iruma, Saitama 350-0495, Japan (E-mail: hkuraba@saitama-med.ac.jp).

Cerebral Infarction by Polycythemia

4.0% band forms, 84.0% mature neutrophilic granulocytes, 2.0% lymphocytes, 6.0% monocytes, 2.0% eosinophilic granulocytes, and 1.0% basophilic granulocytes. The laboratory findings were as follows: total bilirubin, 13.7 $\mu\text{mol/L}$; LDH, 7.33 $\mu\text{kat/L}$; creatinine, 56.7 $\mu\text{mol/L}$; uric acid, 297 $\mu\text{mol/L}$; total cholesterol, 4.73 mmol/L; triglyceride, 1.05 mmol/L; fasting blood sugar, 5.50 $\mu\text{mol/L}$; and international normalized ratio of prothrombin time, 1.24. The serum levels of HDL-cholesterol and homocysteine were not determined. In addition, cerebrospinal fluid showed no abnormalities. His periodic medical checkup showed no evidence of hypertension, and his body mass index was 21.3 kg/m^2 . He had no episodes of dizziness, hypotension, or arrhythmia and no habits of smoking and drinking alcohol. His parents, sisters, and a brother had no history of thrombosis and hyperlipidemia, though his younger sister and brother had hypertension and diabetes mellitus, respectively. A tentative diagnosis of cerebral infarction was made, and conservative therapy including glycerol, sodium oza-grel, and hydration was started, though no evidence was found on the brain CT scan. The next morning, disease day 3, his hemiplegia developed to 0/5 by manual muscle test. However, the CT scan of the brain showed a subtle change in the white matter of the right frontal lobe (Figure 1a). The electrocardiogram and echo-

cardiogram showed no findings suggestive of heart disease. Echography showed that the long axis of the spleen was 10.0 cm. The serum levels of ferritin, erythropoietin, and vitamin B₁₂ were 9.0 $\mu\text{g/L}$, 11.1 (normal range, 0.0 to 29.0) IU/L, and 1051 pmol/L, respectively. Neutrophil alkaline phosphatase was 98% positive and 376 in score. The total blood volume and total red cell volume were 89.7 and 43.6 mL/100 g per kilogram, respectively. Bone marrow aspirate showed marked erythropoiesis without increasing blasts, and the karyotype of bone marrow cells presented 46XY. Blood gas analysis and chest radiographic examination showed no evidence of pulmonary diseases. A definite diagnosis of PRV was made. Therapy including edaravone, argatroban, and heparin was begun. Furthermore, phlebotomy was initiated on disease day 3. The next day (day 4), MRI demonstrated a small, abnormal signal in the frontal lobe, and diffusion-weighted imaging showed prominent and abnormal signals in the frontal and temporal lobes (Figure 1b and c). They made a diagnosis of middle cerebral artery infarction with extension into the anterior cerebral/middle cerebral artery territory. Magnetic resonance angiography showed no evidence of atherosclerosis and stenosis in the cerebral arteries, and the carotid echogram demonstrated neither plaque nor stenosis in the cervical arteries. Taken together, it

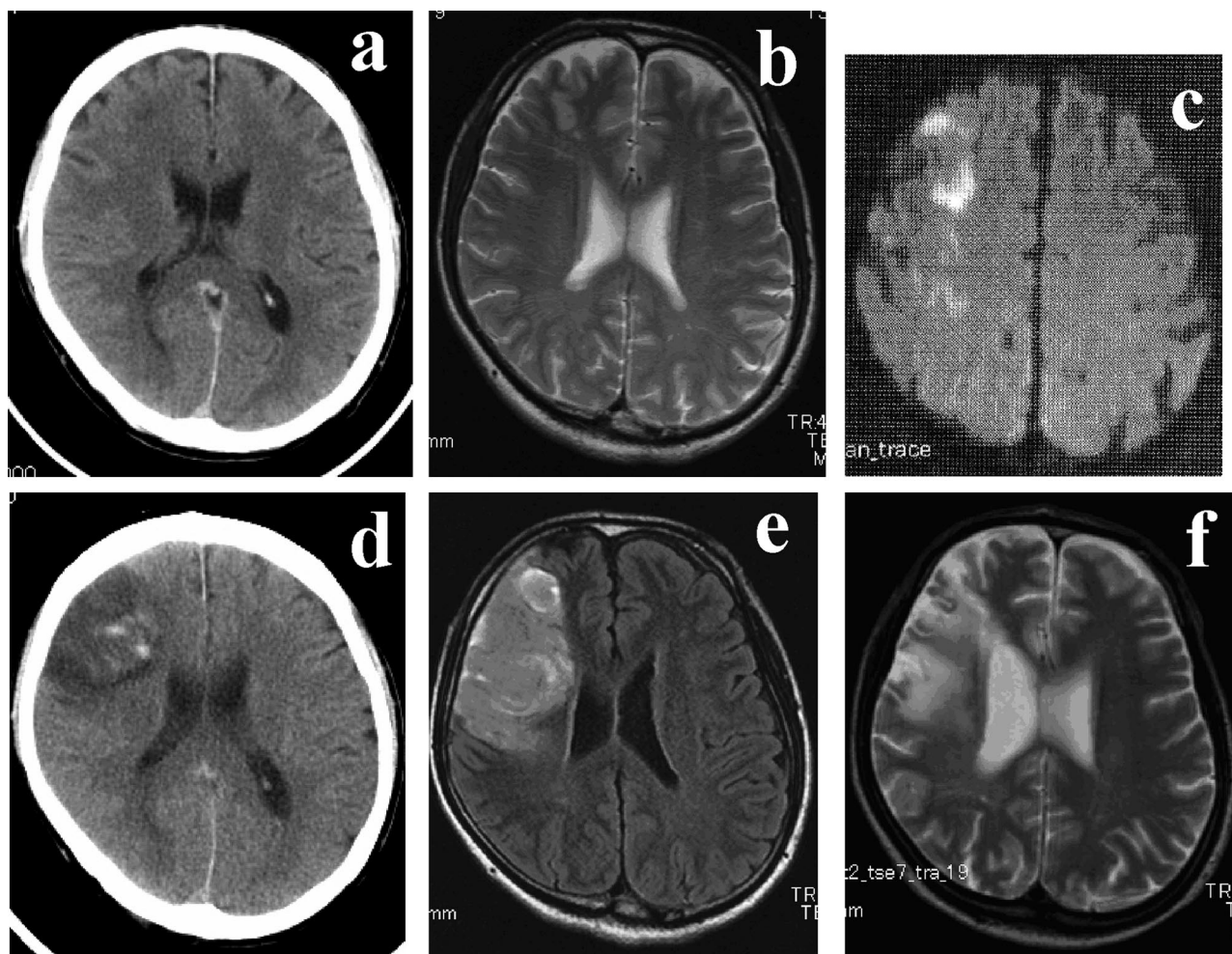


Figure 1. a, CT scan on day 3. A subtle change in the white matter of the right frontal lobe was found, although the patient presented complete hemiplegia. b and c, MRI and diffusion-weighted imaging on day 4. First appearance of abnormal signal was small in the frontal lobe on MRI but prominent in right frontal and temporal lobes on diffusion-weighted imaging, which was compatible with middle cerebral artery infarction extended to the anterior/middle cerebral artery territory. d, CT scan on day 17. e, MRI on day 24. The abnormal signal became maximum in size and thereafter decreased gradually. f, MRI on day 183. The abnormal signal decreased in size and strength.

was concluded that the cerebral infarction was caused by PRV alone and not by atherosclerosis. Phlebotomy was continued until the hematocrit decreased to a normal value, disease day 10. Aspirin and hydroxyurea were given orally after the cessation of edaravone, argatroban, and heparin. Single-photon emission-computed tomography with technetium-99m ethyl cysteinate dimer on disease day 14 showed decreased blood flow in both hemispheres as follows: mean cerebral blood flow in the right hemisphere, 37.1 mL/100 g per minute; left hemisphere, 37.5 mL/100 per minute. The lesion of cerebral infarction on MRI on disease day 24 showed a maximum size (Figure 1e) and thereafter decreased slowly (Figure 1f). A rehabilitation program including physical, occupational, and speech therapies was begun on disease day 5. He could walk with a cane and a short leg brace and speak fluently when he was discharged 2 months after the onset. The rehabilitation course or recovery of motor function was almost equal to that of cerebral infarction based on atherosclerosis.

Discussion

Our patient fulfilled the criteria of PRV⁷ and presented complete hemiplegia and motor aphasia due to acute cerebral infarction with no evidence of atherosclerosis nor possible cause of embolism. The infarction, therefore, was concluded to be derived not from atherosclerosis but from elevated erythrocyte volume. Although left hemiplegia was evident, CT scan of the brain demonstrated a subtle change in the white matter of the frontal lobe 3 days after the onset and MRI showed small signals on disease day 4. Furthermore, the lesion of cerebral infarction increased slowly in size on MRI, peaked on disease day 24, and then decreased slowly in size. In contrast to the cerebral infarction based on atherosclerosis, the cerebral infarction secondary to PRV appeared transiently and expanded slowly on MRI. It is generally accepted that the lesion is detected on MRI several hours after the onset of cerebral infarction and that the size of the abnormal signal develops and reaches a maximum by day 5 to 7.^{1,8,9} The delayed manifestation and slow expansion of the lesion on CT scan and MRI might be explained by the lack of atherosclerosis and endothelial injury in cerebral infarction secondary to PRV.

Thrombosis was reported to be found in 43% of the patients with PRV,¹⁰ although it is still controversial how erythrocytosis develops to cerebral infarction. Previous reports have indicated that the pathogenesis of cerebral infarction secondary to PRV would be caused by embolic infarct, hemodynamic infarct, and prothrombotic state. Pearce et al¹⁰ and Fiermonte et al¹¹ inferred that the increased erythrocytes obstructed small vessels to form embolic infarct. Harrison¹² reasoned that erythrocytosis resulted in a decrease in plasma volume, leading to relative thrombocytosis and accelerating thrombogenesis to form hemodynamic infarct. Segura et al¹³ and Koennecke et al¹⁴ deduced that increased erythrocytes volume made cerebral blood flow decrease to form a prothrombotic state. Although it is difficult to classify our case into these pathogeneses, the endothelial injury and ruptured plaque did not exist in

our case, which might have resulted in the slow expansion of tissue necrosis developing despite ischemia, compared with atherosclerotic infarction. The pathogenesis is different from that of atherosclerotic infarction, in which activated platelets would adhere and aggregate on ruptured plaque, trigger a coagulation cascade, and involve leukocytes and erythrocytes, resulting in a platelet-rich thrombus connected tightly to injured endothelial cells and rapid expansion of brain necrosis.

Some other reasoning from the viewpoint of MRI principles may be proposed. Increased erythrocytes might supply more oxygen to brain tissue, resulting in lower cytotoxic edema. A large number of erythrocytes would contain many ions or much iron to hinder detection of the change of signal on MRI. Increasing tissue hematocrit could make the abnormally high signal difficult to detect on MRI. These factors consisting of MRI principles might modify the appearance of signals to some extent in the case of erythrocythemia, although few reports have shown any association between the appearance of cerebral infarction on MRI and the degree of anemia or erythrocytosis. We reported previously that cerebral blood flow and cerebral metabolic rate of oxygen measured by positron emission tomography by using a continuous ¹⁵O inhalation method were decreased in patients with polycythemia and that both cerebral blood flow and cerebral metabolic rate of oxygen were increased after the normalization of hematocrit by phlebotomy.¹⁵ These results suggested that the overall content of oxygen in cerebral tissue in polycythemic patients was decreased in combined consequence of the decreased blood flow that reduced oxygen supply to brain tissue and the increased erythrocytes that elevated oxygen content in brain tissue. Considered together, the delayed manifestation of cerebral infarction in our case might be explained by the absence of atherosclerosis rather than oxygen supply. In addition, as the lesion on MRI expanded gradually after the phlebotomy in our case, the possibly increased ions or iron would have no effect on hindering detection of the manifestation or expansion of the lesion on MRI.

The CT and MRI findings demonstrated that the cerebral infarction was partly attributable to watershed territory of anterior and middle cerebral arteries. The watershed infarction was reported to be caused mainly by a hemodynamic event such as hypotension, internal carotid artery occlusion, or elevated hematocrit and to evolve slowly because of progressive loss of collateral circulation.^{16,17} The cerebral infarction secondary to polycythemia rubra vera is speculated to compromise collateral flow through sludging or hyperviscosity. The slow evolution of our patient, therefore, might be referred to as sludging caused by elevated hematocrit.

The rehabilitation course or recovery of motor function was almost equal to that of cerebral infarc-

tion caused by atherosclerosis in our rehabilitation unit. A previous study reported that the average functional recovery or gain in functional independence measurement score after rehabilitation therapy was 23.3 for patients with ischemic stroke.¹⁸ The motor functional independence measurement score was improved from 44 to 67 in the rehabilitation unit in our case. Although the progression of cerebral infarction on MRI was delayed and slow, once the thrombosis was completed, its recovery might be the same as that of atherosclerotic infarction.

Conclusion

Our case suggested that the lesion on MRI and CT appears slowly in a patient with cerebral infarction secondary to erythrocytosis. The slow clinical evolution may be explained by sludging caused by increased erythrocyte volume. Once hemiplegia is completed, the recovery process of motor function would be almost the same as that of atherosclerosis. It is therefore recommended that cerebral infarction caused by erythrocytosis should be treated by phlebotomy and hydration after a clinical diagnosis is made, although a definite diagnosis cannot be obtained by CT or MRI.

References

1. **Jenson MC, Brant-Zawadzki MN, Jacobs BC.** Brain ischemia. In: Stark, DD Bradley WG Jr, eds, *Magnetic Resonance Imaging*. St. Louis: Mosby. 1999;1255–75.
2. Gruppo Italiano Studio Policitemica: polycythemia vera: the natural history of 1213 patients followed for 20 years. *Ann Intern Med* 1995;125:656–4.
3. **Falke E.** Plaque rupture with severe pre-existing stenosis precipitating coronary thrombosis. *Br Heart J* 1993;750:31–4.
4. **Berk PD, Boldberg JB, Donovan PB, et al.** Therapeutic recommendations in polycythemia vera based on Polycythemia Vera Study Group protocols. *Semin Hematol* 1986;23: 132–43.
5. **Pearson TC.** Hemorheologic considerations in the pathogenesis of vascular occlusive events in polycythemia vera. *Semin Thromb Hemost* 1997;23:433–9.
6. **Harrison MJ.** Influence of hematocrit in the cerebral circulation. *Cerebrovasc Brain Metab Rev* 1989;1:55–67.
7. **Means RT Jr.** Polycythemia vera. In: Greer JP, Foerster J, Lukens JN, Rodgers GM, Paraskevas F, Glader B, editors. *Wintrobe's Clinical Hematology*. Philadelphia: Lippincott Williams & Wilkins; 2004; p. 2259–72.
8. **Lee HS, Walter JK, Gregory SA, et al.** Time course of lesion development in patients with acute stroke: serial diffusion- and hemodynamic weighted magnetic resonance imaging. *Stroke* 1998;29:2268–76.
9. **van Everdingen KI, van der Grond J, Kapelle LJ, et al.** Diffusion-weighted magnetic resonance imaging in acute stroke. *Stroke* 1998;29:1783–90.
10. **Pearce JM, Chandrasekera CP, Ladusans EJ.** Lacunar infarcts in polycythemia with raised packed cell volumes. *Br Med J* 1983;287:9356.
11. **Fiermonte G, Aloe Spiriti MA, Latagliata R, et al.** Polycythemia vera and cerebral blood flow: a preliminary study with transcranial Doppler. *J Intern Med* 1993;234:599–602.
12. **Harrison MJ.** Influence of hematocrit in the cerebral circulation. *Cerebrovasc Brain Metab Rev* 1989;1:55–67.
13. **Segura T, Serena J, Teruel J, et al.** Cerebral embolism in a patient with polycythemia rubra vera. *Eur J Neurol* 2000; 7:87–90.
14. **Koennecke HC, Bernarding J.** Diffusion-weighted magnetic resonance imaging in two patients with polycythemia rubra vera and early ischemic stroke. *Eur J Neurol* 2001;8: 273–7.
15. **Shirakura T, Kubota K, Kurabayashi H, et al.** Effect of phlebotomy on viscosity, cerebral blood flow and cerebral metabolic rate of oxygen in polycythemic elderly patients. In: Bravo S, Gonzales J, editors. *Proceedings of the 14th International Congress Gerontology*; 1989 June 18–23; Acapulco, Mexico. Mexico, D.F.: Mexico; 1989; p. 267.
16. **Bogousslavsky J, Regli F.** Unilateral watershed cerebral infarcts. *Neurol* 1986;36:373–7.
17. **Momijian-Mayor I, Baron JC.** The pathophysiology of watershed infarction in internal carotid artery disease: review of cerebral perfusion studies. *Stroke* 2005;36:567–77.
18. **Kelly P, Furie KL, Shafqat S, et al.** Functional recovery following rehabilitation after hemorrhagic and ischemic stroke. *Arch Phys Med Rehabil* 2003;84:968–72.