

This is the first controlled study of BLT in PD. We conclude that it is a safe, easy to use, and inexpensive nonpharmacological treatment option, which significantly improves tremor and most noncardinal features of PD. However, our study must be regarded as exploratory, and we are aware that absolute changes were moderate, most probably due to the mild clinical symptoms of the included patients and the short treatment duration. As our results raise the possibility that—at least for depression—more severely affected patients show a greater response, future examinations of BLT in PD should focus on more advanced patient populations and treatment durations of at least four weeks.

REFERENCES

1. Terman M, Terman JS. Light therapy for seasonal and nonseasonal depression: efficacy, protocol, safety, and side effects. *CNS Spectr* 2005;10:647-663.
2. Srinivasan V, Pandi-Perumal SR, Maestroni GJ, Esquifino AI, Hardeland R, Cardinali DP. Role of melatonin in neurodegenerative diseases. *Neurotox Res* 2005;7:293-318.
3. Zisapel N. Melatonin-dopamine interactions: from basic neurochemistry to a clinical setting. *Cell Mol Neurobiol* 2001;21:605-616.
4. Willis GL, Armstrong SM. A therapeutic role for melatonin antagonism in experimental models of Parkinson's disease. *Physiol Behav* 1999;66:785-795.
5. Willis GL, Robertson AD. Recovery of experimental Parkinson's disease with the melatonin analogues ML-23 and S-20928 in a chronic, bilateral 6-OHDA model: a new mechanism involving antagonism of the melatonin receptor. *Pharmacol Biochem Behav* 2004;79:413-429.
6. Bordet R, Devos D, Brique S, et al. Study of circadian melatonin secretion pattern at different stages of Parkinson's disease. *Clin Neuropharmacol* 2003;26:65-72.
7. Catala MD, Canete-Nicolas C, Iradi A, Tarazona PJ, Tormos JM, Pascual-Leone A. Melatonin levels in Parkinson's disease: drug therapy versus electrical stimulation of the internal globus pallidus. *Exp Gerontol* 1997;32:553-558.
8. Chaudhuri KR, Healy DG, Schapira AH; National Institute for Clinical Excellence. Non-motor symptoms of Parkinson's disease: diagnosis and management. *Lancet Neurol* 2006;5:235-245.
9. Lam RW, Levitt AJ, Levitan RD, Enns MW, Morehouse R, Michalak EE, Tam EM. The Can-SAD study: a randomized controlled trial of the effectiveness of light therapy and fluoxetine in patients with winter seasonal affective disorder. *Am J Psychiatry* 2006;163:805-812.
10. Fertl E, Auff E, Doppelbauer A, Waldhauser F. Circadian secretion pattern of melatonin in de novo parkinsonian patients: evidence for phase-shifting properties of l-dopa. *J Neural Transm Park Dis Dement Sect* 1993;5:227-234.
11. Dell'Agnello G, Caravolo R, Nuti A, et al. SSRIs do not worsen Parkinson's Disease: evidence from an open-label, prospective study. *Clin Neuropharm* 2001;4:221-227.
12. Lemke MR, Fuchs G, Gemende I, et al. Depression and Parkinson's disease. *J Neurol* 2004;251:24-27.
13. Paus S, Brecht HM, Koster J, Seeger G, Klockgether T, Wullner U. Sleep attacks, daytime sleepiness, and dopamine agonists in Parkinson's disease. *Mov Disord* 2003;18:659-667.
14. Ruger M, Gordijn MC, Beersma DG, de Vries B, Daan S. Weak relationships between suppression of melatonin and suppression of sleepiness/fatigue in response to light exposure. *J Sleep Res* 2005;14:221-227.
15. Arnulf I, Konofal E, Merino-Andreu M, et al. Parkinson's disease and sleepiness: an integral part of PD. *Neurology* 2002;58:1019-1024.

Alien Limb Following Posterior Cerebral Artery Stroke: Failure to Recognize Internally Generated Movements?

Elizabeth Coulthard, BA, MRCP,^{1,2*}
 Anthony Rudd, MB, BChir, FRCP (London),^{3,4}
 E. Diane Playford, MD, FRCP,⁵ and
 Masud Husain, DPhil, FRCP^{1,2}

¹Institute of Neurology, University College London, London, United Kingdom; ²Institute of Cognitive Neuroscience, University College London, London, United Kingdom; ³St Thomas' Hospital, London, United Kingdom; ⁴King's College, London, United Kingdom; ⁵Rehabilitation Group, Institute of Neurology, London, United Kingdom

Video



Abstract: We describe two rare cases of alien limb syndrome following right posterior cerebral artery (PCA) stroke. Both patients present with left hemianopia, visual neglect and proprioceptive loss in addition to their alien limb symptoms. Lesion subtraction from seven control PCA patients revealed that medial parietal-occipital and thalamic areas were selectively damaged in the alien limb patients. We propose that loss of the sense of motor intention and internal model of the current state of the arm, combined with deficient proprioceptive and visual feedback of the moving limb, are critical for genesis of posterior alien limb and discuss how affected regions normally function to ensure awareness of self-generated motor activity. © 2007 Movement Disorder Society

Key words: alien hand; intention; sensory alien limb; awareness; motor preparation

This article includes supplementary video clips, available online at <http://www.interscience.wiley.com/jpages/0885-3185/suppmat>.

*Correspondence to: Dr. E. Coulthard, Institute of Neurology and Institute of Cognitive Neuroscience, University College London, 17 Queen Square, London, WC1N 3AR, UK.
 E-mail: l.coulthard@ion.ucl.ac.uk

Received 15 January 2007; Revised 16 March 2007; Accepted 1 April 2007

Published online 21 May 2007 in Wiley InterScience (www.interscience.wiley.com). DOI: 10.1002/mds.21546

Alien limb syndrome, comprising involuntary and uncontrollable movements of a limb accompanied by the subjective complaint that it feels foreign or alien, is an uncommon consequence of stroke. Most cases follow damage to anterior medial frontal brain regions often including the corpus callosum. In such cases, alien limb is thought to result from intermanual conflict, due to disconnection between the two hemispheres, and release of primitive frontal reflexes such as grasping and compulsive manipulation of tools.^{1,2}

Alien limb following posterior stroke is rarer still²⁻⁸ and the underlying mechanisms are far less well understood (Table 1 summarizes these cases). Although patients with corticobasal degeneration (CBD) may have some similarities to such patients—both show neglect-like behavior and sensory loss in the alien limb⁹—the mechanisms and brain regions underlying alien limb behavior are difficult to study in cases with widespread neurodegeneration. Here, we describe two cases following posterior cerebral artery (PCA) stroke, discussing clinical and neuroanatomical features and possible underlying brain mechanisms.

CASE REPORT

Patient 1

A 75-year-old right-handed man suffered a right PCA stroke 4 days after coronary artery bypass graft surgery. Initially, he complained of left-sided somatosensory and visual loss. Shortly afterwards, he reported inability to control his left arm describing it as moving of its own accord. For example, if he was trying to undo a lid with his right arm, his left arm would interfere. The patient complained that his arm poked him at night. He described feeling annoyed when his arm moved and shouting at it. There was no loss of possession of the limb; he knew the arm belonged to him and had no difficulty distinguishing it from his right arm. It was possible for him to suppress the movement by laying his hand under his leg.

On examination 10 days post-stroke, there was a left homonymous hemianopia. Power, tone, and reflexes were normal, but joint position-sense was lost to shoulder level in the left arm. Pinprick and light touch sensation were intact. However, there was clear left-sided tactile extinction. He had severe left visuospatial neglect (7.5 cm rightward deviation on line bisection of 17 cm lines; and only 10 items cancelled on the right and none on the left on the BIT star cancellation task). No cerebellar or frontal release signs were present.

Several episodes of alien limb activity were witnessed (see video). His left arm moved involuntarily. For example, while sitting at a table, his left arm wandered around away from his body, under or above the table. He occasionally exhorted the arm to stop moving. On visual stimulation from the right, e.g., placement of a cup towards his right side, he developed abnormal grasping movements of the left hand and clung onto the object even though he said he had no intention to do so. The patient sometimes intervened with his right hand to release the object. He also demonstrated mirror movements of the left hand when asked to move his right hand. A CT scan performed on the day of presentation demonstrated an extensive right PCA infarct (Fig. 1a).

Five months later, the alien limb symptoms were markedly improved. The patient still complained of occasional interference from the left hand when performing activities such as putting on a tie. He experienced mild tremor of the left arm, but his main complaint was of severe pain affecting the left arm and leg. On examination, his proprioception had returned to normal. Leftward neglect had slightly improved (4.5 cm rightward line bisection and 1:20 left:right items cancelled on BIT star cancellation). The hemianopia was unchanged. No purposeful alien limb movements were now witnessed or elicited.

Patient 2

This 63-year-old, right-handed woman developed sudden-onset left hemisensory loss and difficulty mobilizing, due to uncertainty about the position of her left leg. She also complained that her left hand was moving without her prior intention. It often came over to touch the right hand or hold onto the side of her wheelchair when she was trying to move.

On examination, there was a dense left hemianopia, and left-sided proprioceptive loss throughout the arm and leg with subjective mild loss of light touch and pinprick sensation, as well as tactile extinction. She had marked left neglect revealed on cancellation tasks (0:8 left:right on BIT star cancellation) and a rightward line bisection (mean 1.2 cm right of center on 17 cm lines). No frontal release or cerebellar signs were present. Magnetic resonance imaging showed a large right PCA infarct (Fig. 1b).

After 6 weeks, the proprioceptive loss improved to only minimal impairment at the distal interphalangeal joint and alien limb symptoms were no longer present. The hemianopia remained and the neglect was still severe (0:12 left:right Bells cancellation test). She also

TABLE 1. Summary of clinical findings

Authors	Hemisphere of lesion	Vascular territory or anatomical localization	Presence of hemianopia/quadrantanopia	Presence of visual neglect	Visual extinction	Proprioceptive loss	Loss of light touch	Tactile extinction	Other information
Levine and Rinn, 1986 ⁸	Right	Right PCA: temporo-occipital and ventral posterolateral thalamic	Left H	+	NA	+++	+++	-	Proprioceptive loss improved after 2 months. Abnormal movements resolved but she retained the feeling of the limb being foreign.
Ay et al., 1998 ³	Right	Right PCA: thalamus, hippocampus, inferior-medial temporal lobes, splenium of corpus callosum and occipital lobe.	Left H	+++	NA	+++ ^a	+++ ^a	-	Dysmetria attributed to cerebellar ataxia and misreaching attributed to optic ataxia is described. PET scanning showed subtle reduced blood activity in most of the right hemisphere.
Marey-Lopez et al., 2002 ⁵	Right	Ventral posterolateral and dorsal thalamus	nil	+	-	+++	+++	-	Misreaching with the left arm also reported.
Ventura et al., 1995 ⁷	Right	Right thalamic and posterior capsule haemorrhage with mesencephalic extension	Left H	nil	NA	++	++	++	Left tactile extinction resolved in parallel with the alien limb. PET scanning suggested cortical reduced activity is sensorimotor areas. Named his arm "George" and was fond of it. Very little details regarding neurological deficits
Pack et al., 2002 ⁶	Right	Lateral thalamic infarct	nil	++	-	++	++	-	
Doody and Jankovic, 1992, ² Case 6	Right	Right-sided posterior temporo-occipital lobe, also involving posterior parietal lobe and posterior limb of internal capsule, right basal ganglia, left caudate, and left cerebellum.	-	-	-	-	-	-	
Groom et al., 1999 ⁴	Right	Right PCA: medial and posterior temporal lobe, posterior parietal and occipital lobes	Left H	+++	NA	+++	++		Patient liked the limb and referred to it as "my little buddy." Dysmetria, anosognosia and mirror movements also described.

+ mild; ++ moderate; +++ severe; - not mentioned in text.

^aSevere primary sensory loss described by authors, but different modalities not specifically mentioned.

HH, homonymous hemianopia.

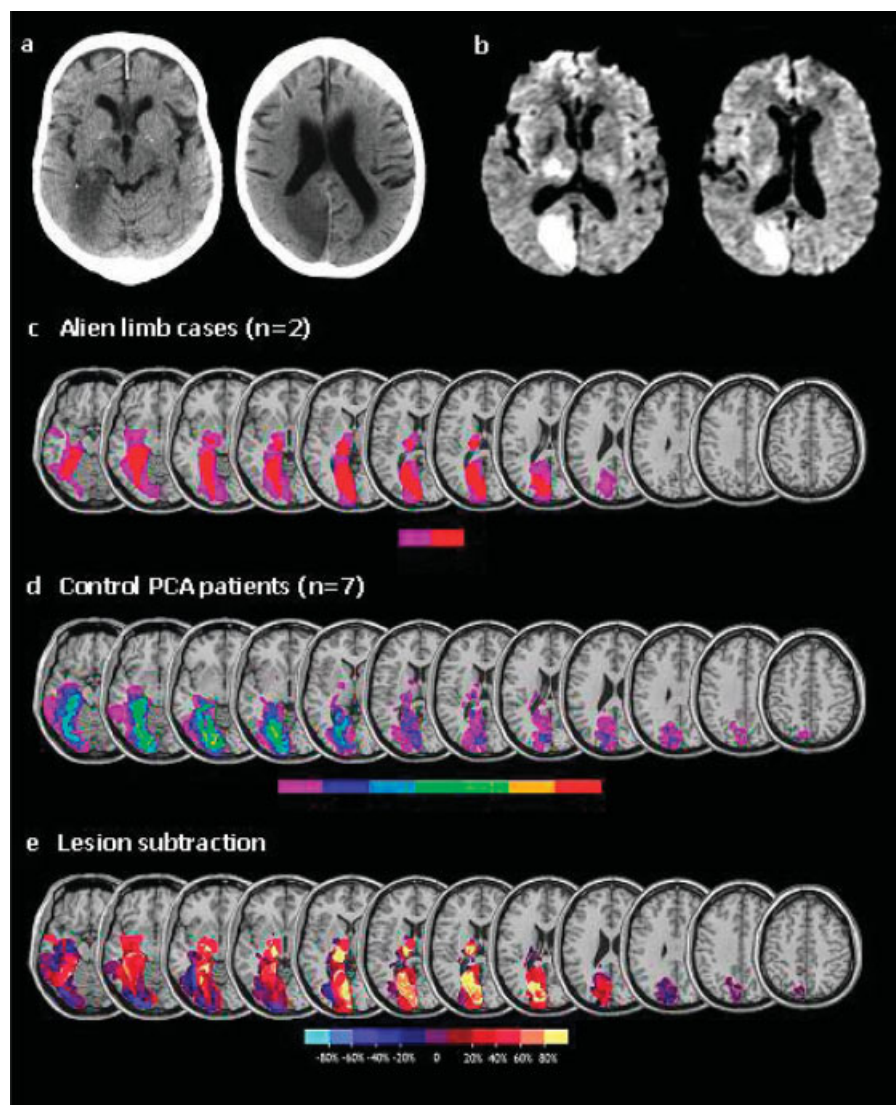


FIG. 1. Axial section from CT showing infarction of the right occipital, inferior parietal and medial temporal lobe as well as the thalamus in Patient 1 (a) and the diffusion weighted MR scan revealing a similar lesion in Patient 2 (b). Diffusion weighted images are shown as the scan was performed in the first few days after the stroke and T2 images reveal less of the infarct. Lesion overlay of the two patients with alien limb (c), control PCA patients (d), and after subtraction of the 7 control patients with PCA stroke and no alien limb phenomenon (e). Lesions are plotted from routine clinical imaging onto MRICro template and the subtraction is performed using MRICro software (www.mricro.com). In (e), the area in yellow is the area affected in *both* alien limb patients and no more than one of the 7 control patients. Yellow areas include the occipital and inferior parietal cortex as well as the thalamus and to a lesser extent medial temporal. The color bar in (e) shows percentage involvement in the subtraction. In (c) and (d), the color bars show how many patients are affected in each areas ranging from 1 (purple) to 2 (red) in (c) and 7 (red) in (d). Z coordinates for the slices are: -18, -16, -11, -6, -3, 3, 13, 16, 20, 24, and 30 (from left to right).

developed dystonia of the left arm and leg, which hindered her rehabilitation.

Control PCA Territory Patients

In order to establish which areas within the PCA territory may be critical for manifestation of the alien limb, we compared the lesions of our alien limb cases with those of a control group of seven patients with PCA stroke, but with no alien limb syndrome. All these control cases had a left visual field cut (hemianopia in 5 and left upper quadrantanopia in 2). Six of the seven had spatial neglect, but only two had hemisensory loss (to pinprick). In the four patients where joint position sense is documented, two had impaired proprioception. Only one of these individuals had neglect, hemianopia, and proprioceptive loss, but the severity of the

proprioceptive loss was not documented and this patient did not display any alien limb symptoms. The lesions of the seven control patients and those of the two alien limb patients were plotted onto anatomical templates using standard methods (Fig. 1c,d).¹⁰ Control patients' lesions were then subtracted from the alien limb lesions (Fig. 1e). Areas exclusively affected in the two patients with alien limb syndrome and none of the control patients (yellow on the overlay) are in the medial parieto-occipital regions—including the deep white matter, thalamus and to a lesser extent the medial temporal lobe.

DISCUSSION

The two patients described here both had left alien limb syndrome associated with severe left hemineglect,

left hemianopia and proprioceptive loss following right PCA stroke. A review of the literature reveals somatic sensory impairment and visual field defect or neglect in *all* previous cases with documented clinical findings (Table 1).^{2–8} In both our patients, proprioception returned to normal as manifestation of alien limb reduced. Two previous reports also note a similar improvement in somatosensory function with resolution of alien limb phenomena.⁹

These findings suggest that loss of both proprioceptive and visual feedback of the limb, which impairs sensory detection of limb movement, may be necessary for the manifestation of PCA alien limb syndrome. Medial occipital, deep parietal white matter and thalamic regions particularly affected in our alien limb cases (Fig. 1e) may contribute to these impairments. Proprioceptive loss and visual field deficits result from thalamic and occipital lobe damage respectively. The anatomical locus of visual neglect in PCA stroke is more controversial but may involve deep white matter parietal connections or the thalamus.^{10–12} Interestingly, these areas are also underactive in corticobasal degeneration.¹³

But even if visual or proprioceptive feedback of the moving limb is degraded, brain mechanism for initiating movement, in frontal motor and premotor regions, would still be expected to be intact in PCA cases. However, new findings show that parietal damage may also be associated with loss of sense of control of limb movement.¹⁴ The sense of intention is thought to arise from motor preparatory activity in both frontal and parietal regions. Patients with focal lateral parietal lobe damage have delayed awareness of the intention to perform voluntary movements even when frontal regions are intact.¹⁴ In addition, medial and superior parietal regions may play a critical role in directing reaching movements, perhaps by holding an internal model of the current state of the limb.¹⁵ Many of the cases of posterior alien limb syndrome previously described had lesions involving the parietal lobe or its connections (Table 1). In our cases only deep medial white matter connections were lost. It is possible that disconnection of, as well as direct damage to, parietal regions may impair the sense of intention, internal models of the current state of the limb, or both these factors.

These considerations raise the possibility that despite actions being willed, neither their intention nor their sensory consequences may be properly registered in PCA alien limb syndrome cases. The combination of loss of sense of motor intention and the internal model of the current state of the arm and lack of both proprioceptive and visual feedback of the moving limb would be cata-

strophic, leading to an impoverished representation of the contralesional limb. Such a combination of deficits might be critical for the loss of agency for their limb that our PCA patients report.

LEGENDS TO THE VIDEO

Segment 1. Interview with Patient 1. He describes when his alien limb becomes active and how he perceives this. He also displays some spontaneous alien limb activity.

Segment 2. Demonstration of alien limb phenomena provoked by placement of a cup near his hand. Critically, unlike the classical grasp reflex, this is as a result of visual not tactile stimulation.

Segment 3. Alien limb activity after placement of a wallet from his right visual field.

Acknowledgments: This work was supported by the Wellcome Trust.

REFERENCES

1. Fisher CM. Alien hand phenomena: a review with the addition of six personal cases. *Can J Neurol Sci* 2000;27:192–203.
2. Doody RS, Jankovic J. The alien hand and related signs. *J Neurol Neurosurg Psychiatry* 1992;55:806–810.
3. Ay H, Buonanno FS, Price BH, Le DA, Koroshetz WJ. Sensory alien hand syndrome: case report and review of the literature. *J Neurol Neurosurg Psychiatry* 1998;65:366–369.
4. Groom KN, Ng WK, Kevorkian CG, Levy JK. Ego-syntonic alien hand syndrome after right posterior cerebral artery stroke. *Arch Phys Med Rehabil* 1999;80:162–165.
5. Marey-Lopez J, Rubio-Nazabal E, Alonso-Magdalena L, Lopez-Facal S. Posterior alien hand syndrome after a right thalamic infarct. *J Neurol Neurosurg Psychiatry* 2002;73:447–449.
6. Pack BC, Stewart KJ, Diamond PT, Gale SD. Posterior-variant alien hand syndrome: clinical features and response to rehabilitation. *Disabil Rehabil* 2002;24:817–818.
7. Ventura MG, Goldman S, Hildebrand J. Alien hand syndrome without a corpus-callosum lesion. *J Neurol Neurosurg Psychiatry* 1995;58:735–737.
8. Levine DN, Rinn WE. Opticosensory ataxia and alien hand syndrome after posterior cerebral-artery territory infarction. *Neurology* 1986;36:1094–1097.
9. Mahapatra RK, Edwards MJ, Schott JM, Bhatia KP. Corticobasal degeneration. *Lancet Neurol* 2004;3:736–743.
10. Bird CM, Malhotra P, Parton A, Coulthard E, Rushworth MFS, Husain M. Visual neglect after right posterior cerebral artery infarction. *J Neurol Neurosurg Psychiatry* 2006;77:1008–1012.
11. Mort DJ, Malhotra P, Mannan SK, et al. The anatomy of visual neglect. *Brain* 2003;126 (Part 9):1986–1997.
12. Park KC, Lee BH, Kim EJ, et al. Deafferentation-disconnection neglect induced by posterior cerebral artery infarction. *Neurology* 2006;66:56–61.
13. Garraux G, Salmon E, Peigneux P, et al. Voxel-based distribution of metabolic impairment in corticobasal degeneration. *Mov Disord* 2000;15:894–904.
14. Sirigu A, Daprati E, Cianca S, Giraux P, Nighoghossian N, Posada A, Haggard P. Altered awareness of voluntary action after damage to the parietal cortex. *Nature Neurosci* 2004;7:80–84.
15. Wolpert DM, Goodbody SJ, Husain M. Maintaining internal representations: the role of the human superior parietal lobe. *Nat Neurosci* 1998;1:529–533.