

Images in Nephrology
(Section Editor: G. H. Neild)

Reversible posterior leukoencephalopathy syndrome (RPLS) in a patient with systemic lupus erythematosus (SLE) and lupus nephritis

Tausif Zar, Wilner Samson and Joseph Palmisano

Division of Nephrology, Department of Medicine, University of Connecticut

Keywords: Reversible posterior leukoencephalopathy syndrome; RPLS; Hypertensive encephalopathy; lupus nephritis-leukoencephalopathy syndrome

A 20-year-old Asian woman with a well-established history of systemic lupus erythematosus (SLE) and lupus nephritis (WHO stage IVB) presented to the emergency department with generalized arthralgia and headaches. Her current medications included cellcept 1000 mg daily and prednisone 30 mg daily. The patient had had low normal blood pressure in the past, and experienced episodes of hypotension with lisinopril. Initial laboratory workup revealed serum creatinine of 4.5 mg/dl (baseline 0.5 mg/dl), C3 57 g/l, C4 <10 g/l, anti-dsDNA >200 IU/ml, CRP 356 mg/dl, ESR 122 mm/h and a spot urine protein to creatinine ratio of 3309 mg/g. Urine microscopy showed persistent nephritic sediments. Physical examination was significant for a malar rash. Initial blood pressure (BP) was 96/66 mmHg. The patient was diagnosed with lupus flair-up and received methylprednisone 125 mg IV, in the emergency room. Within the next hour, her BP increased to 140/110 mmHg. After admission, the patient was continued on IV hydrocortisone, 100 mg every 6 h. Renal function improved and returned to baseline over the next 3 days. Simultaneously, the patient gained 10 lbs weight and developed significant dependent oedema. Her BP progressively increased, despite multiple antihypertensive medications. On day 3, the cellcept was discontinued due to gram negative bacteremia, and IV antibiotics were started. On day 4, BP rose to 190/110 mmHg. The patient experienced a transient seizure and cortical blindness. She was transferred to ICU, and started on aggressive BP management with IV antihypertensives. MRI of the brain

Correspondence and offprint requests to: Dr Tausif Zar, 263 Farmington Avenue, Farmington, Connecticut 06032, USA.
Email: zarjr73@yahoo.com

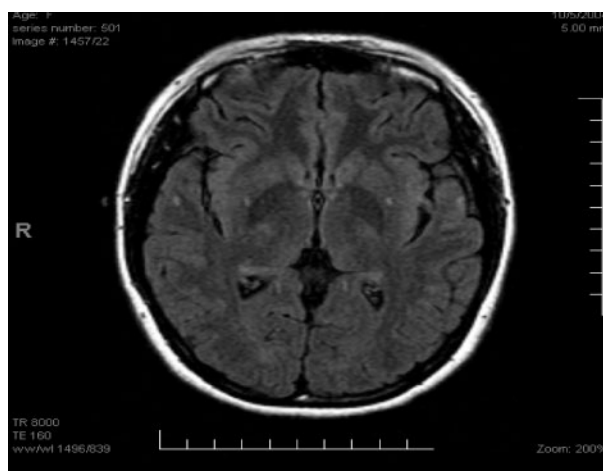


Fig. 1. Fluid-attenuated inversion recovery (FLAIR) MRI image of the patient on 5 October 2004, showing no abnormality.

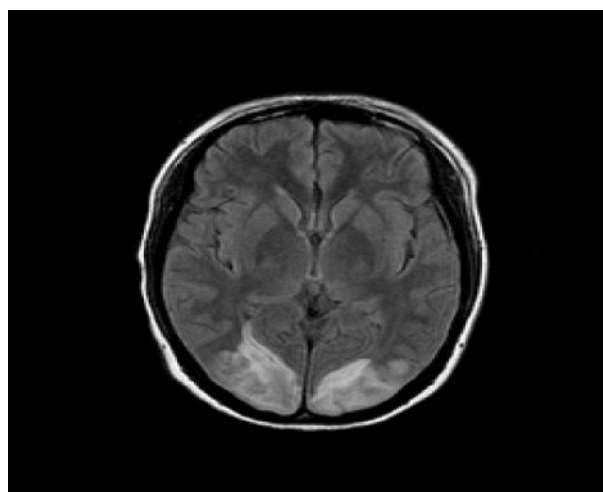


Fig. 2. FLAIR MRI image of the patient on 23 October 2005, showing bilateral occipital lesions.

showed new bilateral gray and white matter oedematous lesions, consistent with RPLS (Figures 1, 2). MRV and MRA were normal. To rule out an infectious aetiology, lumbar puncture was performed. CSF analysis and cultures were negative. As reported in the literature, RPLS was attributed to hypertensive encephalopathy and a background of SLE, immunosuppression and high dose steroids [1–3]. Steroid dosage was tapered to 20 mg of prednisone daily. BP improved and her symptoms completely resolved within the next 48 h. Follow-up MRI 1 week later showed improved bilateral occipital lesions, which were almost completely resolved 2 months later (Figure 3).

Conflict of interest statement. None declared.

References

1. Magnano MD, Bush TM, Herrera I, Altman RD. Reversible posterior leukoencephalopathy in patients with systemic lupus erythematosus. *Semin Arthritis Rheum* 2002; 35: 396–402
2. Primavera A, Audenino D, Mavilio N, Cocito L. Reversible posterior leukoencephalopathy syndrome in systemic lupus and vasculitis. *Ann Rheum Dis* 2001; 60: 534–537
3. Hinchey J, Chaves C, Appignani B *et al.* A reversible posterior leukoencephalopathy syndrome. *N Engl J Med* 1996; 334: 494–500

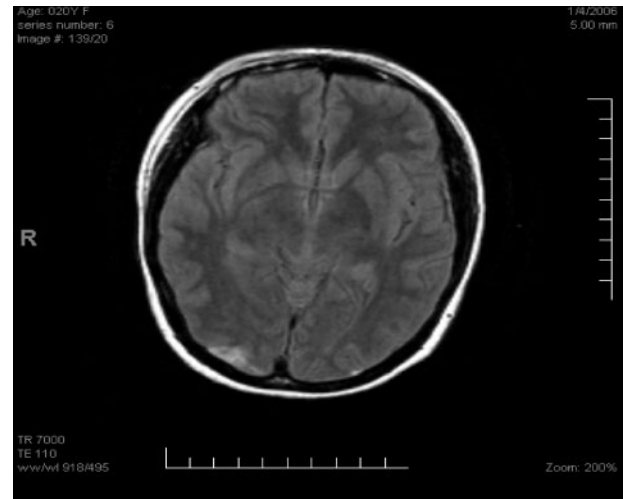


Fig. 3. FLAIR MRI of the patient obtained on 4 January 2006, showing almost complete resolution of the bilateral occipital lesions.

Received for publication: 15.3.07
Accepted in revised form: 13.4.07